



CODEN [USA]: IAJPBB

ISSN: 2349-7750

INDO AMERICAN JOURNAL OF
PHARMACEUTICAL SCIENCES<http://doi.org/10.5281/zenodo.1067105>Available online at: <http://www.iajps.com>

Research Article

COMPARISON OF INTRAVITREAL BEVACIZUMAB (AVASTIN) WITH TRIAMCINOLONE FOR TREATMENT OF DIFFUSED DIABETIC MACULAR EDEMA: A PROSPECTIVE RANDOMIZED STUDYAli Kasiri ¹, Fereydoun Farrahi ¹, Mostafa Fegghi ¹, Behnam Sadeghi ¹, Hesam Hedayati ¹, Seyed Ahmad Rasoulinejad ²¹ Department of Ophthalmology, Ahvaz Jundishapur University of Medical Sciences, Ahvaz, Iran² Department of Ophthalmology, Babol University of Medical Sciences, Babol, Iran**Abstract:**

Objectives: Despite the high prevalence of diabetic macular edema (DME), there is no definite treatment because of its complicated pathophysiologic mechanism, which is still not fully understood. This study was performed to compare the efficacy of intravitreal bevacizumab (IVB) with intravitreal triamcinolone acetate (IVT) in patients exhibiting diffused DME.

Methods: In this randomized clinical trial, eligible eyes were assigned randomly to one of the three study arms: the IVB group, patients who received 1.25 mg IVB (30 eyes); the IVT group, patients who received 2 mg of IVT (30 eyes); and the MPC group, patients who underwent modified grid laser (30 eyes). The eyes of the IVB and IVT patients underwent macular grid photocoagulation 3 weeks afterward. Main outcome measures included change in central macular thickness (CMT) and change in best-corrected visual acuity (BCVA) 6 and 12 weeks after injection.

Results: There was no difference between the IVB and IVT groups in terms of BCVA improvement at both 6 weeks ($p=0.532$) and 12 weeks ($p=0.751$). In both IVB and IVT groups, BCVA improved significantly from baseline to 6 and 12 weeks compared with MPC group. CMT decreased more in the IVB group than it did in the IVT group during the follow-up period ($p=0.036$). CMT decreased significantly in both IVB and IVT groups compared with MPC group.

Conclusion: The results of our study revealed that both IVB and IVT may be effective in the treatment of diffused DME compared with macular grid augmentation. However, IVB may offer certain advantages over triamcinolone in the short-term management of diffused DME.

Key words: Diabetic macular edema, Intravitreal bevacizumab, Intravitreal triamcinolone, Laser photocoagulation, Best corrected visual acuity, Central macular thickness.

Corresponding author:**Ali Kasiri,**Department of Ophthalmology,
Ahvaz Jundishapur University of Medical Sciences,
Ahvaz, Iran.Email: Alikasiri343@gmail.com

QR code



Please cite this article in press as Ali Kasiri et al., *Comparison of Intravitreal Bevacizumab (Avastin) With Triamcinolone for Treatment of Diffused Diabetic Macular Edema: A Prospective Randomized Study*, *Indo Am. J. P. Sci.*, 2017; 4[11].

INTRODUCTION:

Diabetic macular edema (DME), is one of the most common causes of visual impairment in the diabetic patients [1]. The worldwide prevalence of diabetes is estimated to rise to 366 million by 2030 [2]. The 10-year incidence of macular edema in patients with type 2 diabetes was up to 14%, and 29% of type 1 progressed into DME over a 25-year period [3,4]. Hence, finding a safe and effective treatment of DME becomes urgent. Despite the high prevalence of DME, there is no definite treatment because of its complicated pathophysiologic mechanism, which is still not fully understood. However, there is no single modality that has been shown to be superior.

The Early Treatment Diabetic Retinopathy Study (EDTRS) showed that macular laser photocoagulation (MPC) is effective in reducing the risk of visual loss by approximately 50% in eyes with clinically significant macular edema [5]. However, unsatisfactory outcomes are frequent, and 12% treated eyes developed moderate visual loss. Moreover, about 15% patients fall into the category of refractory DME and do not respond to repeated laser treatments. This shows that in spite of laser being the gold standard treatment of DME, some patients do not respond to laser [6]. Various modalities of treatment are currently being tried in the management of persistent; laser refractory DME such as supplemental laser, intravitreal steroid injection, and anti-vascular endothelial growth factor (anti-VEGF) injection [7].

Ranibizumab and bevacizumab are two main anti-VEGF agents for DME. Although ranibizumab has been recently approved by the United States Food and Drug Administration for the treatment of DME, its cost is immense. Bevacizumab, which costs much less than ranibizumab, is a full-length recombinant humanized monoclonal antibody directed against VEGF and has been used off label in the treatment of ocular diseases including DME. Some studies have indicated that intravitreal bevacizumab (IVB) was effective for reducing macular edema [8,9].

Triamcinolone acetonide, one of corticosteroids, has the effect of anti-inflammatory and anti-angiogenesis. Multiple reports have demonstrated the similar performance of IVB versus intravitreal triamcinolone acetonide (IVT) in patients with DME [10,11].

With the increasing use of IVB and IVT, it is of interest to uncover whether the compounded intravitreal agents are more effective and safe. This study was performed to compare the efficacy of intravitreal bevacizumab (IVB) with intravitreal

triamcinolone acetonide (IVT) in patients exhibiting DME.

MATERIALS AND METHODS:

Study design: Prospective, 3-armed, randomized clinical trial.

Ethical considerations:

The study protocol adhered to the tenets of the Declaration of Helsinki and was approved by the institutional review board (IRB) of the Ahvaz Jundishapur University of Medical Sciences Ethics Committee. In addition, all participants signed an informed consent form after a detailed explanation of the study design, associated investigations for scientific purposes, and adjuvant imaging procedures.

Sample size:

To have a power of 90%, a significance level equal to 0.05, and an assumed standard deviation of 50 μm in central macular thickness (CMT), a sample size of 30 eyes for each arm was calculated.

Participant:

Inclusion criteria for this study were the presence of clinically evident diffuse DME confirmed by fluorescence angiography (FFA) in patients who had never previously underwent treatment with laser photocoagulation, intravitreal injections, or surgery. Clinically evident DME was defined as central macular thickness more than 250 μm , as measured by spectral domain optical coherence tomography (SD-OCT) (Opko/OTI; Ophthalmic Technologies, Toronto, ON, Canada) with a sponge like appearance of the macula considered as diffuse DME and without any evidence of vitreo-retinal traction; retinal thickening within one disc area at the fovea-center on clinical biomicroscopic examination; and presence of hard exudates in the perifoveal area, with or without subfoveal involvement.

If both eyes in the same patient showed DME, only one eye was randomly selected for analysis.

Patients with a history of previous treatments of retinal photocoagulation or prior anti-VEGF therapy, previous intraocular or peribulbar steroid injection (within the previous six months), proliferative diabetic retinopathy identified by fluorescence angiography or with significant optical media problems that could distort OCT images, history of ocular diseases other than diabetic retinopathy, glaucoma or ocular hypertension, ischemic maculopathy, massive subfoveal hard exudates or subretinal fibrosis, significant media opacity precluding retinal view, vitreous surgery within the previous six months, or significant cataract, patients having uncontrolled diabetes mellitus, uncontrolled hypertension,

patients with thromboembolic event within six months, presence of traction on the macula evidenced by optical coherence tomography (OCT), monocularly, and pregnancy were excluded from the study.

Patients fulfilling all inclusion and exclusion criteria were evaluated with a detailed history, complete systemic examination, and a thorough ocular examination including the best corrected visual acuity (BCVA) assessment using Snellen visual acuity chart, anterior segment evaluation, slit lamp biomicroscopy, intra ocular pressure (IOP) measurement using Goldmann applanation tonometer, funduscopy, and central macular thickness (CMT) measurement using optical coherence tomography (Stratus OCT, Carl Zeiss Meditec Inc, Dublin, CA). All patients were also evaluated for their metabolic control including fasting and postprandial blood sugars, serum lipid levels, renal function tests, and glycosylated hemoglobin levels

- Randomization:

Randomization was performed using the randomly permuted blocks according to a computer generated randomization list. The block lengths varied randomly (3, 6). A random allocation sequence was performed by a biostatistician. Details of the series were unknown to the investigators.

- Intervention:

Injections were performed under complete sterile conditions using bovidine iodine 10% for eyelid skin and 5% for ocular surface wash, followed by applying at least 3 drops of eye drops to topical anesthesia and insertion of a lid speculum.

Intravitreal injection was performed as follows:

- For the IVB group, 1.25/0.05 (mg/ml) intravitreal anti-VEGF agent bevacizumab (Avastin, Genentech Inc., San Francisco, CA, USA (made for F. Hoffmann- La Roche Ltd. Basel, Switzerland)) was injected in the inferotemporal quadrant with a 27-gauge needle through the pars plana (3.5 mm from limbus) into the vitreous.
- For the IVT group, 0.05 mL (2 mg) triamcinolone acetonide (Triamhexal, Hexal AG, Holzkirchen, Germany) was injected with another 27-gauge needle in the inferotemporal quadrant.
- In the MPC group, patients underwent modified macular grid laser photocoagulation augmentation. Macular grid laser augmentation was performed by a single experienced examiner according to the modified ETDRS protocol with a spot size of

100 μ , pulse duration of 100 ms, and a power of 50–100 mW titrated to produce mild intensity burns in areas showing diffuse leakage on the FFA in a 'C' shaped zone between 500 and 3000 μ from the foveal center sparing the papilla-macular bundle [12].

After the injection, all patients were prescribed a topical antimicrobial drug, moxifloxacin 0.5% four times a day for a week. The modified macular grid laser coagulation 3 weeks after injection was applied only in the IVB and IVT group eyes.

- Masking:

In MPC group, a sham injection by a needleless syringe pressed against the conjunctiva was done. For complete masking, subjects were prevented from seeing the syringe. All procedures were run by staff members other than the study investigators to maintain investigator masking. Additionally, the outcome assessors (optometrists responsible for visual acuity and OCT testing) and data analysts were masked to the allocation.

- Follow up:

Patients in all the three groups were examined on the first postprocedure day to look for any complications following the procedure. Examination of best corrected visual acuity, IOP, detection of anterior chamber reaction, lens opacity, and funduscopy were performed at day 1, and weeks 1, 6, and 12 after injection.

Follow up visits were conducted by a single masked investigator at 6 weeks and 12 weeks in each group. BCVA was measured using the Snellen chart and converted to logarithm of the minimum angle of resolution (logMAR) notations. Lens opacity was graded according to the Lens Opacities Classification System III (LOCS III) (13). Detection of macular thickness in 1 mm circle centered on the fovea was done at the week 6 and week 12 follow-up.

- Statistical analysis:

The data were analyzed using SPSS ver. 12.0 (SPSS Inc., Chicago, IL, USA). Quantitative data were expressed as Mean \pm Standard Deviation and qualitative data were expressed as percentages. paired *t*-test was used to detect the statistical difference between the pre- and the post-injection data; one-way ANOVA (analysis of variance) test was used to detect the statistical difference in the outcome measures at weeks 6 and 12; and the least significant difference post hoc test was used to detect the statistical difference between the results of each pair of the study groups at the week 6 and week 12 follow-up. $P < 0.05$ was considered statistically significant.

RESULTS:

A total of 90 eyes of 90 patients were enrolled in the study. For all the study patients, the mean age was 60.08 ± 7.46 years, with a minimum of 45 and maximum of 75 years; males were 43 (47.78%), and females were 47 (52.22%). Patients were consecutively randomized to one of the three treatment groups with 30 patients in each group. Baseline demographic and clinical characteristics for participants in the study groups are shown in table 1. There were no significant differences amongst the groups for baseline characteristics.

As shown in table 2, in IVB group with regards to the BCVA, there was significant difference between the baseline and follow up results at week 6 ($p=0.001$); however, this difference was not significant at week 12 ($p=0.721$). BCVA at 6 weeks of follow up in the IVT group showed significant improvement compared with the BVCA at baseline ($p=0.001$) but at 12 weeks there were no significant change compared with baseline measurement. However, in the MPC group BVCA deteriorated at 12 weeks (Figure 1).

There was no difference between the IVB and IVT groups in terms of BCVA improvement a both 6 weeks ($p=0.532$) and 12 weeks ($p=0.751$). In both IVB and IVT groups, BCVA improved significantly from baseline to 6 and 12 weeks

compared with MPC group (Table 3). As shown in Table 2, Both groups IVB and IVT showed a statistically significant decrease in the mean CMT at 6 weeks compared with the baseline ($p=0.004$ and $p<0.0001$, respectively). At 12 weeks there were no significant change compared with 6 weeks measurements. However, CMT had not significant changes at 6 and 12 weeks in MPC group (Figure 2).

CMT decreased more in the IVB group than it did in the IVT group during the follow-up period ($p=0.036$). CMT decreased significantly in both IVB and IVT groups compare with MPC group (Table 3).

There was no significant IOP increase or patient requiring IOP reduction treatment in IVB group. However, three eyes in MPC group and four eyes in IVT group showed increase in IOP from baseline needing treatment with an average rise in IOP of 23mm of Hg. All the patients were managed successfully medically with none of the eyes needing a surgical intervention for the control of IOP. No adverse events like endophthalmitis, vitreous hemorrhage or retinal detachment were observed in any group. No systemic side effects with IVB were observed in group 1 eyes. No clinically significant cataract progression was noted during the study period.

Table 1: Distribution of baseline characteristic in three treatment groups

Characteristic	Treatment Group			P value
	IVB	IVT	MPC	
No. of eyes	30	30	30	
Age (Years)	59.93 ± 5.32	59.11 ± 9.51	61.21 ± 4.76	0.312*
Gender (M:F)	12 / 18	14 / 16	17 / 13	0.091†
BCVA (logMAR)	0.63 ± 0.27	0.59 ± 0.31	0.71 ± 0.22	0.114*
CMT (μm)	417 ± 141	451 ± 139	439 ± 130	0.516*
IOP (mmHg)	14.9 ± 2.9	14.4 ± 2.3	14.5 ± 3.1	0.455*

IVT, intravitreal triamcinolone; IVB, intravitreal bevacizumab; MPC, macular laser photocoagulation; BCVA, best-corrected visual acuity; logMAR, logarithm of the minimum angle of resolution; CMT, central macular thickness; IOP, intraocular pressure.

*Tested using the chi-square test; †Tested using the Mann-Whitney test

Table 2: Mean corrected visual acuity and central macular thickness for each treatment group before, 6 weeks and 12 weeks after intervention

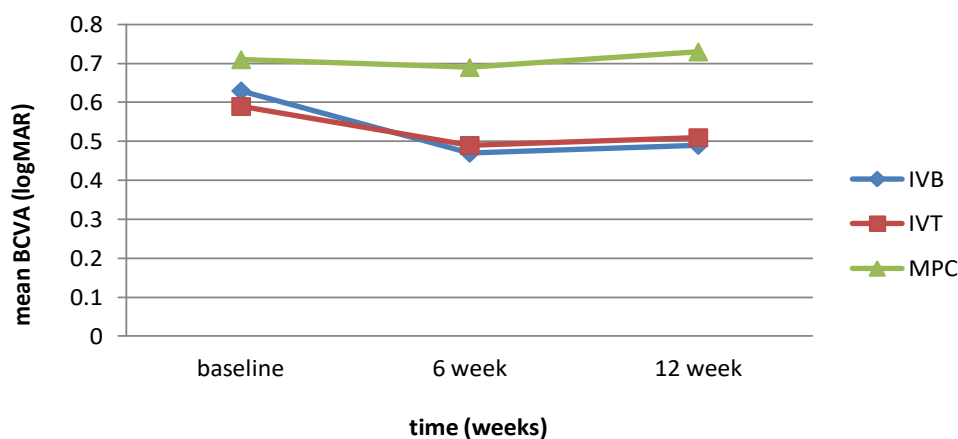
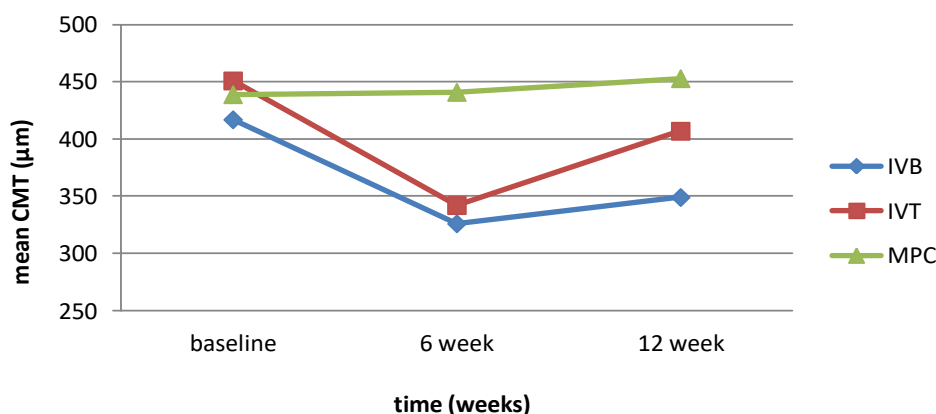
	CMT (μm)			BCVA (logMAR)		
	IVB	IVT	MPC	IVB	IVT	MPC
Baseline	417 ± 121	451 ± 139	439 ± 136	0.63 ± 0.24	0.59 ± 0.33	0.71 ± 0.34
6 weeks	326 ± 142	342 ± 124	441 ± 94	0.47 ± 0.14	0.49 ± 0.24	0.69 ± 0.22
12 weeks	349 ± 97	407 ± 141	453 ± 92	0.49 ± 0.26	0.51 ± 0.39	0.73 ± 0.27

IVT, intravitreal triamcinolone; IVB, intravitreal bevacizumab; MPC, macular laser photocoagulation; BCVA, best-corrected visual acuity; logMAR, logarithm of the minimum angle of resolution; CMT, central macular thickness.

Table 3: Multiple comparisons between the post-injection data in the three study groups using the least significance difference test

	Compared groups		P value
BCVA 6 weeks post-injection	IVB	IVT	0.532
	IVB	MPC	0.001
	IVT	MPC	0.001
CMT 6 weeks post-injection	IVB	IVT	0.062
	IVB	MPC	<0.0001
	IVT	MPC	<0.0001
BCVA 12 weeks post-injection	IVB	IVT	0.751
	IVB	MPC	<0.0001
	IVT	MPC	<0.0001
CMT 12 weeks post-injection	IVB	IVT	0.036
	IVB	MPC	<0.0001
	IVT	MPC	0.041

BCVA, best-corrected visual acuity; CMT, central macular thickness.

**Fig 1: Change of the mean best-corrected visual acuity in three treatment groups. IVT, intravitreal triamcinolone; IVB, intravitreal bevacizumab; MPC, macular laser photocoagulation****Fig 2: Change of the mean central macular thickness in three treatment groups. IVT, intravitreal triamcinolone; IVB, intravitreal bevacizumab; MPC, macular laser photocoagulation**

DISCUSSION:

In our study, we compare and evaluate IVB, IVTA, and standard laser treatment in diffused DME. The results of our study, however, revealed definite a benefit with both IVB and IVTA over grid laser augmentation for treatment of diffused DME compared with grid laser augmentation in terms of both visual gain and reduction in CMT. Both IVB and IVTA may be effective in the treatment of diffused DME compared with macular grid augmentation. However, intravitreal injection of bevacizumab may offer certain advantages over triamcinolone in the short-term management of diffused DME, specifically with regard to changes in central macular thickness.

In the studies by Chakrabarti et al [14] and Marey and Ellakwa [15], the response to therapy with bevacizumab showed superiority compared with triamcinolone for DME. However, these studies differed from that of Shimura et al [16] and Paccola et al [17]. Shimura et al. compared the effect of an IVB with that of IVT in persistent DME and results show that with generally used concentration, IVT showed better results in reducing DME and in improvement of visual acuity than that of IVB [16]. Paccola et al. compared the morphological and visual outcomes associated with single IVT versus IVB for the treatment of refractory diffuse DME and results showed that one single IVT may offer certain advantages over IVB specifically with regard to changes in CMT [17].

And in the other study by Rensch et al [18], IVT and IVB did not differ markedly in term of their effects in improving BCVA and reducing macular thickness. Which treatment are more effective remains controversial.

Diabetic macular edema is characterized by intraretinal and subretinal accumulations of fluid, resulting principally from retinal vascular leakage [7]. As evidenced by fluorescein angiography of diffuse DME, microvascular obstruction and resultant ischemia induce derangements in the integrity of the inner blood-retinal barrier. In contrast, outer blood-retinal barrier damage at the level of the retinal pigment epithelium has also been suggested as a mechanism to explain the development of diffuse edema [19]. Laser photocoagulation has been the mainstay of treatment for DME. Grid laser treatment for DME is believed to reduce permeability of leaky blood retinal barrier but several reports indicate that photocoagulation itself may induce blood retinal barrier breakdown and increased retinal thickness soon after grid laser treatment [19,20]. It has also been stated in previous studies that laser coagulation of macular region often does not lead to increase in vision and that macular edema

especially in diffuse type may persists despite laser treatment [12].

In diffuse DME, however, profound foveal thickening, retinal opacification, and fluid accumulation, predominantly in the retinal outer layers, interfere with the transmission of laser energy into the retinal pigment epithelium. Furthermore, the laser effects on the retinal vascular endothelium and photoreceptors are hard to expect under such circumstance. In addition, diffuse DME originates from a more generalized breakdown of the blood-retinal barrier, representing an advanced stage of diabetic retinopathy. For these reasons, diffuse DME is associated with poor prognoses despite grid laser photocoagulation [21]. Other reported adverse effects of laser photocoagulation are foveal burns, visual field defects, retinal fibrosis and subretinal laser scars scotomas, field constriction decrease in dark adaptation and development of choroidal neovascularization [22,23].

The existence of substantial group of patients with DME whose vision has failed to improve following laser photocoagulation has prompted clinicians to seek more effective treatment modalities. Steroids and anti-VEGF drugs are newer treatments in DME.

Intravitreal triamcinolone acetonide has been seen to be effective treatment adjuvant in number of studies. It has been seen to both improve vision and reduce CMT in eyes with refractory DME. Previous reports have demonstrated improvements in the visual acuity and the alleviation of diffuse macular edema after IVT [24,25]. Tunc et al. [26] reported that eyes with diffuse DME undergoing laser treatment had better VA outcomes after 18 weeks of treatment was preceded by a posterior sub-Tenon's capsule injection of triamcinolone. Kang et al. [27] randomized 86 eyes with diffuse DME to receive either IVT or IVT followed by grid laser and found laser treatment acted synergistically with IVT resulting in an increased duration of effect attributable to IVT. Avitabile et al. [28] found that VA and macular thickness outcomes had no apparent difference between the laser plus triamcinolone and the triamcinolone alone groups. Lam et al. [29] randomized patients with DME to grid laser photocoagulation, IVT, or IVT combined with grid laser. They showed that IVT combined with laser produced a greater reduction in central macular thickness compared to laser alone.

The exact mechanism of the maintenance of improved vision and decreased central macular thickness due to grid laser treatment after IVT is unknown but we speculate that several factors are involved. First, decreased foveal thickness after

IVT may enhance the effects of grid laser photocoagulation. Without IVT, markedly increased foveal thickness, subfoveal fluid, and retinal opacity due to diffuse DME might interfere with adequate laser burning of the retinal pigment epithelium and photoreceptor layers. However, after IVT, the decreased foveal thickness and restoration of retinal transparency achieved by the treatment would facilitate the delivery of the laser energy selectively to the photoreceptors and retinal pigment epithelia. Second, the possibility exists that steroids might act beneficially in the process of mature laser scar formation. It has been established that 2 or 3 weeks should elapse for the formation of a mature laser scar, and laser treatment itself frequently induces the aggravation of macular edema or inflammation during this period. The presence of intravitreal steroids might exert certain protective effects against the initial deleterious events that follow grid laser treatment and might also modulate retinal pigment epithelial remodeling after grid laser treatment [7].

Although IVT has been reserved for DME refractory to laser photocoagulation, IVT as a primary treatment for diffuse DME has recently been advocated because of its favorable results [14]. The major limitation of using IVT as adjunctive therapy for DME is the short duration of action and the need for multiple injections. The therapeutic effect of the steroid is typically seen within one week, but in many patients, reinjections are needed every 3-6 months as the effect diminishes [7]. Repeated intravitreal injections, however, do carry their own inconvenience and risks including endophthalmitis and retinal detachment. IOP and cataract progression were reported as relatively common ocular side effects among others [25].

The advent of anti-VEGF agents marks a major advancement in treatment of various ocular diseases. Bevacizumab is a pan-VEGF-blocking agent and may impair normal physiologic VEGF-mediated functions, which might be considered as a disadvantage of this agent. Decrease in retinal thickness and improvement in visual acuity has also been noted in patients with diffuse chronic macular edema [30]. There are few reports illustrating that visual loss can be due to disruption of the capillary network and induction of macular ischemia following intravitreal injection of bevacizumab [31].

A randomized clinical trial by Soheilian *et al* revealed that a single injection of IVB, as a primary treatment for DME, more effectively improves vision in the short term when compared to laser therapy [32]. The BOLT study randomized patients to laser therapy or intravitreal bevacizumab [33].

At 24 months, the mean changes in BCVA were statistically significantly higher in the bevacizumab arm than in the laser arm. Lim *et al* [34] evaluated the combination of bevacizumab plus triamcinolone when compared with bevacizumab alone or triamcinolone alone and found no statistically significant difference between groups for BCVA or CMT.

There was a low frequency of adverse events reported in the included trials. A higher incidence of mild anterior chamber reaction was reported in bevacizumab groups compared with controls. The incidence of IOP increase was comparable between bevacizumab and laser. Soheilian *et al* [32] were the only authors to report the incidence of lens opacity.

We performed grid photocoagulation 3 weeks after IVT and IVB because we thought that the decreased foveal thickness and restoration of retinal transparency achieved by injection might facilitate adequate laser burning of the retinal pigment epithelia and photoreceptors.

Further trials with a longer follow-up period, randomized to laser photocoagulation alone, IVTA alone, and combination therapy, may provide more solid grounds for this new strategy for diffuse DME.

REFERENCES:

1. Romero-Aroca P. Current status in diabetic macular edema treatments. *World J Diabetes*. 2013;4(5):165-9.
2. Habib SL, Rojna M. Diabetes and risk of cancer. *ISRN Oncol*. 2013;2013:583786.
3. Klein R, Klein BE, Moss SE, Cruickshanks KJ. The Wisconsin Epidemiologic Study of Diabetic Retinopathy. XV. The long-term incidence of macular edema. *Ophthalmology*. 1995;102(1):7-16.
4. Klein R, Knudtson MD, Lee KE, Gangnon R, Klein BE. The Wisconsin Epidemiologic Study of Diabetic Retinopathy: XXII the twenty-five-year progression of retinopathy in persons with type 1 diabetes. *Ophthalmology*. 2008;115(11):1859-68.
5. Photocoagulation for diabetic macular edema. Early Treatment Diabetic Retinopathy Study report number 1. Early Treatment Diabetic Retinopathy Study research group. *Archives of ophthalmology*. 1985;103(12):1796-806.
6. Early photocoagulation for diabetic retinopathy. ETDRS report number 9. Early Treatment Diabetic Retinopathy Study Research Group. *Ophthalmology*. 1991;98(5 Suppl):766-85.
7. Bhagat N, Grigorian RA, Tutela A, Zarbin MA. Diabetic macular edema: pathogenesis and treatment. *Surv Ophthalmol*. 2009;54(1):1-32.
8. Fortin P, Mintzes B, Innes M. A systematic review of intravitreal bevacizumab for the

- treatment of diabetic macular edema. *CADTH Technol Overv.* 2013;3(1):e3203.
- 9.Lee SJ, Kim ET, Moon YS. Intravitreal bevacizumab alone versus combined with macular photocoagulation in diabetic macular edema. *Korean J Ophthalmol.* 2011;25(5):299-304.
- 10.Sobaci G, Ozge G, Erdurman C, Durukan HA, Bayraktar ZM. Comparison of grid laser, intravitreal triamcinolone, and intravitreal bevacizumab in the treatment of diffuse diabetic macular edema. *Ophthalmologica Journal international d'ophtalmologie International journal of ophthalmology Zeitschrift fur Augenheilkunde.* 2012;227(2):95-9.
- 11.Azad R, Sain S, Sharma YR, Mahajan D. Comparison of intravitreal bevacizumab, intravitreal triamcinolone acetonide, and macular grid augmentation in refractory diffuse diabetic macular edema: A prospective, randomized study. *Oman J Ophthalmol.* 2012;5(3):166-70.
- 12.Akduman L, Olk RJ. Laser photocoagulation of diabetic macular edema. *Ophthalmic Surg Lasers.* 1997;28(5):387-408.
- 13.Chylack LT, Jr., Wolfe JK, Singer DM, Leske MC, Bullimore MA, Bailey IL, et al. The Lens Opacities Classification System III. The Longitudinal Study of Cataract Study Group. *Arch Ophthalmol.* 1993;111(6):831-6.
- 14.Chakrabarti M, John S, Chakrabarti A. Intravitreal monotherapy with bevacizumab (IVB) and triamcinolone acetonide (IVTA) versus combination therapy (IVB and IVTA) for recalcitrant diabetic macular edema. *Kerala J Ophthalmol.* 2009;21(2):139-48.
- 15.Marey HM, Ellakwa AF. Intravitreal bevacizumab alone or combined with triamcinolone acetonide as the primary treatment for diabetic macular edema. *Clin Ophthalmol.* 2011;5:1011-6.
- 16.Shimura M, Nakazawa T, Yasuda K, Shiono T, Iida T, Sakamoto T, et al. Comparative therapy evaluation of intravitreal bevacizumab and triamcinolone acetonide on persistent diffuse diabetic macular edema. *Am J Ophthalmol.* 2008;145(5):854-61.
- 17.Paccola L, Costa RA, Folgosa MS, Barbosa JC, Scott IU, Jorge R. Intravitreal triamcinolone versus bevacizumab for treatment of refractory diabetic macular oedema (IBEME study). *Br J Ophthalmol.* 2008;92(1):76-80.
- 18.Rensch F, Spandau UH, Wickenhauser A, Jonas JB. Diffuse diabetic macular oedema treated with intravitreal bevacizumab or triamcinolone acetonide. *Acta Ophthalmol.* 2010;88(2):e36-7.
- 19.Kumar B, Gupta SK, Saxena R, Srivastava S. Current trends in the pharmacotherapy of diabetic retinopathy. *J Postgrad Med.* 2012;58(2):132-9.
- 20.Nicholson BP, Schachat AP. A review of clinical trials of anti-VEGF agents for diabetic retinopathy. *Graefes Arch Clin Exp Ophthalmol.* 2010;248(7):915-30.
- 21.Ford JA, Lois N, Royle P, Clar C, Shyangdan D, Waugh N. Current treatments in diabetic macular oedema: systematic review and meta-analysis. *BMJ Open.* 2013;3(3).
- 22.Sander B, Larsen M, Moldow B, Lund-Andersen H. Diabetic macular edema: passive and active transport of fluorescein through the blood-retina barrier. *Invest Ophthalmol Vis Sci.* 2001;42(2):433-8.
- 23.Chew EY, Ferris FL, 3rd, Csaky KG, Murphy RP, Agron E, Thompson DJ, et al. The long-term effects of laser photocoagulation treatment in patients with diabetic retinopathy: the early treatment diabetic retinopathy follow-up study. *Ophthalmology.* 2003;110(9):1683-9.
- 24.Massin P, Audren F, Haouchine B, Erginay A, Bergmann JF, Benosman R, et al. Intravitreal triamcinolone acetonide for diabetic diffuse macular edema: preliminary results of a prospective controlled trial. *Ophthalmology.* 2004;111(2):218-24; discussion 24-5.
- 25.Jonas JB, Kreissig I, Sofker A, Degenring RF. Intravitreal injection of triamcinolone for diffuse diabetic macular edema. *Archives of ophthalmology.* 2003;121(1):57-61.
- 26.Tunc M, Onder HI, Kaya M. Posterior sub-Tenon's capsule triamcinolone injection combined with focal laser photocoagulation for diabetic macular edema. *Ophthalmology.* 2005;112(6):1086-91.
- 27.Kang SW, Sa HS, Cho HY, Kim JI. Macular grid photocoagulation after intravitreal triamcinolone acetonide for diffuse diabetic macular edema. *Arch Ophthalmol.* 2006;124(5):653-8.
- 28.Avitabile T, Longo A, Reibaldi A. Intravitreal triamcinolone compared with macular laser grid photocoagulation for the treatment of cystoid macular edema. *Am J Ophthalmol.* 2005;140(4):695-702.
- 29.Lam DS, Chan CK, Mohamed S, Lai TY, Lee VY, Liu DT, et al. Intravitreal triamcinolone plus sequential grid laser versus triamcinolone or laser alone for treating diabetic macular edema: six-month outcomes. *Ophthalmology.* 2007;114(12):2162-7.
- 30.Haritoglou C, Kook D, Neubauer A, Wolf A, Priglinger S, Strauss R, et al. Intravitreal bevacizumab (Avastin) therapy for persistent diffuse diabetic macular edema. *Retina (Philadelphia, Pa).* 2006;26(9):999-1005.
- 31.Chen E, Hsu J, Park CH. Acute visual acuity loss following intravitreal bevacizumab for diabetic macular edema. *Ophthalmic Surg Lasers Imaging.* 2009;40(1):68-70.
- 32.Soheilian M, Ramezani A, Obudi A, Bijanzadeh B, Salehipour M, Yaseri M, et al. Randomized trial of intravitreal bevacizumab alone or combined with triamcinolone versus macular photocoagulation in

diabetic macular edema. *Ophthalmology*. 2009;116(6):1142-50.

33. Michaelides M, Fraser-Bell S, Hamilton R, Kaines A, Egan C, Bunce C, et al. Macular perfusion determined by fundus fluorescein angiography at the 4-month time point in a prospective randomized trial of intravitreal bevacizumab or laser therapy in the management of diabetic macular edema (Bolt Study): Report 1. *Retina (Philadelphia, Pa)*. 2010;30(5):781-6.

34. Lim JW, Lee HK, Shin MC. Comparison of intravitreal bevacizumab alone or combined with triamcinolone versus triamcinolone in diabetic macular edema: a randomized clinical trial. *Ophthalmologica Journal international d'ophtalmologie International journal of ophthalmology Zeitschrift fur Augenheilkunde*. 2012;227(2):100-6.