



CODEN [USA]: IAJPBB

ISSN: 2349-7750

**INDO AMERICAN JOURNAL OF
PHARMACEUTICAL SCIENCES**<http://doi.org/10.5281/zenodo.1067101>Available online at: <http://www.iajps.com>**Research Article****THE EFFECT OF TOPICAL BEVACIZUMAB ON CORNEAL
NEOVASULARIZATION IN A RABBIT MODEL****Ali Kasiri and Hesam Hedayati**Department of Ophthalmology, Ahvaz Jundishapur University of Medical Sciences,
Ahvaz, Iran**Abstract:**

Objectives: To evaluate the effect of topical bevacizumab for treatment of the corneal neovascularization (CNV) in a rabbit model of corneal injury.

Methods: Corneal neovascularization was induced by 3 sutures of the cornea in 20 rabbits (20 corneas). Two weeks later all sutures have been removed then rabbits were divided randomly into 2 groups: group 1 received topical bevacizumab at 10 mg/mL and group 2 received only topical normal saline drops as control group, in the right eyes three times a day for two weeks. Photographs of (CNV) were obtained before drug administration and at 1 and 2 weeks after therapy. The images were analyzed using NIH Image J 1.49c software.

Results: The mean percentage of CNV area estimated as 100 % before treatment. At the 1 week after treatment, the mean percentage of neovascularization area in Bevacizumab and Salin group were 75.64±4.32 and 93.33±4.57 respectively. Also at the 2 week after treatment were 61.45±6.18 and 84.96±5.21 respectively. After one and two weeks treatment, the neovascularization area in Bevacizumab group was regressed more than saline group significantly ($P < 0.0001$).

Conclusions: Topical administration of Bevacizumab reduces corneal neovascularization in the short term, so it can be used for treatment of corneal neovascularization.

Key words: Corneal Neovascularization, Bevacizumab, Topical.

Corresponding author:**Ali Kasiri,**Department of Ophthalmology,
Ahvaz Jundishapur University of Medical Sciences,
Ahvaz, Iran.Email: Alikasiri343@gmail.com

QR code



Please cite this article in press as Ali Kasiri and Hesam Hedayati., *The Effect of Topical Bevacizumab on Corneal Neovascularization in a Rabbit Model*, *Indo Am. J. P. Sci*, 2017; 4[11].

INTRODUCTION:

Corneal neovascularization (CNV) is a common consequence of various inflammatory, infectious, and traumatic corneal disorders [1]. Neovascularization (NV) induces tissue scarring, lipid deposition, stromal hemorrhage, and corneal edema, all of which severely alter visual acuity [2]. In addition, vascularity reduces the immune privilege of the cornea and the likelihood of graft survival in patients who subsequently elect to undergo penetrating keratoplasty [3].

Angiogenesis is mediated by several different factors, including vascular endothelial growth factor (VEGF) and platelet-derived growth factor (PDGF). VEGF is a homodimeric glycoprotein, heparin-binding growth factor specific to vascular endothelial cells, commonly considered the most prominent angiogenic factor. Within the VEGF family, VEGF-A is considered to be the major factor involved in hemangiogenesis and has received the most attention as the mediator of pathologic NV [2–5]. VEGF and its tyrosine kinase receptors, VEGF Receptor1 and VEGF Receptor2, promote many aspects of the angiogenic process [4–8, 22].

Bevacizumab is a recombinant humanized monoclonal immunoglobulin G1 antibody directed against all isoforms of VEGF-A. It has been used in the off-label treatment of exudative age-related macular degeneration, proliferative diabetic retinopathy, and iris rubeosis.[2,10]. Topical and subconjunctival routes of bevacizumab administration have been investigated in experimental models and in human clinical cases examining the treatment of CNV. The majority of experimental and clinical studies have shown a statistically significant, but incomplete, reduction in the parameters reflecting NV [4–8, 35].

So the purpose of the present study was to investigate the anti-angiogenic effects of topical administration bevacizumab in experimentally induced CNV in a rabbit model.

MATERIALS AND METHODS:

In this study, 20 male wild brown rabbits, weighing 1500 to 1900 g, were used. The protocol for this experimental study was approved by the Institutional Animal Care and Use Committee of Ahvaz Jundishapur University of Medical Sciences. Animal maintenance and all in vivo experiments were performed in accordance with the institutional guidelines and the Association for Research in Vision and Ophthalmology (ARVO) Statement.

The animals were anesthetized by IM injections of tile amine (2.5 mg/kg body weight), zolazepam (2.5 mg/kg), and xylazine (3.45 mg/kg) if needed. After the application of topical tetracain, Three 7-0 silk

sutures were placed radially, at midstromal depth, at the 10-, 12-, and 2-o'clock positions on the corneas of the right eyes, avoiding corneal perforation. Topical ciprofloxacin was instilled twice a day to minimize the risk of infection after surgery. Corneal sutures were removed 2 weeks after suture placement. After suture removal, the 20 rabbits were divided into 2 groups, with 10 rabbits in each group. In groups 1 and 2, the right eyes received topical applications of bevacizumab (10 mg/mL), and saline respectively. The solutions were administered three times a day for 2 weeks, starting immediately after suture removal. The concentrations of topical bevacizumab were chosen from previous studies [14,16].

All treated and control eyes were photographed using a charge-coupled device (CCD) camera attached to a slit-lamp bio microscope at $\times 40$ magnification. Photographs were obtained before drug administration and at 1 and 2 weeks after therapy.

The images were analyzed using NIH Image J 1.49 software. The resolution of each image was 640 · 480 pixels. All images were converted to tagged information file format (TIFF) files. The quantification of NV throughout the entire cornea was performed in a blinded fashion to minimize sampling bias. The area of corneal vasculature was outlined with the computer mouse and calculated using the image software. To control for individual variation in the area of NV induced by the suture, the area before anti-neovascular treatment was set at 100%, and post treatment area values were presented as the percentage of the remaining NV. This approach to measurement is consistent with that described previously [38–45].

Statistical analyses were performed using SPSS software version 21.0 for Windows.

The Mann–Whitney U test was used to compare between administrations of two drugs. Differences were considered statistically significant when P values were less than 0.05.

RESULTS:

Bio microscopic examination of rabbit's eyes at one and two weeks after the initiation of treatment revealed that corneal neovascularization in eyes that received bevacizumab had regressed more than those received saline (Figure 1).

The mean percentage of corneal neovascularization area estimated as 100 % before treatment. At the 1 week after treatment, the mean percentage of neovascularization area in bevacizumab and saline group were 75.64 ± 4.32 and 93.33 ± 4.57

respectively. Also at the 2 week after treatment were 61.45 ± 6.18 and 84.96 ± 5.21 respectively (Table-1). After 1 week treatment, the neovascularization area in bevacizumab group was regressed more than saline group significantly ($P < 0.0001$) (Figure-2). After 2 week treatment, the neovascularization area in bevacizumab groups was regressed more than saline group significantly ($P < 0.0001$) (Figure-2). Figure-3 showed the changes of corneal neovascularization area in two

weeks treatment. The mean percentage of changes of corneal neovascularization area in bevacizumab and saline groups were 38.55 ± 6.18 and 15.04 ± 5.21 respectively (Table-2).

The mean percentage of regression of corneal neovascularization area in bevacizumab group were different to saline group significantly ($P < 0.0001$) (Figure-3).

Table 1: Comparison between two groups

Group	After 1 week	After 2 weeks
Bevacizumab	75.64 ± 4.32	61.45 ± 6.18
Normal Saline	93.33 ± 4.57	84.96 ± 5.21

Table 2: Comparison between two groups

Group	Mean changes
Bevacizumab	38.55 ± 6.18
Normal Saline	15.04 ± 5.21

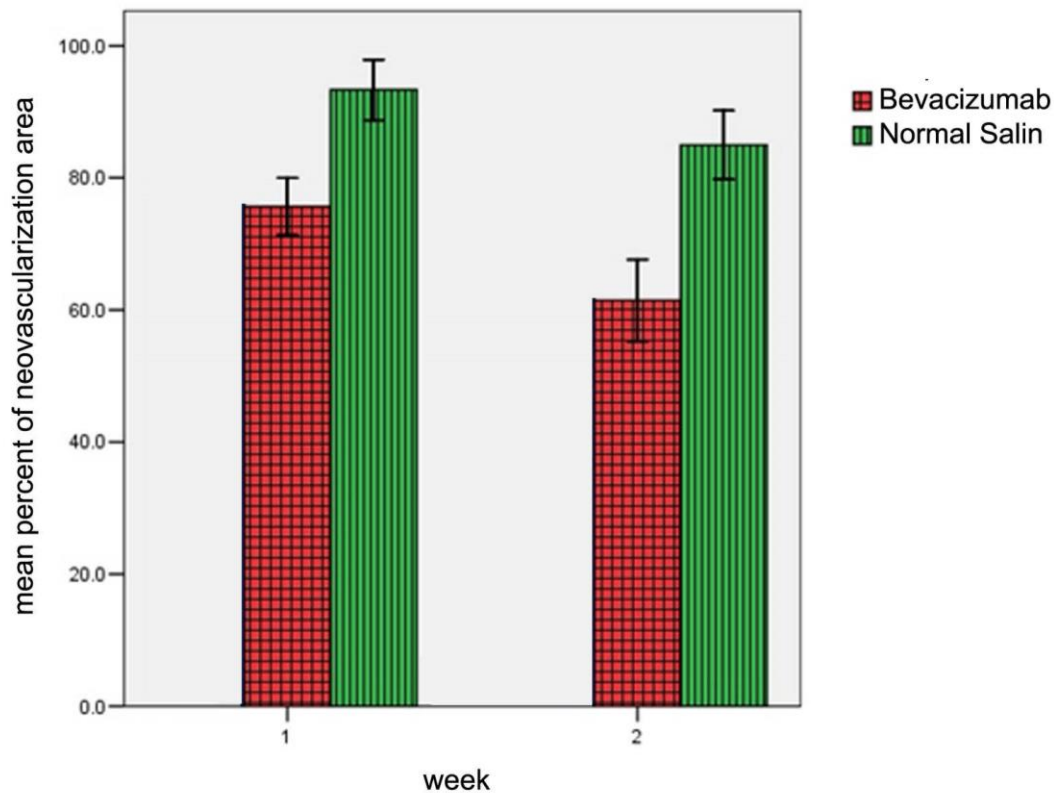


Fig 1: Comparison the mean±SD between two groups after 1 & 2 weeks

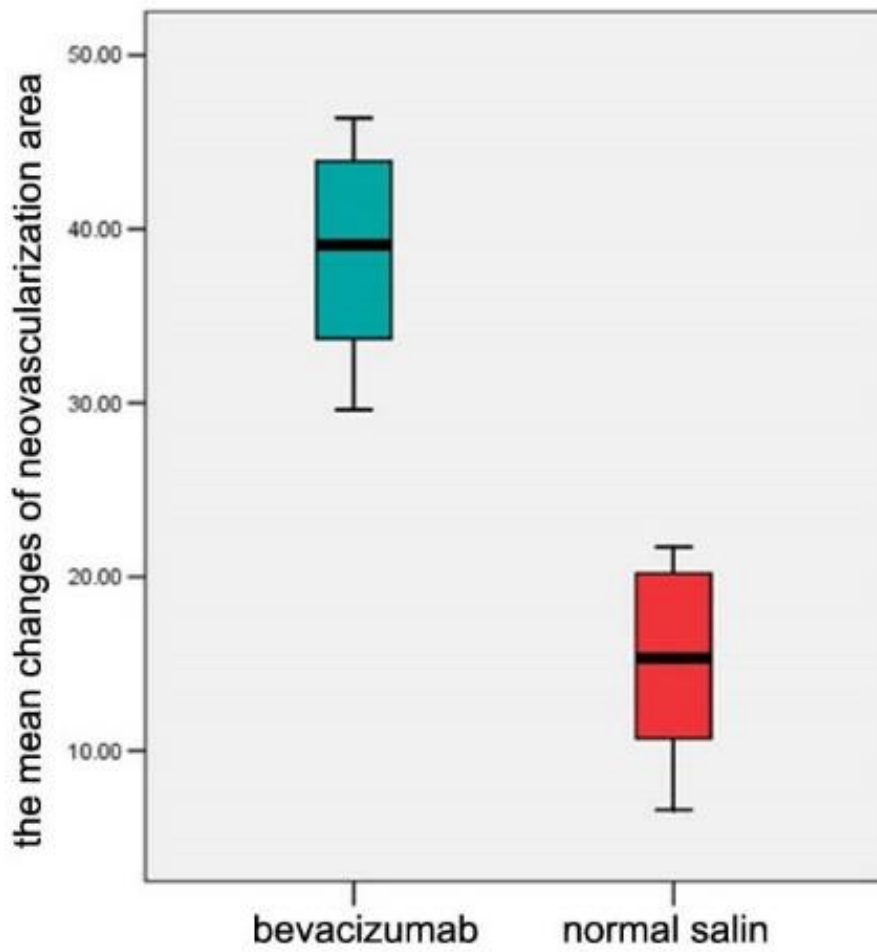


Fig 2: Comparison the mean±SD between two groups after 2 weeks

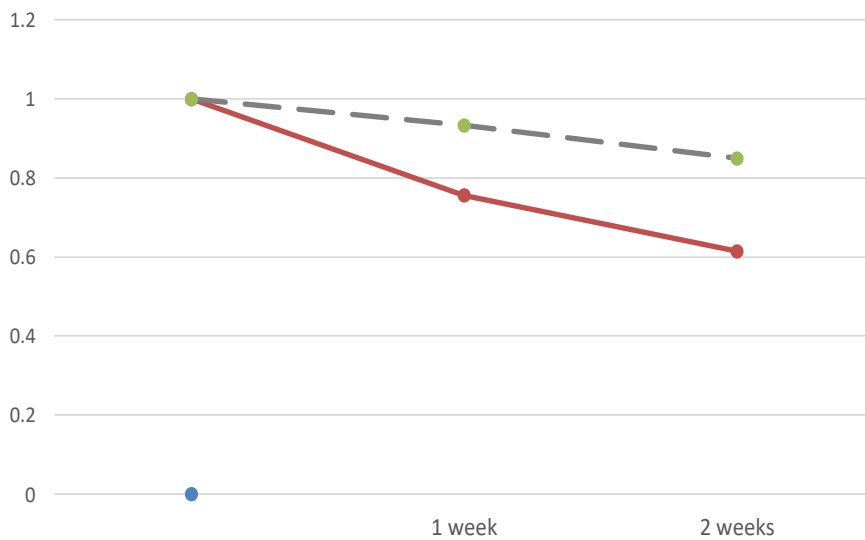


Fig 3: Comparison the regression of CN between two groups

DISCUSSION:

The treatment of CNV can be challenging and problematic.[4-8]. Various antiangiogenic therapy strategies have been used to interfere with the VEGF system. At the present time, the clinical focus in the treatment of CNV involves the use of antibodies to VEGF.22 several studies have demonstrated the effect of topical bevacizumab in the inhibition of CNV, with figures ranging 20% to 79.7% in reports describing animal experiments [4-8].

Kim TI et al in 2008 have reported subconjunctival injection of bevacizumab can inhibit experimental corneal neovascularization significantly [44]. Hashemian et al in 2011 and Oner V et al in 2012 have reported nonsignificant difference statistically between topical and subconjunctival bevacizumab for corneal neovascularization in an experimental rat model but both of them were effective [(39,40)]. In our study topical bevacizumab has been evaluated and it was effective but subconjunctival bevacizumab injection not performed. Kim J et al in 2013 have shown topically administered bevacizumab had longer standing anti-angiogenic effect than subconjunctivally injected bevacizumab in rat corneal neovascularization. They reported observations of epitheliopathy and corneal thinning after topical bevacizumab. These adverse effects generally appeared during the second month of treatment. On the contrary, in the current study, no instance of epitheliopathy or corneal thinning was observed. This may be because the study lasted for only 2 weeks, which may be too short a period to allow for the development of epitheliopathy [41].

The results of our experiments demonstrated that regression of corneal neovascularization area in topical bevacizumab group was different to saline group significantly, 2.56-fold after 2 weeks.

CONCLUSIONS:

Our findings strengthen the hypothesis that anti-VEGF can efficiently counteract neovascularization and show topical bevacizumab can regress corneal neovascularization in short term period. Our study suggest that topical eye application of bevacizumab can represent an alternative delivery route to subconjunctival injection thus avoiding the risk of associated complications and side effects that could make this drug unsafe in long term treatment.. However, the evaluation of multiple doses of topical bevacizumab and the efficacy and side effects of long term treatment for corneal neovascularization needs more investigations. The limitations of our study include the short follow-up period and the lack of information about the biocompatibility of topical bevacizumab. Further trials with longer periods of follow-up will be necessary. Further studies of the optimal dosage,

treatment interval, and duration are also recommended.

REFERENCES:

- 1.DelMonte DW, Kim T. Anatomy and physiology of the cornea. *J Cataract Refract Surg.* 2011;37(3):588-98.
- 2.Chang JH, Gabison EE, Kato T, Azar DT. Corneal neovascularization. *Curr Opin Ophthalmol.* 2001;12(4):242-9.
- 3.Lee P, Wang CC, Adamis AP. Ocular neovascularization: an epidemiologic review. *Survey of ophthalmology.* 1998;43(3):245-69.
- 4.Perez-Santonja JJ, Campos-Mollo E, Lledo-Riquelme M, Javaloy J, Alio JL. Inhibition of corneal neovascularization by topical bevacizumab (Anti-VEGF) and Sunitinib (Anti-VEGF and Anti-PDGF) in an animal model. *American journal of ophthalmology.* 2010;150(4):519-28.e1.
- 5.Perez-Santonja JJ, Campos-Mollo E, Lledo-Riquelme M, Fernandez-Sanchez L, Cuenca-Navarro N. Vascular morphological and microdensity changes of corneal neovascularization induced by topical bevacizumab and sunitinib in an animal model. *Archivos de la Sociedad Espanola de Oftalmologia.* 2013;88(12):473-81.
- 6.Tunik S, Nergiz Y, Keklikci U, Akkus M. The subconjunctival use of cetuximab and bevacizumab in inhibition of corneal angiogenesis. *Graefe's archive for clinical and experimental ophthalmology = Albrecht von Graefes Archiv fur klinische und experimentelle Ophthalmologie.* 2012;250(8):1161-7.
- 7.Stevenson W, Cheng SF, Dastjerdi MH, Ferrari G, Dana R. Corneal neovascularization and the utility of topical VEGF inhibition: ranibizumab (Lucentis) vs bevacizumab (Avastin). *The ocular surface.* 2012;10(2):67-83.
- 8.Akar EE, Oner V, Kucukerdonmez C, Aydin Akova Y. Comparison of subconjunctivally injected bevacizumab, ranibizumab, and pegaptanib for inhibition of corneal neovascularization in a rat model. *International journal of ophthalmology.* 2013;6(2):136-40.
- 9.Ristori C, Filippi L, Dal Monte M, Martini D, Cammalleri M, Fortunato P, et al. Role of the adrenergic system in a mouse model of oxygen-induced retinopathy: antiangiogenic effects of beta-adrenoreceptor blockade. *Investigative ophthalmology & visual science.* 2011;52(1):155-70.
- 10.Bancalari A, Schade R, Munoz T, Lazcano C, Parada R, Pena R. Oral propranolol in early stages of retinopathy of prematurity. *J Perinat Med.* 2016.
- 11.Huang X, Yang Z, Wang Y. Propranolol as a possible new pharmacologic treatment of retinopathy of prematurity. *Zhonghua Er Ke Za Zhi.* 2015;53(7):555-7.

12. Bührer C, Bassler D. Oral Propranolol: A New Treatment for Infants with Retinopathy of Prematurity? *Neonatology*. 2015;108(1):49-52.
13. Filippi L, Cavallaro G, Bagnoli P, Dal Monte M, Fiorini P, Donzelli G, et al. Oral propranolol for retinopathy of prematurity: risks, safety concerns, and perspectives. *J Pediatr*. 2013;163(6):1570-7.e6.
14. Dal Monte M, Casini G, la Marca G, Isacchi B, Filippi L, Bagnoli P. Eye drop propranolol administration promotes the recovery of oxygen-induced retinopathy in mice. *Exp Eye Res*. 2013;111:27-35.
15. Martini D, Monte MD, Ristori C, Cupisti E, Mei S, Fiorini P, et al. Antiangiogenic effects of beta2 -adrenergic receptor blockade in a mouse model of oxygen-induced retinopathy. *J Neurochem*. 2011;119(6):1317-29.
16. Simavli H, Erdurmus M, Terzi EH, Bucak YY, Onder HI, Kukner AS. The effect of beta receptor blockade through propranolol on corneal neovascularization. *J Ocul Pharmacol Ther*. 2014;30(8):650-6.
17. Hosseini H, Nejabat M. A potential therapeutic strategy for inhibition of corneal neovascularization with new anti-VEGF agents. *Med Hypotheses*. 2007;68(4):799-801.
18. Zhang SX, Ma JX. Ocular neovascularization: Implication of endogenous angiogenic inhibitors and potential therapy. *Prog Retin Eye Res*. 2007;26(1):1-37.
19. West SK. Trachoma: new assault on an ancient disease. *Prog Retin Eye Res*. 2004;23(4):381-401.
20. Zheng M, Schwarz MA, Lee S, Kumaraguru U, Rouse BT. Control of stromal keratitis by inhibition of neovascularization. *Am J Pathol*. 2001;159(3):1021-9.
21. Dana MR, Schaumberg DA, Kowal VO, Goren MB, Rapuano CJ, Laibson PR, et al. Corneal neovascularization after penetrating keratoplasty. *Cornea*. 1995;14(6):604-9.
22. Robinson CJ, Stringer SE. The splice variants of vascular endothelial growth factor (VEGF) and their receptors. *J Cell Sci*. 2001;114(Pt 5):853-65.
23. Gan L, Fagerholm P, Palmblad J. Expression of basic fibroblast growth factor in rabbit corneal alkali wounds in the presence and absence of granulocytes. *Acta Ophthalmol Scand*. 2005;83(3):374-8.
24. Kojima T, Chang JH, Azar DT. Proangiogenic role of ephrinB1/EphB1 in basic fibroblast growth factor-induced corneal angiogenesis. *Am J Pathol*. 2007;170(2):764-73.
25. Visse R, Nagase H. Matrix metalloproteinases and tissue inhibitors of metalloproteinases: structure, function, and biochemistry. *Circ Res*. 2003;92(8):827-39.
26. Zhang H, Li C, Baciu PC. Expression of integrins and MMPs during alkaline-burn-induced corneal angiogenesis. *Invest Ophthalmol Vis Sci*. 2002;43(4):955-62.
27. Sakimoto T, Shoji J, Yamada A, Sawa M. Upregulation of matrix metalloproteinase in tear fluid of patients with recurrent corneal erosion. *Jpn J Ophthalmol*. 2007;51(5):343-6.
28. Shin SH, Kim JC, Chang SI, Lee H, Chung SI. Recombinant kringle 1-3 of plasminogen inhibits rabbit corneal angiogenesis induced by angiogenin. *Cornea*. 2000;19(2):212-7.
29. Gabison E, Chang JH, Hernandez-Quintela E, Javier J, Lu PC, Ye H, et al. Anti-angiogenic role of angiostatin during corneal wound healing. *Exp Eye Res*. 2004;78(3):579-89.
30. Hanai J, Dhanabal M, Karumanchi SA, Albanese C, Waterman M, Chan B, et al. Endostatin causes G1 arrest of endothelial cells through inhibition of cyclin D1. *J Biol Chem*. 2002;277(19):16464-9.
31. Abdollahi A, Hahnfeldt P, Maercker C, Grone HJ, Debus J, Ansorge W, et al. Endostatin's antiangiogenic signaling network. *Mol Cell*. 2004;13(5):649-63.
32. Lai LJ, Xiao X, Wu JH. Inhibition of corneal neovascularization with endostatin delivered by adeno-associated viral (AAV) vector in a mouse corneal injury model. *J Biomed Sci*. 2007;14(3):313-22.
33. Notari L, Miller A, Martinez A, Amaral J, Ju M, Robinson G, et al. Pigment epithelium-derived factor is a substrate for matrix metalloproteinase type 2 and type 9: implications for downregulation in hypoxia. *Invest Ophthalmol Vis Sci*. 2005;46(8):2736-47.
34. Abe R, Fujita Y, Yamagishi S, Shimizu H. Pigment epithelium-derived factor prevents melanoma growth via angiogenesis inhibition. *Curr Pharm Des*. 2008;14(36):3802-9.
35. Sinapis CI, Routsias JG, Sinapis AI, Sinapis DI, Agrogianis GD, Pantopoulou A, et al. Pharmacokinetics of intravitreal bevacizumab (Avastin(R)) in rabbits. *Clin Ophthalmol*. 2011;5:697-704.
36. Padrini L, Isacchi B, Bilia AR, Pini A, Lanzi C, Masini E, et al. Pharmacokinetics and local safety profile of propranolol eye drops in rabbits. *Pediatr Res*. 2014;76(4):378-85.
37. Hamdan J, Boulze M, Aziz A, Alessi G, Hoffart L. Corneal neovascularisation treatments compared: Subconjunctival bevacizumab injections and/or photodynamic therapy. *J Fr Ophtalmol*. 2015;38(10):924-33.
38. Turkcu FM, Cinar Y, Turkcu G, Sahin A, Cingu AK, Yuksel H, et al. Topical and subconjunctival ranibizumab (lucentis) for corneal neovascularization in experimental rat model. *Cutan Ocul Toxicol*. 2014;33(2):138-44.
39. Oner V, Kucukerdonmez C, Akova YA, Colak A, Karalezli A. Topical and subconjunctival bevacizumab for corneal neovascularization in an experimental rat model. *Ophthalmic Res*. 2012;48(3):118-23.

40. Hashemian MN, H ZM, Moghimi S, Tahvildari M, Mojazi-Amiri H. Prevention of corneal neovascularization: comparison of different doses of subconjunctival bevacizumab with its topical form in experimental rats. *Ophthalmic Res.* 2011;46(1):50-4.
41. Kim J, Kim D, Kim ES, Kim MJ, Tchah H. Topically administered bevacizumab had longer standing anti-angiogenic effect than subconjunctivally injected bevacizumab in rat corneal neovascularization. *Int J Ophthalmol.* 2013;6(5):588-91.
42. Ko BY, Kim YS, Baek SG, Lee GW, Kim JM, Jean WS, et al. Inhibition of corneal neovascularization by subconjunctival and topical bevacizumab and sunitinib in a rabbit model. *Cornea.* 2013;32(5):689-95.
43. Hosseini H, Nowroozzadeh MH, Salouti R, Nejabat M. Anti-VEGF therapy with bevacizumab for anterior segment eye disease. *Cornea.* 2012;31(3):322-34.
44. Kim TI, Kim SW, Kim S, Kim T, Kim EK. Inhibition of experimental corneal neovascularization by using subconjunctival injection of bevacizumab (Avastin). *Cornea.* 2008;27(3):349-52.
45. Chang JH, Garg NK, Lunde E, Han KY, Jain S, Azar DT. Corneal neovascularization: an anti-VEGF therapy review. *Surv Ophthalmol.* 2012;57(5):415-29.
46. Lin CT, Hu FR, Kuo KT, Chen YM, Chu HS, Lin YH, et al. The different effects of early and late bevacizumab (Avastin) injection on inhibiting corneal neovascularization and conjunctivalization in rabbit limbal insufficiency. *Invest Ophthalmol Vis Sci.* 2010;51(12):6277-85.
47. Ristori C, Filippi L, Dal Monte M, Martini D, Cammalleri M, Fortunato P, et al. Role of the adrenergic system in a mouse model of oxygen-induced retinopathy: antiangiogenic effects of beta-adrenoreceptor blockade. *Invest Ophthalmol Vis Sci.* 2011;52(1):155-70.
48. Charan J, Kantharia ND. How to calculate sample size in animal studies? *J Pharmacol Pharmacother.* 2013;4(4):303-6.
49. Schneider CA, Rasband WS, Eliceiri KW. NIH Image to ImageJ: 25 years of image analysis. *Nat Methods.* 2012;9(7):671-5.