



CODEN [USA]: IAJPBB

ISSN: 2349-7750

**INDO AMERICAN JOURNAL OF
PHARMACEUTICAL SCIENCES**<http://doi.org/10.5281/zenodo.832437>Available online at: <http://www.iajps.com>

Case Report

**APLASTIC ANEMIA WITH SUB CONJUNCTIVAL
HAEMORRHAGE AND PAROXYSMAL NOCTURNAL
HAEMOGLOBINURIA: A RARE CASE REPORT**Swathi. D^{1*}, Ramesh Kumar Reddy. P¹, Dr. R. Siddarama²¹Pharm D intern, CES College of Pharmacy, Kurnool, A.P – 518218²Assistant Professor, Department of Pharmacy Practice, CES College of Pharmacy, Kurnool, A.P – 518218, India.**Abstract:**

This Case report describes a case of idiopathic acquired aplastic anemia in an 18-year-old male patient with petechial rash, sub conjunctival haemorrhage and paroxysmal nocturnal haemoglobinuria. Patient was treated with elthrombopag olamine- 50mg and cyclosporine- 200mg these two drugs are showing good response in most of the patients with Aplastic anemia in the absence of human leucocytes antigen (HLA) matched sibling donor. In some studies good response was shown for elthrombopag olamine 150mg/day. In this patient only 50mg of elthrombopag olamine is given, patient was died because of the febrile neutropenia. The dose adjustment of drugs in this patient was necessary; this is the responsibility of clinical pharmacist by giving suggestions to physician to adjust the doses as per the patient response towards the therapy.

Keywords: *Aplastic anaemia, proximal nocturnal hemoglobinuria, Elthrombopag olamine, subconjunctival haemorrhage*

Corresponding Author:**Swathi. D,**

Pharm D Intern,

Department of Pharmacy Practice,

CES College of Pharmacy,

Kurnool, A.P – 518218, India.

E-mail : swathidudyala5@gmail.com.

QR code



Please cite this article in press as Swathi. D et al, *aplastic Anemia with Sub Conjunctival Haemorrhage and Paroxysmal Nocturnal Haemoglobinuria: a Rare Case Report*, Indo Am. J. P. Sci, 2017; 4(07).

INTRODUCTION:

Aplastic anemia is a rare, life threatening haematological disorder characterized by pancytopenia and hypo cellular bonemarrow [1-3]. The incidence of acquired AA in the Western hemisphere is around 2 per million population per year and higher in East Asia. Age distribution shows peaks in children and young adults and again in patients age > 60 years[2].

Aplastic anaemia is caused by destruction of pluripotent stem cells in the bone marrow. These are responsible for making red blood cells (which carry oxygen), white blood cells

(Which fight infection), platelets (helps to blood clot) [1,2]. Most cases of a plastic anaemia are acquired and immune mediated but they are also inherited forms [1,2]. Toxins, drugs, viruses and prior radio chemotherapy are several causes for the acquired a plastic anaemia. They trigger immune response in some patients, but most cases are idiopathic [1,2,5].

Severe a plastic anaemia (SAA) is treated with Haematopoietic Stem Cell Transplantation (HSCT), if matched Human Leucocyte Antigen (HLA) matched sibling donor. In the majority of cases, Immunosuppressive Therapy (IST) is often used first because most patients are not suitable candidates for HSCT due to age, co morbidities, or lack of a histocompatible sibling donor. The current standard immunosuppressive regimen is the combination of horse ATG (h-ATG) + (CsA) cyclosporine. In late 1970's ATG was introduced and the addition of CsA to ATG in the 1980's led to a significant improvement in haematopoietic recovery and better survival in patients with SAA [11].

Aplastic anemia usually presents with anemia, bleeding and infection. Ocular findings include dry eye, sub conjunctival haemorrhage, eye lid haematoma, retinal haemorrhage, central retinal vein occlusion, vitreous haemorrhage, cotton wool spots and optic neuropathy [1,5,6].

Paroxysmal nocturnal haemoglobinuria (PNH) present in patient with severe aplastic anaemia[8] ("Paroxysmal" means "sudden,"

"nocturnal" means "at night" "and" hemoglobinuria" means "blood in the urine.") PNH is a rare and serious blood disease that causes red blood cells to break apart. Stem cells in the bone marrow can grow into red cells, white cells, and platelets. The complement system is a group of proteins in the blood that work together to attack and destroy abnormal cells in the body. Normal red blood cells have a shield of proteins that protects the cells from being attacked by the complement system. The gene in charge of making this protective shield is called PIG-A [7].

PNH due to an acquired mutation of the *PIG-A* gene in one or more hematopoietic stem cells

leading to deficiency of Glycosyl Phosphatidyl Inositol-Anchored Proteins (GPI-AP) on the cell surface. The emergences of GPI-anchored protein-deficient cells primarily occurs in the setting of bone marrow failure, and about 40-50% of Aplastic anemia patients detected with PNH clone [8]. PNH clone can be detected by *Flow cytometry* it gives information about Proteins on the surface of blood cells.

PNH patients are experience with some other symptoms other than dark colour urine passing they include oesophageal spasm leading to difficulty in swallowing of food, trouble in breathing, irregular heartbeats, thrombosis (At least 1 out of 3 people with PNH would get thrombosis), low white blood cells leading to more prone to infections, low platelets count leading to bleeding, low RBC leading to fatigue, low appetite, paler skin, breathing difficulty [7].

CASE REPORT:

A 18 yrs old male patient previously diagnosed with acquired aplastic anemia was admitted in the Vishwabharathi Superspeciality hospital, Kurnool, Andhra Pradesh with chief complaints of fever since morning on the day of admission, epistaxis since 5 hrs, petechial spots on the skin (**fig.no.1**) and generalised weakness. Previously he was prescribed with elthrombopag olamine 50mg once daily, used for 3months and discontinued for a month and again started; now he was on elthrombopag olamine since 6months. A relevant family history was absent.

On the day of admission his physical examinations were found to be Body temperature- 103°F, pulse rate- 160 bpm, BP- 120/70 mm of hg, complete blood picture shows that **Hb- 4g/dl**, TLC- 1,500 cells/cumm, Neutrophils- 30%, Lymphocytes- 65%, Eosinophils- 3%, Monocytes- 2%, platelet count- 30,000 cells/cumm, ESR- 65%. Liver function tests showing that total bilirubin- 1.6mg/dl, direct bilirubin- 0.9mg/dl, alkaline phosphate levels- 680 U/L.

Treatment regimen include- elthrombopag olamine was continued in addition to that tranexamic acid- 200mg/2ml BD, ethamsylate- 125mg/2ml TID, Amoxicillin+ clavulanic acid - 1.2g BD, Levofloxacin 500mg OD given through IV. Cyclosporin- 200mg in the morning and 100mg in the night, folic acid-5mg, and paracetamol-650 mg was given through oral route. One bag of whole blood transfusion was done.

Second day epistaxis was decreased, patient had fever, conjunctival haemorrhage (**Fig.No.2**), tachycardia and haematuria in the early morning. Complete blood picture showing that Hb- 6g/dl, TLC- 2,000 cells/cumm, Neutrophils-32%, Leucocytes- 64%, Eosinophils-3%, Monocytes-2%, Platelet count- 45,000 cells/cumm, ESR- 65mm/hr.

same treatment regimen was continued. Fresh Blood transfusion was done.

Third day patient with fever, haematuria, conjunctival haemorrhage, no epistaxis, pulse rate-124 bpm, respiratory rate- 35 cpm. Same treatment regimen was continued, paracetamol tablet was changed to IV infusion. Fourth day patient was with fever and nasal blockage. In addition to the previous regimen levocitrizine 5mg OD was added and otrivine (xylometazoline) nasal drops TID were given to the patient. Fifth day patient temperature was decreased and no other complaints from patient. Complete blood picture showing that Hb-7.4g/dl, TLC- 3,000 cells/cumm, Neutrophils-30%, Lymphocytes- 65%, Eosiniphils- 3%, Monocytes-2%, platelet count- 50,000, ESR- 74 mm/hr. on sixth day also no fresh complaints from patient same treatment regimen was continued. On the seventh day patient had facial puffiness (**Fig.No.3**), pedal oedema, malena, epistaxis. In addition to the

previous treatment regimen hydrocortisone 100mg through IV was given. On the eighth day patient was with facial puffiness, nasal blockage and haematuria. Complete blood picture showing that Hb- 5g/dl, TLC- 2,500 cells/cumm, Neutrophils-30%, Lymphocytes- 65%, Eosiniphils- 3%, Monocytes- 2%, platelet count- 60,000, ESR- 98 mm/hr. In addition to the daily treatment regimen chymoral forte tablet OD was given. On the ninth day also patient was with similar complaints, same treatment regimen was continued. Blood transfusion was done. On the 10th day patient had similar complaints and on the same treatment regimen there is no improvement of patient condition, on the 11th day patient was died due to febrile neutropenia. Eser et al mentioned in his study during the course of the aplastic anemia infection followed by neutopenia leads death [3].

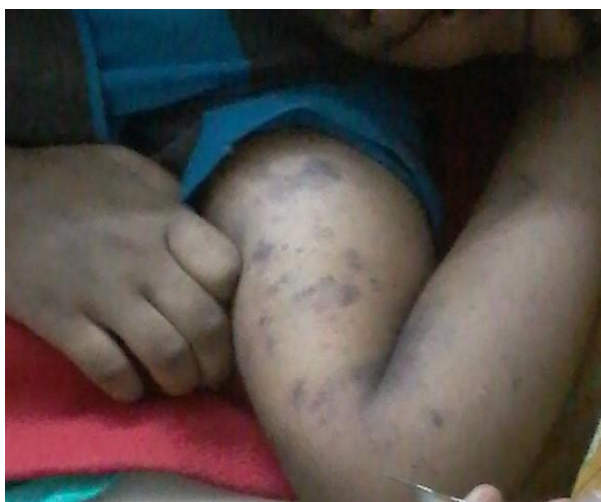

Fig.No.1 petechiae on the patient skin

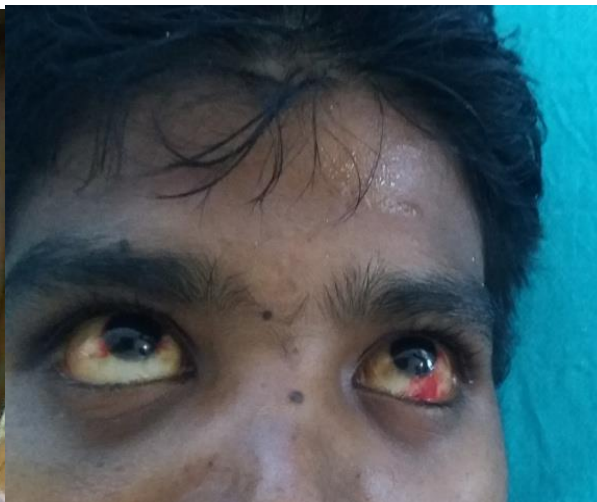

fig.No.2 conjunctival bleeding

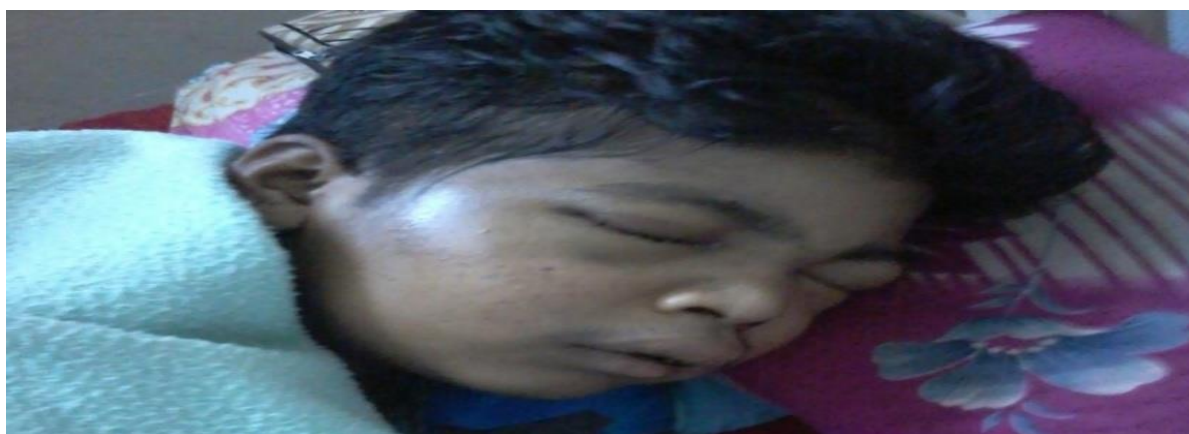


Fig.No.3 facial puffiness

DISCUSSION:

Aplastic anemia is a rare, life threatening haematological disorder characterized by pancytopenia and hypocellular bonemarrow [1-3]. The annual incidence of Aplastic anemia is about 2 cases per million population [2,4]. Acquired aplastic anemia is most commonly presents between the ages of 15 and 25years. But there is a second smaller peak incidence after the age 60 years [2,4]. Mansour et al shown in his retrospective study, 78% of cases of aplastic anemia exhibit ophthalmic manifestations. Typical ophthalmic manifestations in aplastic anaemia include eyelid hematoma, sub conjunctival haemorrhage, cotton wool spots, retinal nerve fiber layer haemorrhage, roth's spots, pre-retinal haemorrhage, vitreous haemorrhage and disc edema. In that majority of the patients with pre-retinal haemorrhages, only one patient identified with sub conjunctiva haemorrhage. This study showing that sub conjunctival haemorrhages are the rare ocular manifestations in Aplastic anemic patients [5].

This sub conjunctival haemorrhage is due to the breaking of the tiniest blood vessels in the conjunctiva and cause leaking the blood in between the conjunctiva and the sclera it appears as a bright red spots on the white proportion of the eye. In this A plastic anaemic patients the cause for breaking of blood vessels is increased blood pressure in the veins and also severe thrombocytopenia.

Paroxysmal nocturnal haemoglobinuria (PNH) is a rare acquired disease with thrombotic episodes and frequent pancytopenia.⁹ PNH is because of mutations in one or more haematopoietic stem cells. The mutations in the PIG-A gene causes the deficiency of glycosylphosphatidyl ino sitol-anchored proteins on the haemopoetic stem cells [8], these haemopoetic stem cells produce the 3 types of blood cells those are red blood cells, white blood cells, platelets. This PNH is a rare and serious blood diseases in which breaking of red blood cells occur because red blood cells are produced by the mutated haemopoetic cells these abnormal cells are destroyed by complement system in the body [7].

PNH produce variety of symptoms, Apart from the haematuria in the night and early morning other symptoms are also there, those symptoms are because of the haemolysis of red blood cells, thrombosis and low blood cell count [7]. In our case patient had early morning haematuria, difficulty in breathing and swallowing of food, irregular heartbeats and low white blood cells and platelet count, because of the low platelet count patient developed epistaxis condition and petechiae spots on the skin.

Scheinberg et al reported that 40-50% patients with aplastic anaemia have a PNH clone [10] this clones are detected by the flow cytometry. This test

gives the information about proteins on the blood cells [7]. In this case they haven't performed any flow cytometry test based on the symptoms of the patient we are suspecting that this patient had PNH.

CONCLUSION:

In this case, patient was with acquired Aplastic anemia, sub conjunctival haemorrhage and suspected paroxysmal nocturnal haemoglobinuria. Patient therapy includes eltrombopag olamine-50mg, but in other studies for the patient's who had poor response to 50mg, the dosage was increased up to 150mg/day and good response was observed in such patients. So in this dose adjustment area clinical pharmacist play a major role in suggesting dosage regimens to the physician as per the patients response to the treatment regimen.

Conflict of interest: None.

REFERENCES:

- 1.Divyalakshmi K.S. & Kalpana B.N. Ocular manifestations of aplastic anemia following Platelet transfusion : a case report. Nitte university journal of health science 2014; 4:ISSN 2249-7110.
- 2.Haldar B, pal PP, Tarun S, sharma S, Goswami B, Aikat aditi I. aplastic anemia: A common hematological Abnormality among peripheral pancytopenia. North american journal of medical sciences 2012; 4:IP: 157.48.4.219.
- 3.Ali eser, Tanrikulu F P, Tayfur T, suheyla uyar bozkurt, Erdem K, Isik K, Osman K, Ayse T, Fratli T . Successful treatment of severe aplastic anemia with eltrombopag. Medical science and discovery 2016; 3(3): 141-4.
- 4.Dr Laurence Knott, Aplastic anemia [Internet] 18th Feb 2014. Available from: <https://patient.info/in/doctor/aplastic-anaemia>.
- 5.Ahmad M mansour et al. Ocular manifestations of idiopathic aplastic anemia: retrospective study and literature review. Clinical ophthalmology 2014;8 :777-787.
- 6.Nusrat shaheen, junaid S. Wani, a.R. Nasti, m.I. Quadri. Ocular manifestations in anaemia-a clinical study. Jk-practitioner 2005; 12.
- 7.Hill A, Connor M, Orbach T. Copyright© 2008, Aplastic Anemia & MDS International Foundation, Inc.
- 8.Phillip S, Michael M, Olga N et al. Paroxysmal nocturnal hemoglobinuria clones in severe aplastic anemia patients Treated with horse anti-thymocyte globulin plus cyclosporine. Haematologica 2010; 95(7).
- 9.Railene célia B. Alencar; andréa M. Guimarães; lacy C. Brito junior. Report of a case of paroxysmal nocturnal hemoglobinuria (PNH) with complex evolution and liver transplant. J bras patol med lab 2016; 52: 307-311.
- 10.Scheinberg P, Wu CO, Nunez O, Young NS. Predicting response to immunosuppressive therapy and survival in severe aplastic anaemia. *Br J Haematol.* 2009 January; 144(2): 206-216.