



doi:10.4103/2221-6189.244174

©2018 by the Journal of Acute Disease. All rights reserved.

Intracranial hematoma development following thrombolysis inpatients suffering with acute myocardial infarction: Management strategy

Luis Rafael Moscote Salazar^{1✉}, Amit Agrawal², Guru Dutta Satyarthee³, George Chater Cure⁴, Alfonso Pacheco-Hernandez¹

¹Universidad de Cartagena, Cartagena de Indias, Colombia

²Department of Neurosurgery, Narayna Medical College Hospital, Chinthareddypalem, Nellore-524003, Andhra Pradesh, India

³All India Institute of Medical Sciences, New Delhi, India

⁴Clinica General de Norte, Barranquilla, Colombia

ARTICLE INFO

Article history:

Received 16 July 2018

Revision 20 August 2018

Accepted 18 September 2018

Available online 30 October 2018

Keywords:

Acute myocardial infarction

Thrombolysis

Intracranial hematoma

Management

Outcome

ABSTRACT

Intracerebral hemorrhage secondary to thrombolysis in patients with acute myocardial infarction is a catastrophic condition. Several factors predispose to intracranial bleeding including low body weight, female sex, advanced age, use of oral anticoagulants prior to the administration of fibrinolytic therapy, diastolic blood pressure (greater than 110 mm Hg), among others. Optimal medical management involves multidisciplinary roles of hematology, neurosurgery and critical medicine. In this illustrative case, a classification and management algorithm were proposed for patients with complications hemorrhage associated with thrombolysis after myocardial infarction.

1. Introduction

Acute myocardial infarction is considered as a major cause of mortality. The current usage of therapeutic strategies including thrombolysis for management in the acute phase can result in serious complications[1-5]. After the confirmation of the diagnosis of acute myocardial infarction, the proposed management options must take consideration of individual cases and must also take into account of the absolute and relative contraindications of initial and follow-up for thrombolytic therapy. Intracerebral hemorrhage accounts for 10%-15% of all intracranial vascular events in the general population. A number of risk factors for haemorrhagic stroke

are advanced age, hypertension, trauma, vascular malformations, and anticoagulant therapy. Following the use of thrombolytic therapy in patients suffering with acute myocardial infarction, at least half of the vascular events are related to the hemorrhagic manifestation[6-14]. This paper briefly reviews current status of various management options for therapy of intracranial hemorrhage after thrombolysis in acute myocardial infarction.

This is an open access journal, and articles are distributed under the terms of the Creative Commons Attribution-NonCommercial-ShareAlike 4.0 License, which allows others to remix, tweak, and build upon the work non-commercially, as long as appropriate credit is given and the new creations are licensed under the identical terms.

For reprints contact: reprints@medknow.com

©2018 Journal of Acute Disease Produced by Wolters Kluwer- Medknow

How to cite this article: Salazar LRM, Agrawal A, Satyarthee GD, Cure GC, Pacheco-Hernandez A. Intracranial hematoma development following thrombolysis inpatients suffering with acute myocardial infarction: management strategy. *J Acute Dis* 2018; 7(5): 217-219.

✉First and corresponding author: Luis Rafael Moscote Salazar, Universidad de Cartagena, Cartagena de Indias, Colombia.
E-mail: mineurocirujano@aol.com

2. Case illustration

A 66-year-old man was admitted to critical patient unit with a history of sudden chest pain. Evaluation at admission in the emergency department revealed an anxious elderly male had tachypnoea with respiratory rate at 26 per minute and rest of physical examination did not find any abnormality. His peripheral pulses were normal. His electrocardiogram showed a ST-segment elevation and based on ECG finding, a diagnosis of acute myocardial infarction was made and planned for emergency thrombolysis therapy. He underwent thrombolysis therapy with 10 000 IU of tenecteplase and then transferred to an intensive care unit for hemodynamic surveillance. Six hours after the thrombolysis therapy, the patient noticed acute difficulty in speech and right side hemiparesis. Cranial noncontrast CT scan was performed, which revealed presence of intracerebral and ventricular hemorrhage (Figure 1). Fresh plasma was transfused and he was evaluated by neurosurgery. He also underwent external ventricular drainage and kept for seven days. The patient was slowly showing recovery of speech with mild hemiparesis. He was discharged from hospital twenty days after admission.

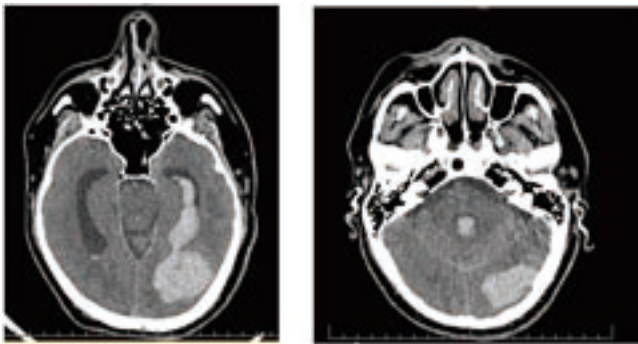


Figure 1. Brain CT showing intracerebral hemorrhage after thrombolysis in a patient with myocardial infarction.

3. Discussion

The use of thrombolytic therapy has shown to limit the size of infarct with preservation of left ventricular function and decrease mortality after an acute myocardial infarction. Risk of thrombolytic therapy commonly include intracranial hemorrhage following thrombolysis in acute myocardial infarction, occurs in about 0.9%-1.0% of cases and is considered as an emergency condition due to its high mortality. The diagnosis of post-thrombolytic haemorrhage in acute myocardial infarction should be considered in any patient who has a focal or sensory neurological deficit after thrombolysis[15]. Its early recognition is essential to establish strategies that allow limiting the evolution of the disease. A study involving 1 696 patients described tomographic patterns in patients with myocardial

infarction, who also underwent pharmacological thrombolysis, the most frequent site was supratentorial and intraparenchymal, and 84% of the symptoms occurred within the first 24 hours of therapy[6]. Al Khuwaitir et al reported the case of a 40-year-old male who underwent surgical evacuation of a right temporoparietal hematoma after thrombolysis with streptokinase[16]. Although the place of bleeding following thrombolysis is the gastrointestinal tract, neurosurgeons should be vigilant before any neurological deficits.

Thrombolytic therapy improves coronary blood flow by the activation of plasmin and the enzyme responsible for fibrin degradation. The most commonly used pharmacological agents are: streptokinase and recombinant plasminogen activator-alteplase, reteplase and tenecteplase. It has been postulated that the development of bleeding areas requires the loss of vascular integrity, dissolution of hemostatic plugs and the depletion of coagulation factors. Intracranial hematomas with large volumes have been associated with higher mortality. Authors proposed a classification of intracranial hemorrhage following thrombolysis in acute myocardial infarction based on the various hemorrhagic patterns. Type I : Supratentorial hemorrhage without hydrocephalus; Type II : Supratentorial multiple hemorrhage without hydrocephalus; Type III: Supratentorial hemorrhage with hydrocephalus; Type IV: Cerebellar hemorrhage with/without hydrocephalus.

The development of an organized approach is crucial for evaluation and treatment of post-thrombolysis intracerebral hemorrhage in myocardial infarction (Figure 2). It is important to emphasize that the algorithm is intended to guide management of post-thrombolysis intracerebral hemorrhage in myocardial infarction. The clinical judgment will be fundamental in the management. Variations in clinical resources available locally will also influence the management. The guidelines of neurocritical care society (2015) for Reversal of Antithrombotics in Intracranial Hemorrhage provided recommendations for thrombolytic reversal: i. To discontinue thrombolytic agents when intracranial hemorrhage is present or suspected (good practice statement), ii. To use cryoprecipitate (10 units initial dose) in patients with thrombolytic agent-related symptomatic intracranial hemorrhage, who received a thrombolytic agent in the previous 24 hours. (Conditional recommendation, low-quality evidence), iii. In cases where cryoprecipitate is contraindicated or not available in a timely manner, we suggest use an antifibrinolytic agent (tranexamic acid 10-15 mg/kg intravenous over 20 min or e-aminocaproic acid 4-5 g intravenous) as an alternative to cryoprecipitate (conditional recommendation, very low-quality evidence). iv. Checking serum fibrinogen levels after administration of reversal agents. If the serum fibrinogen level is less than 150 mg/dL, administration of additional cryoprecipitate (Conditional recommendation, very low-quality evidence). v. It is unclear if platelet transfusion is useful and we cannot offer a recommendation at this time.

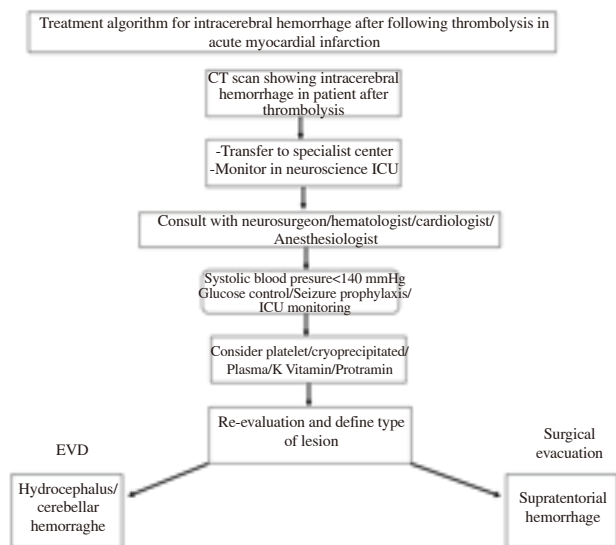


Figure 2. Algorithm for treatment of intracerebral hemorrhage after following post-thrombolysis.

The development of intracerebral hemorrhage following thrombolytic therapy carry a poor prognosis with about 62% mortality during hospitalization. The application of our proposed classification and management algorithm will contribute to better management of patients with this catastrophic pathology. Although there is a lack of enough evidence for recommendation of cryoprecipitate use, we observed improved outcome following administration of fresh frozen plasma.

Conflict of interest statement

The authors declare no conflict of interest.

References

[1] GISSI (Gruppo Italiano per lo Studio della Streptochinasi nell'Infarto miocardio), Effectiveness of intravenous thrombolytic treatment in acute myocardial infarction. *Lancet* 1986; **1**(8478): 397-402.

[2] Patel SC, Mody A. Cerebral hemorrhagic complications of thrombolytic therapy. *Prog Cardiovasc Dis* 1999; **42**: 217-233.

[3] Gore JM, Granger CB, Simoons ML, Sloan MA, Weaver WD, White HD, et al. Stroke after thrombolysis. Mortality and functional outcomes in the GUSTO-I trial. Global use of strategies to open occluded coronary arteries. *Circulation* 1995; **92**: 2811-2818.

[4] Mahaffey KW, Granger CB, Sloan MA, Green CL, Gore JM, Weaver

WD, et al. Neurosurgical evacuation of intracranial hemorrhage after thrombolytic therapy for acute myocardial infarction: Experience from the GUSTO-I trial. Global utilization of Streptokinase and tissue-plasminogen acute myocardial infarction: Experience from the GUSTO-I Trial. *Am Heart J* 1999; **138**: 493.

[5] Uglietta JP1, O'Connor CM, Boyko OB, Aldrich H, Massey EW, Heinz ER. CT patterns of intracranial hemorrhage complicating thrombolytic therapy for acute myocardial infarction. *J Stroke Cerebrovasc Dis* 1991; **181**(2): 555-559.

[6] Fibrinolytic Therapy Trialists' (FTT) Collaborative Group. Indications for fibrinolytic therapy in suspected acute myocardial infarction: collaborative overview of early mortality and major morbidity results from all randomised trials of more than 1 000 patients. *Lancet* 1994; **343**(8893): 311- 322.

[7] De Jaegere PP, Arnold AA, Balk AH, Simoons ML. Intracranial hemorrhage in association with thrombolytic therapy: Incidence and clinical predictive factors. *J Am Coll Cardiol* 1992; **19**: 289-294.

[8] Califf RM, Fortin DF, Tenaglia AN, Sane DC. Clinical risks of thrombolytic therapy. *Am J Cardiol* 1992; **69**: 12A -20A.

[9] Verstraete M, Collen D. Pharmacology of thrombolytic drugs. *J Am Coll Cardiol* 1986; **8**: 33B-40B.

[10] Jorge Sdo C. Endovenous thrombolysis in acute myocardial infarct. The experience in a community hospital. An analysis of 120 patients. *Arq Bras Cardiol* 1992; **59**(1): 23-30.

[11] Lubarsky DA, Kaufman B, Turndorf H. Anesthetic care of a patient with an intracranial hemorrhage after thrombolytic therapy. *J Clin Anesth* 1990; **2**(4): 276-279.

[12] Al-Khuwaitir TS, Wani BA, Dawood HA, Khan MA. Successful outcome after evacuation of intracranial hematoma following thrombolysis in acute myocardial infarction. *Neurosciences* 2005; **10**(1): 96-98.

[13] Frontera JA, Lewin JJ 3rd, Rabinstein AA, Aisiku IP, Alexandrov AW, Cook AM, et al. Guideline for reversal of antithrombotics in intracranial hemorrhage: a statement for healthcare professionals from the Neurocritical Care Society and Society of Critical Care Medicine. *Neurocrit Care* 2016; **24**(1): 6-46.

[14] Al Khuwaitir TS, Wani BA, Dawood HA, Khan MA. Successful outcome after evacuation of intracranial hematoma following thrombolysis in acute myocardial infarction. *Saudi Med J* 2005; **26**(1): 130-132.

[15] Alvis-Miranda HR, M Rubiano A, Agrawal A, Rojas A, Moscote-Salazar LR, Satyarthee GD, et al. Craniocerebral Gunshot Injuries; a review of the current literature. *Bull Emerg Trauma* 2016; **4**(2): 65-74.

[16] Mahanes D. Neurologic assessment after fibrinolytic therapy for myocardial infarction. *Crit Care Nurse* 2013; **33**(2): 78-80.