



Traumatic optic neuropathy secondary to acupuncture treatment for glaucoma: A case report

Wen Yee Lee^{1,2}✉, Wee Min Teh¹, Norlina Mohd Ramli², Ahmad Mt Saad¹

¹ Department of Ophthalmology, Hospital Sultanah Bahiyah, Alor Setar, Kedah, Malaysia

² Department of Ophthalmology, Universiti of Malaya, Petaling Jaya, Selangor, Malaysia

ARTICLE INFO

Article history:

Received 6 April 2018
Revision 13 April 2018
Accepted 21 April 2018
Available 1 May 2018

Keywords:

Acupuncture
Traumatic optic neuropathy
Glaucoma
Vitreous hemorrhage

ABSTRACT

Internal organ injuries have been recognized as a major complication of acupuncture. Reported ocular adverse events include traumatic cataract, oculomotor nerve injury, endophthalmitis and retinal puncture. We report a case of traumatic optic neuropathy and self-sealed globe perforation following acupuncture. A Chinese gentleman with primary open angle glaucoma presented with sudden loss of vision in the right eye after acupuncture therapy. The vision dropped to 2/60 from 6/6 pre-morbid. Relative afferent pupillary defect was present. Fundus examination showed hemorrhage from the optic disc into the vitreous. It is likely that the optic nerve injury occurred when the acupuncture needle was advanced deep into locations near the optic nerve. Main acupoints used in acupuncture treatment of glaucoma include Tongziliao GB-1, Jingming BL-1 and Chengqi ST-1. It is crucial to have a good understanding of ocular anatomy to avoid potentially blinding complications.

1. Introduction

Acupuncture is a system of complementary medicine in which fine needles are inserted in the skin at specific points to treat various conditions. It is a key component of traditional Chinese medicine, but it is now also gaining popularity and acceptance in Western countries. Glaucoma is a chronic, progressive optic neuropathy with characteristic patterns of optic nerve damage and visual field loss. Although research and inroads have been made in the treatment of

glaucoma, lowering of intraocular pressure remains the mainstay of treatment currently. Acupuncture has also been used in the treatment of glaucoma. However, it is also known to cause various ocular complications. We would like to report a case of traumatic optic neuropathy and self-sealed globe perforation following acupuncture.

This is an open access journal, and articles are distributed under the terms of the Creative Commons Attribution-NonCommercial-ShareAlike 4.0 License, which allows others to remix, tweak, and build upon the work non-commercially, as long as appropriate credit is given and the new creations are licensed under the identical terms.

For reprints contact: reprints@medknow.com

©2018 Journal of Acute Disease Produced by Wolters Kluwer- Medknow

How to cite this article: Lee WY, Teh WM, Ramli NM, Saad AM. Traumatic optic neuropathy secondary to acupuncture treatment for glaucoma: A case report. J Acute Dis 2018; 7(3): 134-136.

✉ First and corresponding author: Wen Yee Lee, Department of Ophthalmology, University of Malaya, Jalan Universiti, 50603 Kuala Lumpur, Wilayah Persekutuan Kuala Lumpur.
Tel: (+ 60)16-4528689
E-mail: leewenyee87@gmail.com

2. Case report

A 63-year-old Chinese gentleman with bilateral advanced primary open angle glaucoma was on long-term follow-up since 2012, and had left eye trabeculectomy done in August 2016. He presented with sudden loss of vision in the right eye after three sessions of acupuncture therapy for consecutive days. During each session, he claimed that the needles were inserted through the lateral canthal region of both eyes. The needles were advanced until he felt a pricking sensation. On the second day of therapy, he developed acute blurred vision in his right eye. However, he was told that this commonly occurred during acupuncture, and was reassured to continue the session. He visited the hospital three days after the third session of acupuncture as his symptoms remained.

On examination, the right eye vision dropped from 6/6 to 2/60. Clinically, there was possible penetration of the globe as suggested by presence of localized subconjunctival hemorrhage over the superotemporal part of the right eye. The cornea was clear and the anterior chamber was deep. There was no hyphema in the anterior chamber and intraocular pressure was 16 mmHg. Traumatic optic neuropathy was suspected based on the findings of marked relative afferent pupillary defect and localized hemorrhage over the right optic disc (Figure 1). There were no signs of infection noted. There were no retinal breaks seen during fundus examination.

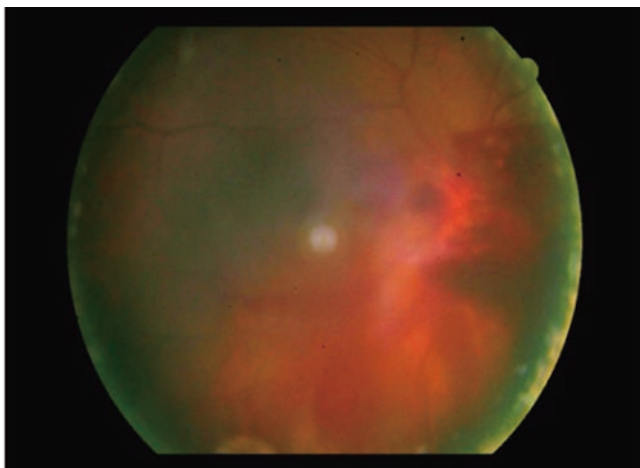


Figure 1. Fundus photo of right eye after acupuncture treatment for glaucoma shows localized hemorrhage over the optic disc.

As the eyeball integrity appeared intact, no surgical intervention was planned. He was also not given any systemic steroids for the possible traumatic optic neuropathy due to the late presentation. He was followed up weekly for the initial two weeks, and there was resolution of the hemorrhage at the optic disc and vitreous at the end of week 2 (Figure 2). Unfortunately, his right eye vision did not improve despite resolution of the hemorrhage.

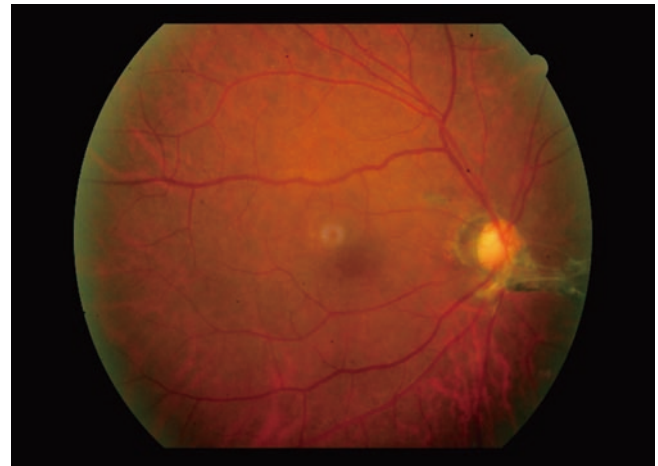


Figure 2. Fundus photo of right eye after vitreous hemorrhage resolved demonstrating fibrovascular membrane on the optic disc.

For the treatment of glaucoma, several acupoints have been identified. Among them are (Figure 3): Acupoint Tongziliao GB-1-lateral to the lateral canthus; Acupoint Jingming BL-1-above the medial canthus; Acupoint Chengqi ST-1-inferior border of the orbit.

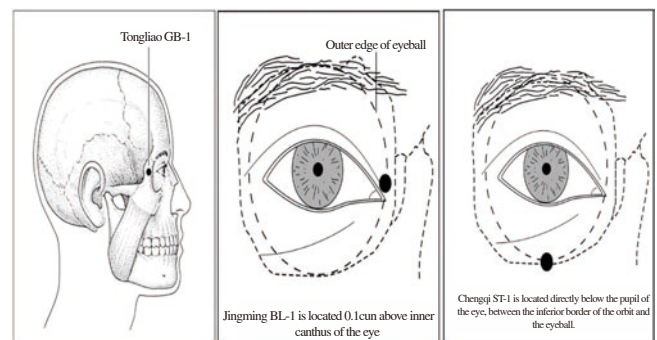


Figure 3. The common acupoints used in glaucoma.

3. Discussion

Acupuncture features prominently in traditional Chinese medicine. Its application dates as far back as the 6th century BC, when the medical profession in China at that time had already included the practice of acupuncture[1]. Acupuncture is now gaining popularity and also acceptance in many countries, including the West. Because of its widespread use, it is important to establish the safety and efficacy of the treatment.

There have been various types of acupuncture-related adverse events identified in the literature. Serious systemic adverse events such as pneumothorax, cardiac tamponade, spinal cord injury and viral hepatitis have been reported[2-5].

Application of acupuncture in eye conditions is also well-established. Some of the symptoms and conditions treated using acupuncture include squint, cataract, optic neuritis, optic atrophy,

myopia, glaucoma, redness of the eyes, watering of the eyes, itchy eyes, swollen and painful eyes, and eyelid spasm[6].

During the procedure, acupuncture needles are advanced deep into the acupoint to achieve an ache radiating to behind of the eye as describe in the Chinese literature[6]. All these points are anatomically predisposed to optic nerve injury and globe perforation due to the proximity of the structures. Other reported adverse events include traumatic cataract, oculomotor nerve injury, endophthalmitis and retinal puncture[7-8].

Our patient sought treatment for his glaucoma at an acupuncture center. From his description, the likely acupoint used in his treatment was acupoint Tongziliao GB-1. The needle was advanced from the area of lateral canthus of the eye and directed medially. The direction of this needle entry poses a very high risk of optic nerve injury. The pain felt by this patient during the acupuncture treatment likely arose from the penetration into the sclera, while the acute loss of vision was due to vitreous hemorrhage and traumatic optic nerve injury.

Fortunately for the patient, he did not develop any signs of infection as the globe perforation appeared to be self-sealing. The vitreous hemorrhage resolved spontaneously, revealing an area of retinal scar just adjacent to optic nerve.

In one of the cases reported in the literature, patient had to undergo vitrectomy surgery with endolaser and intravitreal antibiotics for similar presentation as in our patient[8]. However, comparing the visual outcome of our patient, his vision remained poor because of the optic nerve injury.

To be concluded that this case report wishes to highlight the dangers of acupuncture treatment for the eye. It is important for the acupuncturist to recognize and differentiate between the pain of imminent globe puncture and/or nerve injury from desired therapeutic effect of the procedure. However, this is a very subjective assessment tool as pain threshold varies amongst patients.

Conflict of interest statement

The authors report no conflict of interest.

References

- [1] Ma KW. Acupuncture: its place in the history of Chinese medicine. *Acupunct Med* 2000; **18**(2): 88-99.
- [2] Norheim AJ. Adverse effects of acupuncture: a study of the literature for the years 1981–1994. *J Altern Complement Med* 1996; **2**(2): 291-297.
- [3] Peuker ET, White A, Ernst E, Pera F, Filler TJ. Traumatic complications of acupuncture. Therapists need to know human anatomy. *Arch Fam Med* 1999; **8**(6): 553-558.
- [4] Yamashita H, Tsukayama H, White AR, Tanno Y, Sugishita C, Ernst E. Systematic review of adverse events following acupuncture: the Japanese literature. *Complement Ther Med* 2001; **9**(2): 98-104.
- [5] Ernst E, Sherman KJ. Is acupuncture a risk factor for hepatitis? Systematic review of epidemiological studies. *J Gastroenterol Hepatol* 2003; **18**(11): 1231-1236.
- [6] Blackwell R, Macpherson H. Bright eyes-the treatment of eye diseases by acupuncture. *J Chinese Med* 1992; **39**: 1-8.
- [7] Zhang J, Shang H, Gao X, Ernst E. Acupuncture-related adverse events: a systematic review of the Chinese literature. *Bull World Health Organ* 2010; **88**(12): 915-921C.
- [8] Chung HY, Lee SC, Choi JY, Sohn JH, Hwang DJ. A Case of ocular perforation by an acupuncture needle directly through the bulbar conjunctiva. *J Korean Ophthalmol Society* 2016; **57**(1): 130-133.