

*Case Report***Actinomyces of Gall Bladder: A Rare, Unique and Interesting Case**

Evith Pereira<sup>1</sup>, Hoogar M.B.<sup>2</sup>, Atul Jain<sup>3</sup>, Reeta Dhar<sup>4</sup>, Kalyani Mahore<sup>1</sup>, Puja Iyengar<sup>5</sup>, Shonit Agarwal<sup>5</sup>,  
Priyanka Lad<sup>6</sup>, Mithila Bahuleyan<sup>6</sup>

<sup>1</sup>2<sup>nd</sup> year Resident, <sup>2</sup>Associate Professor, <sup>3</sup>Assistant Professor, <sup>4</sup>HOD & Professor, <sup>5</sup>3<sup>rd</sup> year Resident,  
<sup>6</sup>1<sup>st</sup> year Resident;

Department of Pathology, MGM Medical College, Navi Mumbai.

Corresponding Author: Evith Pereira

Received: 22/10/2016

Revised: 25/10/2016

Accepted: 26/10/2016

**ABSTRACT**

**Introduction:** Actinomyces of gall bladder is highly infrequent and there are few cases found published in literature. The present case is rare and unique one of such few cases which was diagnosed incidentally in a clinically suspected case of carcinoma of bladder.

**Presentation of the case:** The case being discussed here occurred a male, 68 years, who presented with abdominal discomfort. On examination, he was found to be having cholelithiasis on ultrasonography. An open cholecystectomy was carried out. Histopathology laboratory received the specimen of gall bladder which was grayish brown in colour with diffuse thickening of the gall bladder wall, which contained multiple brownish biliary calculi. Histological examination of the gall bladder revealed diffuse loss of mucosal epithelium with the gall bladder wall showing focal area of haemorrhage and encrusted biliary material. At places, colonies of radiating filamentous structure reminiscent of colonies of Actinomyces spp were noted. The sections were further stained with relevant stains for filamentous bacteria such as Periodic Acid Schiff (PAS) stain which confirmed the colonies of Actinomyces spp.

**Conclusion:** The case being presented here is rare and unique case of Actinomyces of gall bladder in that only 50 confirmed cases are found to be published in literature till date. The case in context is very interesting and unique as it is the only second documented case in India apart from another case published in 1997.

**Key words:** Actinomyces, Gall bladder, Rare case, India

**INTRODUCTION**

Actinomyces is an atypical chronic suppurative disease affecting cervical, thoracic, abdomino-pelvic organs in normal as well as immunocompromised individuals. Actinomyces is caused by a gram positive, anaerobic filamentous bacterium, a normal commensal in oral and genito-urinary regions of the body. Actinomyces affects various topographic regions of the body, which occurs most frequently in the cervico-facial region

(50%–65%), abdominal cavity (20%), and thoracic region (15%). The mode of infection is through oral route or when the normal mucosal barrier is breached due to infection or local injury.<sup>[1]</sup> The overall incidence of actinomyces all over the world is decreasing, albeit the abdomino-pelvic actinomyces, showing a modest increasing incidence, which is possibly associated with increase in the frequency of abdominal surgeries such as in cases of appendectomies, intestinal perforation and

blunt abdominal trauma causing internal injuries. Additionally, the increased use of intra-uterine contraceptive devices (IUD), which when used for long time are supposed to be having an increased risk factor in the aetiology of actinomycosis. [2] After infection, *Actinomyces* spp tends to invade the planes of the body tissue evoking a severe acute inflammatory reaction leading to focal suppurative inflammation and abscess formation leading sometimes to sinus formation. Occasional it may evoke a granulomatous inflammatory reaction. When the abscess thus forms drains through a persistent sinus, the purulent exudates draining through such sinuses may contain tiny yellowish granules known as 'sulphur' granules mimicking particles of sulphur. Different species of *Actinomyces* are implicated in the infection, [3] the most common species in India being *Actinomyces israelii*. Other species including *A. gerencseriae*, *A. naeslundii*, *A. viscosus*, *A. odontolyticus*, and *A. meyer* may rarely cause the disease.

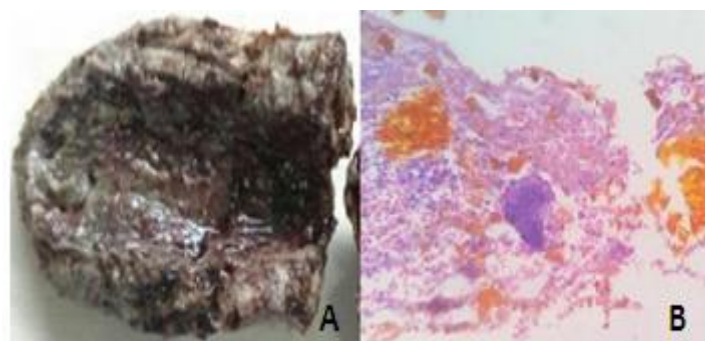
### CASE REPORT

A 68-year-old male presented with abdominal discomfort and dull aching pain in the right hypochondriac region. The patient was known to be a diabetic with fluctuating glycemic control with no history of previous abdominal surgery. Ultrasonography and CE-CT of the abdomen showed that the gall bladder was thickened and edematous with presence of gall stones and sludge. Laboratory studies revealed Normocytic anemia with

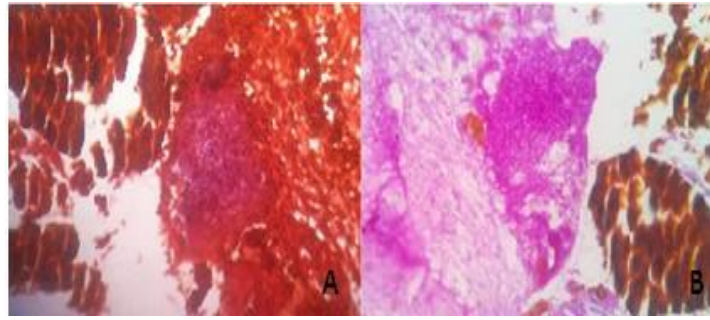
leukocytosis, normal serum electrolytes and liver function tests with markedly raised levels of serum amylase and lipase. Human immunodeficiency virus and hepatitis B serology were negative. The patient was managed conservatively for the raised indices and after 6 weeks an open cholecystectomy was carried out.

### HISTOPATHOLOGICAL EXAMINATION

Histopathology section of the central laboratory of the tertiary care hospital received an intact gall bladder with a firm metallic staple placed in the neck region. The gall bladder was grayish brown and measured 6x4x2.5 cm in size. On cut section, the gall bladder wall was brownish in colour and was diffusely thickened which, all over, measured 1 cm in thickness. The mucosal surface was diffusely denuded with the entire gall bladder wall having firm consistency (Figure 1A). The gall bladder contained multiple brownish calculi. Microscopic examination revealed extensive denudation of mucosal epithelium with the gall bladder wall showing focal area of haemorrhage and encrusted biliary material. At places, round to ovoid colonies of radiating filamentous structures reminiscent of colonies of *Actinomyces* spp were noted (Figure 1B). The sections were further stained with relevant stains for filamentous bacteria such as Periodic Acid Schiff (PAS) and Gram stains which confirmed the morphological features of colonies of *Actinomyces* spp (Figures 2A and 2B).



**FIGURE 1.** A. Gall bladder: Cut section showing thickened gall bladder wall with diffusely ulcerated Mucosa; B. Photomicrograph showing diffusely denuded mucosa with colonies of *Actinomyces* spp. (H and E, 10x).



**FIGURE 2.** A. Photomicrograph showing colonies of *Actinomyces* spp. (Gram staining, 40X); B. Photomicrograph of colonies of *Actinomyces* spp. Stained with Periodic Acid Schiff (PAS) stain, 40X.

## DISCUSSION

Actinomycosis is a chronic debilitating infection endemic all over the world, particularly so in developing countries with poor socio-economic conditions with no reported predisposition for age, race and season. It is an infection caused by anaerobic gram positive and filamentous Actinomycoses species, which belong to the natural flora of the oral cavity, gastro-intestinal tract and urogenital tract. Till date a minimum of 30 pathogenic species have been recognized, of which the most common species being accounted for Actinomycosis across the world are *A.israelii*, *A.naeslundii*, *A.odontolyticus*, *A.viscosus*, *A. meyeri* and *A.genencseriae*.<sup>[3]</sup> The destruction of various tissue barriers by injury, such as in cases of endoscopic manipulation, surgical operations, immunocompromised states, and chronic inflammatory disease processes, is recognized as predisposing factors for penetration of Actinomyces bacteria. Several forms of immunosuppressive conditions such as neoplastic and non-neoplastic conditions including leukemia, lymphoma, renal insufficiency, renal transplant, and diabetes, have been demonstrated to facilitate this process.<sup>[2, 4]</sup> In a study by Lee et al of 14 patients with actinomycosis of gastrointestinal tract it was proposed that the most common CT features for diagnosing abdomino-pelvic actinomycosis were thickened gall bowel wall and regional pelvic or peritoneal mass with extensive infiltration.<sup>[1]</sup> Similarly, in another similar study by Kuo et al., eight

in ten cases of abdomino-pelvic actinomycosis underwent radical surgery because the disease mimicked malignancy.<sup>[1]</sup> Gallbladder actinomycosis is a rare disease that can masquerade as a chronic cholecystitis but more frequently manifests as an acute abdominal disease. Because of the tendency to form masses and invade other organs, neoplastic lesions particularly carcinoma of gall bladder and actinomycosis are almost always confused, the latter being diagnosed only after histopathologic examination.<sup>[5]</sup> Histological diagnosis of actinomycosis is based on the demonstration of presence of dense aggregates of filamentous Actinomyces (“Sulphur granules”) resembling Actinomyces colonies with associated acute suppurative inflammation. However, such “sulphur granules” may occasionally be found in other infectious conditions such as Nocardiasis, *Streptomyces madurae*, and rarely in *Staphylococcus aureus*. Despite, “sulphur granules” being seen on gross examination in only 50% of patients with Actinomycosis, the micro-organism of tangled gram-positive filamentous bacteria are pathognomonic for diagnosing Actinomycosis. Actinomyces are slow-growing micro-organisms that have to be cultured in appropriate laboratory conditions on selective agar medium at 37°C anaerobically for up to three weeks. The various steps in diagnosis of Actinomycosis depend on cumulative complementary factors of clinical suspicion, histological diagnosis with the ultimate step being confirmation by

laboratory culture and isolation of actinomyces spp. [1]

## CONCLUSION

Actinomycosis of the gall bladder is extremely rare being the second of its kind in India<sup>[6]</sup> and its diagnosis is challenging in clinical practice, inasmuch as it is known to be present in the garb of much more severely morbid conditions such as neoplastic lesions. The case being presented here is rare and unique condition of gall bladder which forms one of the rare cases published in literature across the world. Secondly, the case is unique in the present context since it is diagnosed in the backdrop of varied proposed differential diagnoses such as chronic lithiasis and cancer of the gall bladder, which makes it surprisingly interesting, the very outcome being pleasant clinical reprieve in the face of imminence of a possible expectant diagnosis of cancer of the gall bladder.

**Declaration:** This publication does not involve any conflict of interest.

## REFERENCES

1. Cheng Chin-Yuan et.al. *Actinomycosis of the Gallbladder: A Case Report*, vol 2, Article ID 201400324 ed. : American Journal of Cancer Case Reports; 2014.
2. Teresa Pusiol et al.. *Abdominal-Pelvic Actinomycosis Mimicking Malignant Neoplasm*, vol 2011,Article ID 747059 ed. : Infectious Diseases in Obstetrics and Gynecology; 2011.
3. Francisco Acevedo et al.. *Actinomycosis: A great pretender. Case reports of unusual presentations and a review of the literature*, Volume 12, Issue 4, July 2008 ed. : International Society for Infectious Diseases; 2008.
4. Hefny et al.. *Actinomycosis of the Gallbladder: Case Report and Review of the Literature*, Volume 28, Issue 3, July 2005 ed. Asian Journal of Surgery ; 2005.
5. Lee et al.. *Actinomycosis of the Gallbladder Mimicking Carcinoma: a Case Report with US and CT Findings*, 2007 Mar-Apr; 8(2) ed. : Korean Journal Of Radiology; 2007.
6. Arora B et al.. *Actinomycotic cholecystitis*, Apr;16(2) ed. : Indian J Gastroenterol; 1997.

How to cite this article: Evith Pereira, Hoogar M.B., Jain A et al. Actinomycosis of gall bladder: a rare, unique and interesting case. Int J Res Rev. 2016; 3(10):62-65.

\*\*\*\*\*