

Long proximal femoral nail versus short proximal femoral nail in treatment of unstable intertrochanteric fractures- a prospective randomized comparative study

Mahesh Kumar NB^{1,*}, Ullas Mahesh², Santosh Kumar³

^{1,2,3}Assistant Professor, Dept. of Orthopaedics, Rajarajeswari Medical College & Hospital, Bengaluru, Karnataka

***Corresponding Author:**

Email: drmaheshortho@gmail.com, ullasrock@gmail.com

Abstract

Background & objectives: In elderly, the Intertrochanteric fractures are one of the most common fractures of the hip out of which more than 50% are unstable. Internal fixation is optimal for it fractures which are very challenging. Evolution of intramedullary devices is a result of dissatisfaction with the extra medullary devices in it unstable fractures our main aim was to compare the effectiveness & drawbacks of short Pfn vs long Pfn in the management of It fractures

Materials and methods: This study was randomised, time bound, hospital based study conducted in a tertiary hospital, between Sept 2013- Sept 2015. The study included 40cases of unstable it fractures of Group A were operated with short PFN which fitted into the inclusion criteria & group B patients were operated with long Pfn, intraoperative parameters post-operative data & events were noted. Radiological assessment for progression & time of union, fracture alignment & implant related complications were analysed. All patients were accessed in immediate post op, 12 days, 1 month, 3months, 6months & at 1 year with Harris hip score. After data collection, data entry was done in excel worksheet. Data analysis was done with help of SPSS software version 23.

Result: In our study the most common case of IT fracture was a trauma following a fall seen in 57 cases of the 80 cases studied accounting for 71% of the cause of injury, the mean intraoperative blood loss in the long Pfn group was 344.5 ml & the short PFN group was 133.5 ml, P value equals 0.0001 this difference is considered statistically significant. The quality of reduction in the short PFN group was significantly lesser than the long PFN group. The post operative complication in the short PFN group was significantly lesser than the long PFN group. The number of cases with limb shortening were more in the short PFN group than the patients in whom long PFN was used. The mean time of union in the short PFN group was 10.05 weeks and the long PFN group was 21.10 weeks. The two- tailed P value equals 0.0217 by conventional criteria, this difference is considered to be statistically significant. The mean lower extremity functionally scale. In the short PFN group was 63.95 & the long PFN group was 67.50. The two tailed P value equals 0.0114 statistically significant.

Interpretation & conclusion: Short Proximal Femoral Nail provides good fixation for unstable IT fractures, if proper preoperative planning , good reduction & surgical technique are followed , leading to high rate of bone union & soft tissue damage especially for Asian patients with relatively small femora.

Keywords: Bone nails; Fracture fixation, Intramedullary; Hip fractures; Unstable it fractures; Short PFN, Harry's hip score

Introduction

5% of all hip fractures are intertrochanteric fractures and 35–40% of these fractures are unstable three or four part fractures and associated with high rates of morbidity and mortality.^(1,2) Due to difficulty in obtaining anatomical reduction, management of the unstable intertrochanteric fractures in elderly patients is challenging and controversial.^(3,4) Osteoporosis and instability are the most important factors preventing early weight bearing and leading to unsatisfactory results in these cases.^(3,5,6)

In elderly, the IT fracture is one of the most common fractures of the hip. The rise In the IT fracture is because of the increase in number of elderly population with osteoporosis. These fractures are three to four times more common in women. The low energy trauma like a simple fall is usually the cause. By the year 2040 the incidence is estimate to be doubled. In India the figures maybe much more.

The current practises of treatment of IT fractures are by DH for a stable IT fracture or a pfn for an unstable. It fracture. However with long Pfn there are advantages of increased stability because of the advantage of splinting

the whole length of femur. There are times when there is mismatch of curvature of pfn & the femur.

Few disadvantages of long pfn include increased operative time, reaming extending more distally, due to unavailability of distal jig, distal locking becomes difficult etc. The purpose of this study is to study and compare the effectiveness and the disadvantages of intramedullary devices, i.e. short vs long pfn in the management of unstable IT fractures.

Materials & Methods

On the approval from ethical clearance committee, this study was started. This is a Randomized study done in a tertiary hospital, Bangalore between the time period of September 2013 to September 2015. This study included 40 cases of unstable IT fractures of Boyd & Griffin classification- Type III & Type IV fracture patterns in each group. i.e. Group A & Group B. Group A patients were operated with short Pfn which fitted into the inclusion criteria & group B patients were operated with long pfn. All patients were informed about the study in all aspects and an informed consent was taken from the participating patients.

Inclusion criteria

- All unstable intertrochanteric fractures based on AO system of classification
- All patients above 50 years of age.

Exclusion criteria

- All patients with any pathological cause for the fracture
- All young patients
- All patients with multiple limb fractures
- Patients with any contraindications for operative management

Follow up protocol: Pts were called for follow up every month, on follow up following aspects were noted: Deformity, Complaints of pain if any, Range of Hip & knee movements, Shortening, Whether the pt resumes his occupation to pre injury state, ability to sit cross legged and squat, walking ability with or without support.

Method of Randomization: double blind method. Association of various qualitative parameters were done with help of Pearsons Chi square test.

Result

This study is a randomised, time bound, hospital based study conducted in a Tertiary Hospital, between the period of September 2013 to September 2015. This study included 40 cases of unstable IT fractures of the Boyd & Griffin classification type III & type IV fracture patterns in each operated with long Pfn after an ethical clearance was taken from the committees ethical clearance committee and an informed consent of the participating patients were obtained.

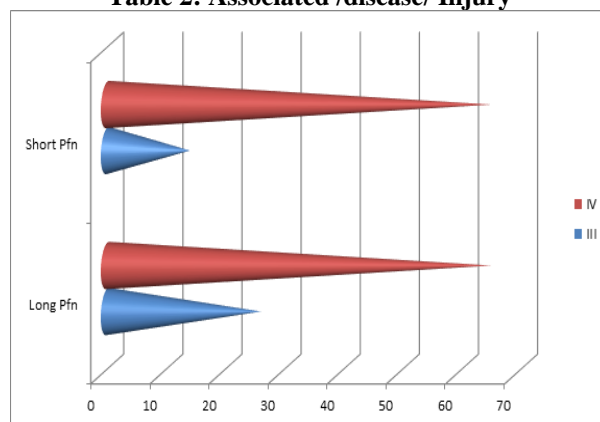
In our study: Most common cause of IT fracture was a trauma following a fall seen in 57/80 cases= 71% of the cause of injury. Only type 3- 19 cases(24%) & type 4- 16 cases(76%) were included. Singh's index- 6 cases -14% had type III, 25 cases 43% had type IV, 9 cases -23% had type V. 45% had no morbidities, 17% had > one associated co morbidity, most common being Hypertension 14%, next Diabetes mellitus 10%. Mean I.weight in Long Pfn group-57.68kgs & short Pfn group 65.18kgs respectively. The mean pre op Haemoglobin was 12.557 in short Pfn & 11.71 in long Pfn & no statistically difference in p value equals 0.0683. 36 cases in long Pfn underwent closed reduction & 38 in short pfn. Additional support- 22.5% in long Pfn & 17% in short Pfn group needed K wires. Mean angle in long pfn -133.75 degrees, short Pfn 133.65 degrees. Mean nail diameter long Pfn -10.44 mm, short pfn -10.95mm. Mean anti rotation screw width in long Pfn -78.50mm & short Pfn- 81.10mm. Two tailed P value=0.1200 not statistically significant. Compression screw width in long Pfn -96.75mm & short Pfn group -94.38mm. Two tailed p value=0.1289, not statistically significant. Mean duration of surgery in long Pfn-108.88 minutes, & short Pfn-81.63minutes. The two tailed P value =0.0001 this difference is considered to be extremely statistically significant. The mean length of incision in long Pfn -

12.08cms, short pfn10.03cms. Two tailed p value 0.0001, this difference is considered to be extremely statistically significant. Mean C-arm time in long pfn - 41.95minutes & short pfn -32.48minutes, this difference is considered to be extremely statistically significant. Mean intra op blood loss in long Pfn -344.5ml & short Pfn -133.5 ml, this difference is considered to be extremely statistically significant. Quality of reduction in short Pfn was significantly better 29 of 40 had good reduction as compared to 25 of 40cases in long Pfn. The intraoperative complication in the short Pfn group was significantly lesser than long Pfn. The post op complication in short Pfn was significantly lesser than long Pfn group. The no of cases with limb shortening were more in the Short Pfn group than the patients in whom long Pfn was used. The mean time of union in the short Pfn group was 10.05 weeks & long Pfn group was 21.10 weeks. Two tailed p value 0.0217, this difference is considered to be statistically significant. The mean lower extremity functionality scale in short Pfn group was 63.95 & the long Pfn group was 67.50. The two tailed P value equals 0.0114 statistically significant.

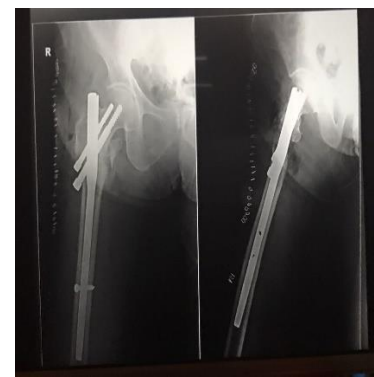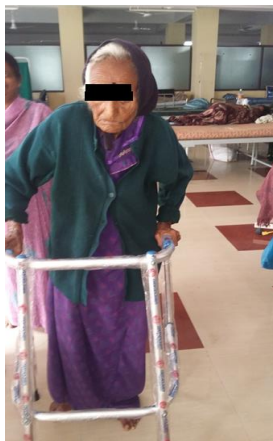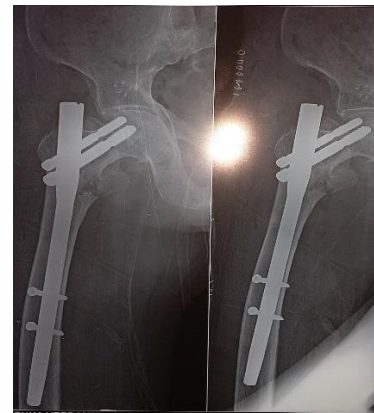
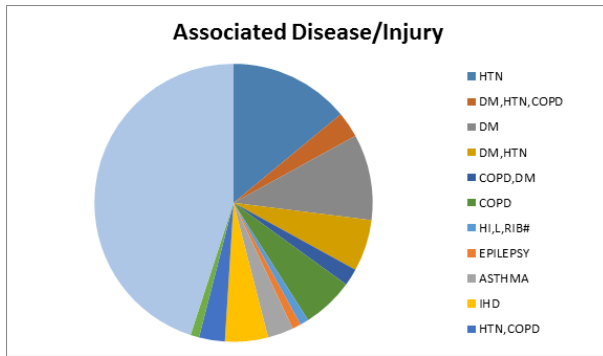
***these are observations and not results**

Table 1: Boyd & Griffin Type of Fracture

	Long Pfn		Short Pfn	
	Frequency	Per cent	Frequency	Per cent
III	14	35	5	12.5
IV	26	65	35	87.5
Total	40	100	40	100

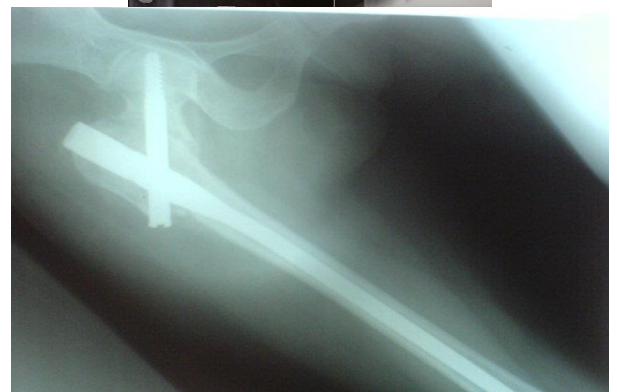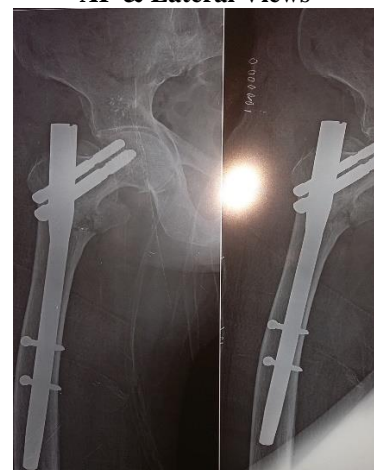
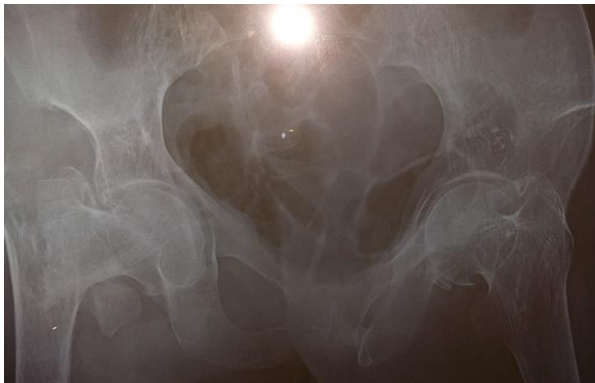Table 2: Associated /disease/ Injury

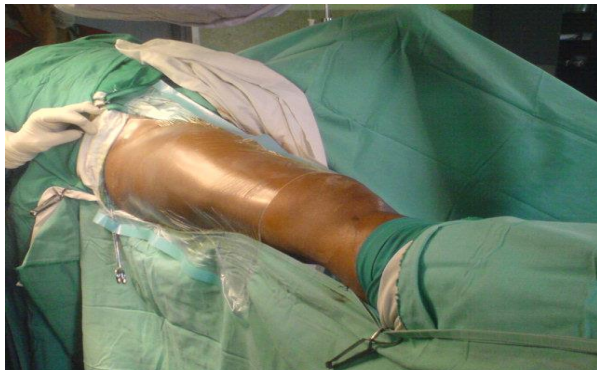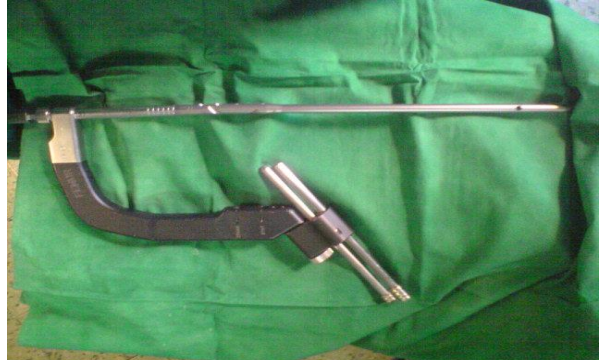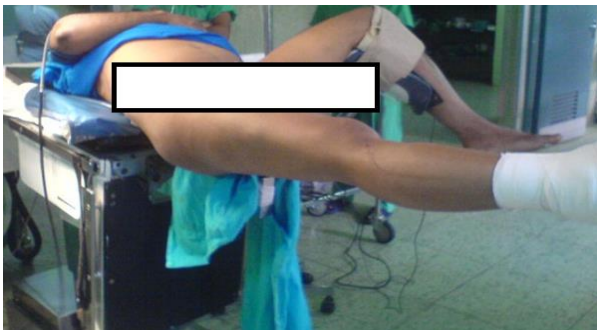
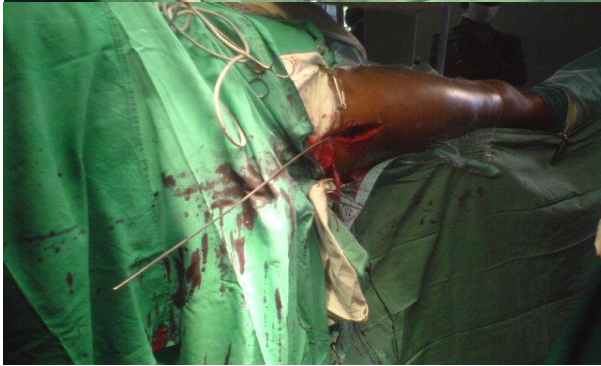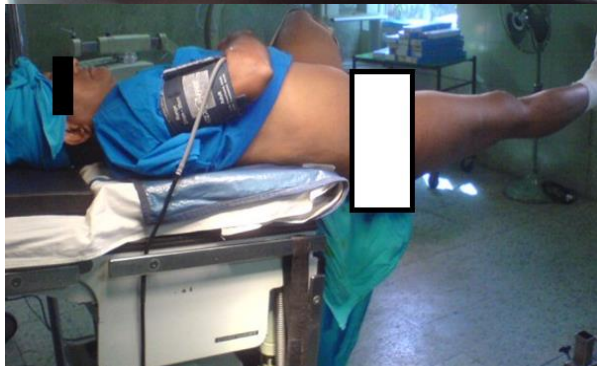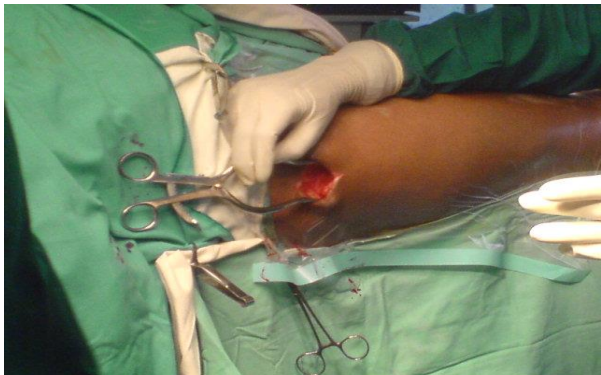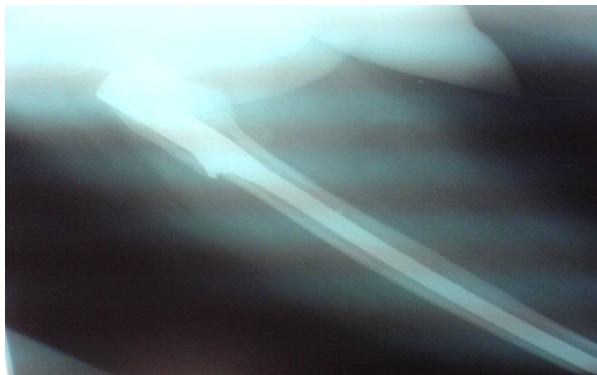In our study 45% had no morbidities, 17% had more than one associated morbidity.

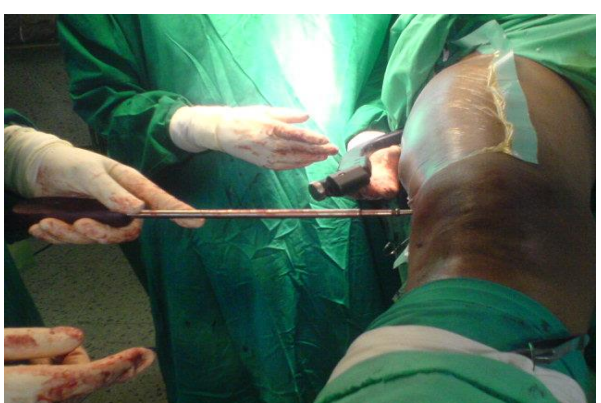
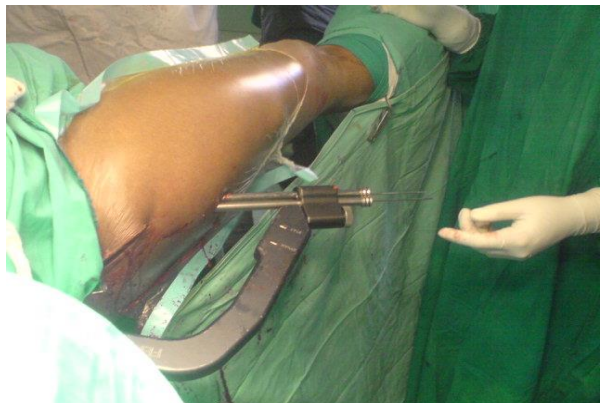
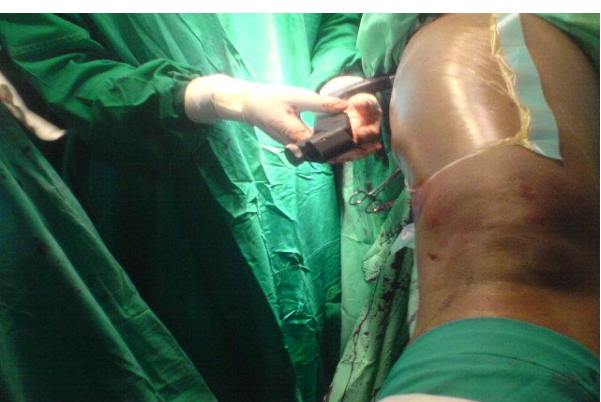
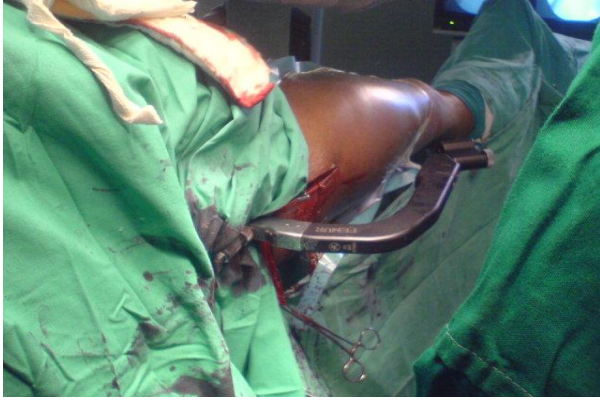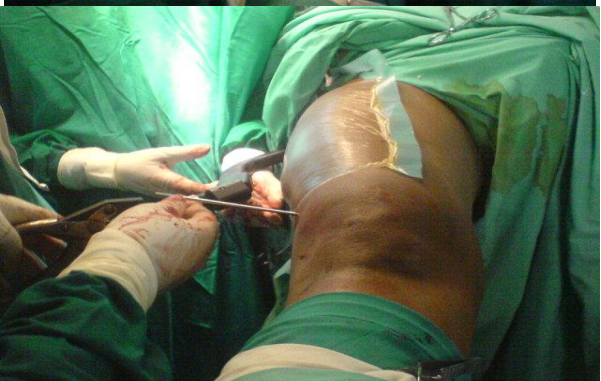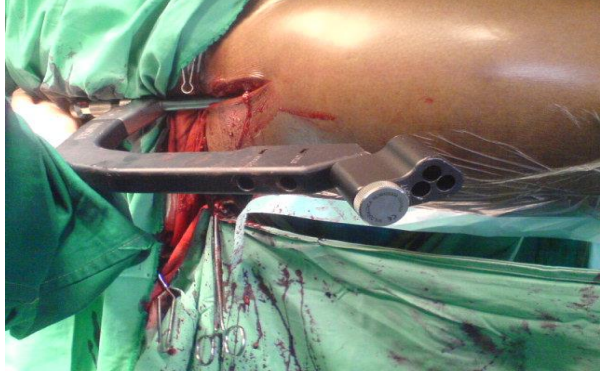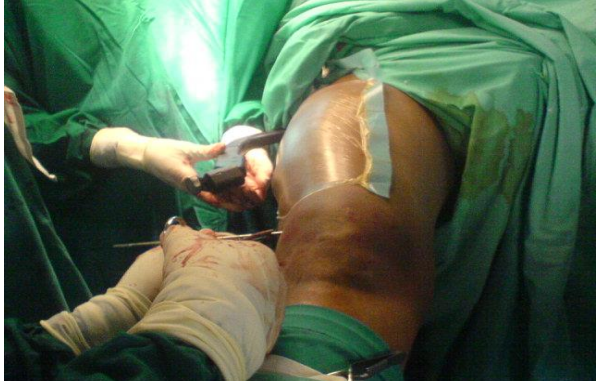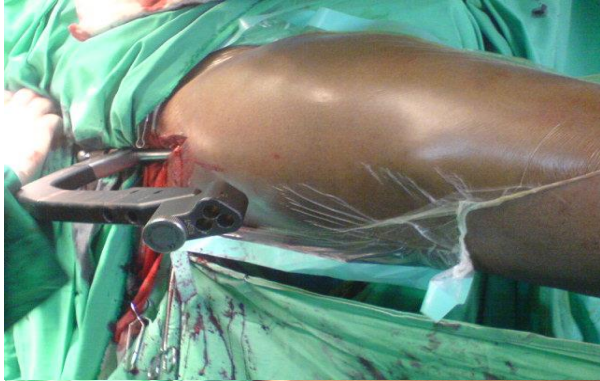AP & Lateral Views

2ND POST OP DAY

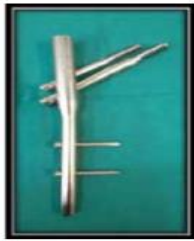









INSTRUMENTS AND IMPLANT



SHORT PFN



SHORT PFN WITH JIG & SLEEVES



***pictures should not be copied from thesis, but original pictures, not have page number etc.**

Discussion

Treatment of Proximal femoral fractures is challenging.⁽¹⁹⁾ The treatment goal is to achieve anatomic reduction with a stable fracture fixation to allow early functional rehabilitation. Over the past decades, intertrochanteric and subtrochanteric fractures were predominantly treated by dynamic hip screw.⁽²⁰⁾ However, the complication rate for unstable fractures treated with a dynamic hip screw or dynamic condylar screw plate has shown to be as high as 3% to 26%.⁽²¹⁾ Primary or secondary varus collapse and hardware failure by “cut-out” of the femoral head screw are the most frequently reported complications.⁽²²⁾ Unstable proximal femoral fractures can be treated by dynamic hip screw or dynamic condylar screw plates but they cannot prevent secondary limb shortening after weight bearing due to lateralization of the neck/head fragment from gliding along the screw or because of distal fragment medialization.⁽²³⁾ Role of intramedullary devices like proximal femoral nail (PFN), gamma nail (GN) and Proximal femoral nail anti-rotation (PFNA) in the treatment of these unstable intertrochanteric fractures have some theoretical advantage over the DHS. Various authors have shown high complication rate with the use of these implants. Failure rate of gamma nail for the treatment of these fractures ranges from 12.7% to 15%.^(16,17) Fogagnolo et al., showed a complication rate of about 23.4% with the use of PFN for the treatment of these unstable fractures.⁽²⁴⁾ In another study done by Uzun et al.,⁽²⁵⁾ non-union was seen in 5.7%, secondary varus collapse in 25.7%, cut out of proximal screws in 5.7% and reoperation in 14.3% cases. As for PFNA, Takigami et al.,⁽²⁶⁾ showed complications in 14% of the cases and 4% required reoperation. In another study by Yaozeng et al., intraoperative complications were seen in 20% cases and 9.1% cases had femoral shaft fracture.⁽²⁷⁾

The study included 40 cases of unstable intertrochanteric fractures of the Boyd & Griffin classification – type III and type IV fracture patterns in each operated with the short PFN which fitted into the inclusion criteria and Group B patients were operated with long PFN after an ethical clearance was taken from the committee’s ethical clearance committee and an informed consent of the participating patients was obtained.

Operative treatment in the form of internal fixation permits early rehabilitation and offers the best chance of functional recovery, and hence has become the treatment of choice for virtually all fractures in the trochanteric region. Amongst the various types of implants available i.e. fixed nail plate devices, sliding nail/screw plate and intramedullary devices, the compression hip screw is most commonly used(still remains the gold standard) but recently techniques of closed intramedullary nailing have gained popularity. Now PFN has evolved into use more largely. It comes in longer and shorter versions, practically no comparison in the use of long and short

PFN has been made so far, in any evidence based studies. So it was lead to a dilemma whether to use long or short PFN in the treatment of unstable intertrochanteric fractures. In this study an attempt was made to survey, evaluate, document and quantify our success in the management of such individuals by using long and short Proximal femoral nail.

Conclusion

In our results it was evident that the use of short Pfn has advantages over long Pfn in terms of the mean duration of surgery, C-arm time, length of incision, intraoperative blood loss, intraoperative complication, postoperative complication, mean time of union being lesser & better scores in terms of the quality of reduction & lower extremity functionality scale.

The short pfn with smaller distal shaft diameter may prevent femoral shaft fractures. It also acts as a buttress to prevent medialisation of the shaft & provides more effective load transfer than does a sliding hip screw. It is superior implant for stable & unstable. It fractures in terms of operating time, surgical exposure, blood loss & complication rates.

The only disadvantage of the short Pfn was that the no of cases with limb shortening were more in the short Pfn group than the patients in whom long Pfn was used and stress risers at the tip of the nail which leads to anterior thigh pain.

Complication

1 case had a screw cut out through the femoral head in short pfn, 1 case in Long Pfn, only dynamic locking could be done, due to mismatch of the implants. 1 case of short Pfn had a periprosthetic fracture after two months and was re treated.

Reference

- Gadegone Wasudeo M, Salphale Yogesh S. Short proximal femoral nail fixation for trochanteric fractures, *Journal of Orthopaedic Surgery* 2010;18(1):39-44.
- Gebauer M, Stark O, Vettorazzi E, Grifka J, Puschel K, Amling M et al. DXA and pQCT predict petrochanteric and not femoral neck fracture load in a human side-impact fracture model. *Journal of orthopaedic research: official publication of the Orthop Res Soc.* 2014;32(1):31-38. doi:10.1002/jor.22478.
- Bazylewicz DB, Egol KA, Koval KJ. Cortical encroachment after cephalomedullary nailing of the proximal femur: evaluation of a more anatomic radius of curvature. *J Orthop Trauma.* 2013 Jun;27(6):303-7. doi: 10.1097/BOT.0b013e318283f24f.
- Kleweno C, Morgan J, Redshaw J, Harris M, Rodriguez E, Zurakowski D, Vrahas M, Appleton P. Short versus long cephalomedullary nails for the treatment of intertrochanteric hip fractures in patients older than 65 years. *J Orthop Trauma.* 2014;28:391-7. [PubMed]
- Y.Z. Zhang Hip fractures in the elderly—the chance and challenge for Chinese orthopedic surgeons *Chin J Trauma,* 30 (2014), pp. 193–195.
- Hou Z, Bowen TR, Irgit KS, Matzko ME, Andreychik CM, Horwitz DS, Smith WR. Treatment of petrochanteric fractures (OTA 31-A1 and A2): long versus short cephalomedullary nailing. *J Orthop Trauma.* 2013 Jun;27(6):318-24. doi: 10.1097/BOT.0b013e31826fc11f.
- C. Kokoroghiannis, I. Aktseles, A. Deligeorgis, et al. Evolving concepts of stability and intramedullary fixation of intertrochanteric fractures—a review *Injury,* 43 (2012), pp. 686–693.
- A.J. Bojan, C. Beigel, A. Speitling, et al. 3066 consecutive Gamma Nails. 12 years experience at a single centre. *BMC Musculoskelet Disord,* 11 (2010), p. 133.
- Wirtz C, Abbassi F, Evangelopoulos DS, Kohl S, Siebenrock KA, Krüger A. High failure rate of intertrochanteric fracture osteosynthesis with proximal femoral locking compression plate. *Injury.* 2013;44:751–756. [PubMed]
- R. Norris, D. Bhattacharjee, M.J. Parker. Occurrence of secondary fracture around intramedullary nails used for trochanteric hip fractures: a systematic review of 13,568 patients. *Injury,* 43 (2012), pp. 706–711.
- Byrne, D. P., Mulhall, K. J., & Baker, J. F. (2010). Anatomy & biomechanics of the hip. *Open Sports Medicine Journal.* 4(1), 51-57.
- M. Bhandari, E. Schemitsch, A. Jonsson, et al. Gamma nails revisited: gamma nails versus compression hip screws in the management of intertrochanteric fractures of the hip: a meta-analysis. *J Orthop Trauma,* 23 (2009), pp. 460–464.
- Lecerf, G., Fessy, M. H., Philippot, R., Massin, P., Giraud, F., Flecher, X., & Stindel, E. (2009). Femoral offset: anatomical concept, definition, assessment, implications for preoperative templating and hip arthroplasty. *Orthopaedics & Traumatology: Surgery & Research,* 95(3), 210-219.
- Shen L, Zhang Y, Shen Y, Cui Z. Antirotation proximal femoral nail versus dynamic hip screw for intertrochanteric fractures: a meta-analysis of randomized controlled studies. *Orthop Traumatol Surg Res.* 2013;99:377–383. [PubMed]
- Mundi S, Pindiprolu B, Simunovic N, Bhandari M. Similar mortality rates in hip fracture patients over the past 31 years. *Acta Orthop.* 2014;85:54–59. [PMC free article] [PubMed]
- Chen T, Li K, Wang X, Lan H, Zhang J (2010) Revision cause and effect of gamma nail fixation. *Zhongguo Xiu Fu Chong Jian Wai Ke Za Zhi* 24(1):78–81. [PubMed] [Google Scholar]
- Hou Z, Bowen TR, Irgit KS, Matzko ME, Andreychik CM, Horwitz DS, Smith WR. Treatment of petrochanteric fractures (OTA 31-A1 and A2): long versus short cephalomedullary nailing. *J Orthop Trauma.* 2013;27:318–24. [PubMed]
- Boone C, Carlberg KN, Koueiter DM, Baker KC, Sadowski J, Wiater PJ, Nowinski GP, Grant KD. Short versus long intramedullary nails for treatment of intertrochanteric femur fractures (OTA 31-A1 and A2) *J Orthop Trauma.* 2014;28:e96–e100. [PubMed]
- Oblique trochanteric femoral fractures with proximal femoral nail. *International Orthopaedics.* 2011;35(4):595–98. Babhulkar SS.
- Management of trochanteric fractures. *Indian J Orthop.* 2006;40(4):210-18. Yong CK, Tan CN, Penafort R, Singh DA, Varaprasad MV.
- Dynamic Hip Screw Compared to Condylar Blade Plate in the Treatment of Unstable Fragility Intertrochanteric Fractures. *Malaysian Orthopaedic Journal.* 2009;3(1):13-18. Kim WY, Han CH, Park JI, Kim JY.
- Failure of intertrochanteric fracture fixation with a dynamic hip screw in relation to pre-operative fracture stability and osteoporosis. *International Orthopaedics.*

- 2001;25:360–62. Nungu KS, Olerud C, Rehnberg L. Treatment of subtrochanteric fractures with the AO dynamic condylar screw. *Injury*. 1993;24:90-92. Sehat K, Baker RP, Pattison G, Price R, Harries WJ, Chesser TJ.
23. The use of long gamma nail in proximal femoral fractures. *Injury* 2005;36(11):1350-54. Saarenmaa I, Heikkinen T, Ristiniemi J, Hyvonen P, Leppilahti J, Jalovaara P.
 24. Functional comparison of the dynamic hip Screw and gamma locking nail in trochanteric hip fractures: a matched pair study of 268 patients. *Int Orthop*. 2009;33(1):255-60. Fogagnolo F, Kfuri Jr M, Paccola C.
 25. Hip fractures with the short AO-ASIF proximal femoral nail. *Arch Orthop Trauma Surg*. 2004;124:31-37. Uzun M, Erturer E, Ozturk I, Akman S, Seckin F, Ozelik IB.
 26. Long term radiographic complications following treatment of unstable intertrochanteric femoral fractures with proximal femoral nail and effects on functional results.
 27. *Acta Orthop Traumatol turc*. 2009;43(6):457-63. Takigami I, Matsuoto k, Ohara A , Yamanaka K, Naganawa T, Ohashi M.
 28. Treatment of trochanteric fractures with PFNA nails system- report of early results. *Bull NYU Hosp Jt Dis*. 2008;66(40):276-79. Yaozeng X, Dechun G, Huilin Y, Guangming Z, Xianbin W.
 29. Comparative study of trochanteric fracture treated with proximal femoral nail antirotation and third generation of gamma nail. *Injury*. 2010;41(7):986-90. Wieser K, Babst R.