

Parasitic fibroid during Pregnancy: A Diagnostic Dilemma (Rare Case Report)

Neha Varun^{1,*}, Arifa A. Elahi², Aruna Nigam³, Nidhi Gupta⁴

^{1,4}Assistant Professor, ²Associate Professor, ³Professor, Dept. of Obstetrics & Gynecology, Hamdard Institute of Medical Sciences & Research, Jamia Hamdard, New Delhi

***Corresponding Author:**

Email: drneha.himsr@gmail.com

Abstract

Leiomyomas are the most common benign tumors of the uterus, but parasitic fibroid is a rare entity. A parasitic leiomyoma is a type of extra-uterine leiomyoma and presents as pelvic benign smooth-muscle masses separate from the uterus. It originates from pedunculated subserosal leiomyoma that twists and torses from its uterine pedicle and thus the contact between the mass and the uterus is lost. A case of parasitic leiomyoma presenting as an adnexal mass in pregnant female causing obstructed labour is reported. 25 year old primigravida with term pregnancy had an emergency lower segment caesarean section (LSCS) in view of arrest of descent of head (mechanical obstruction). Emergency LSCS revealed B/L hard adnexal masses attached to the ovary. Both the masses were removed and histopathological findings were suggestive of leiomyoma. Parasitic leiomyoma presenting an adnexal mass in pregnant female causing obstructed labour is a rare case presentation with no prior history of any Laparoscopic morcellation procedures or myomectomy.

Keywords: Leiomyoma, Parasitic, Adnexal mass, Pregnancy

Received: 10th May, 2017

Accepted: 29th July, 2017

Introduction

Fibroid tumors are benign tumors found in the uterus of women in their 30's and 40's. They may occasionally develop on other organs besides uterus which contains smooth muscle cells. Parasitic leiomyomas are very rare but have been reported in the literature. Parasitic leiomyomas are formed ones the pedunculated leiomyoma get detached from the uterus and have taken blood supply from the adjacent organs⁽¹⁾ or could be retained myoma fragments following laparoscopic morcellation procedures.

Case Report

25 year old female primigravida at 38 weeks of gestation, booked case in hospital, admitted in labour room for induction of labour in view of term pregnancy with gestational diabetes mellitus (GDM) on injection insulin. During the first trimester ultrasonography a small 2 cm mass was found in the left adnexa. On general physical examination vitals were stable, per abdomen examination was term size, cephalic, uterus relaxed and fetal heart sound 136/minute. Blood investigations were within normal limits, glycosylated haemoglobin was 8.9%, random blood sugar (RBS) 108 mg % and 24 hours urinary protein 1.9 gm %. The patient went into spontaneous labour before induction of labour and per vaginal (P/V) findings at that time were one finger loose dilated, 20 % effaced cervix, membrane present, vertex high up and pelvis was adequate. Patient was not getting good uterine contractions so augmented with oxytocin. There was a failure of descent of head even after 24 hours of syntocinon augmentation and on P/V findings there was a stony calcified hard mass felt on left side and lying below the level of head. This mass was obstructing the

descent of head. Patient was prepared for emergency lower segment cesarean section (LSCS) in view of failure of descent of head (mechanical obstruction). Preoperatively bilateral hard adnexal masses were found. On the right side 4 × 3 cm firm hard mas was present attached to the ovary by a thick pedicle. Right fallopian tube and ovary was normal looking. (Fig. 1)

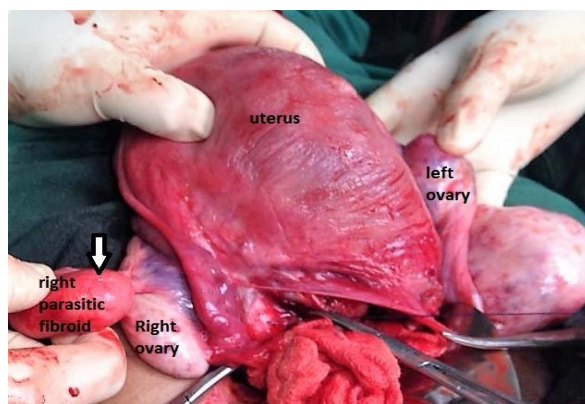


Fig. 1: Right side mass, attached to the right ovary by thick pedicle

On the left side, hard calcified mass 6×5cm was present attached to the left ovarian ligament and left fallopian tube adhered at the fimbrial end otherwise normal looking. This mass was also attached to the omentum and bowel by flimsy adhesions. The left ovary was normal looking. (Fig. 2)

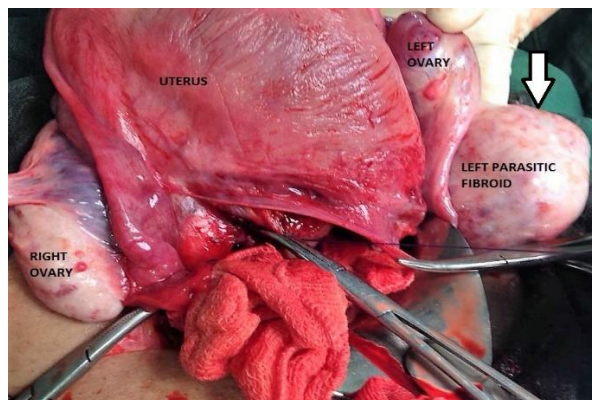


Fig. 2: Left side hard calcified mass, attached to the left ovarian ligament and left fallopian tube

LSCS was done and healthy male baby 2.9 kg delivered. Both the masses were removed and sent for histopathological examination which was suggestive of leiomyoma. Postoperative period was uneventful.

Discussion

Uterine myomas are the commonest benign tumors, with an estimated incidence of about 25% in reproductive age women.⁽¹⁾ They originate from the myometrial smooth muscle cells and according to their location, they are divided into submucous, intramural, and subserosal subtypes.⁽²⁾ In 1909, Kelly and Cullen describe for the first time a “parasitic leiomyoma” made up of smooth muscle cells of the myometrium without any attachment to the uterus.⁽³⁾ The cause and the pathological basis of parasitic leiomyomas are not clearly defined yet in the literature. They might originate from a pedunculated leiomyoma which gets detached from the uterus, attach itself to another organ and develop an auxiliary blood supply. Another possible pathogenesis has been recently proposed on the basis of review of literature on the development of parasitic leiomyoma in women who underwent laparoscopic morcellation procedures, pieces of myometrium which are left after surgery may grow and develop into parasitic myomas with the auxiliary blood supply from adjacent organs and their growth may be promoted by endogenous hormones.⁽⁴⁾

Pedunculated leiomyomas are likely to develop premenopausally, whereas the parasitic leiomyoma can be seen either before or after menopause. The differential diagnosis for a parasitic leiomyoma varies with its location includes: ovarian stromal tumors, leiomyosarcoma, metastatic lesion, and lymphadenopathy. The incidence of parasitic leiomyoma is not clearly defined in the literature but increase incidence has been reported since the introduction of laparoscopic myomectomies or hysterectomies using electrical tissue morcellator⁽²⁾ and in one study (review of literature) reported to be 0.12-0.95%.⁽⁵⁾ Certain Risk factors for parasitic myomas have been found on systemic review and that includes history of previous

surgery with morcellation, use of gonadotropin-releasing hormone or leuprolide acetate therapy and uterine artery embolization. The natural history is not completely understood yet. The parasitic myomas don't have any symptoms, if present they are usually pressure symptoms like pelvic pain, dyspareunia, urinary retention and rarely as adnexal masses mimicking malignancies. Useful modalities to diagnose parasitic myomas are ultrasonography, magnetic resonance imaging (MRI) and computed tomography (CT).⁽⁶⁾ MRI usually shows low signal intensity in case of smooth muscles on T2-weighted images. A strong association between parasitic myomas and prior history of surgery especially laparoscopic morcellation procedures has been seen. Morcellation is mainly use to remove large uterus or myomas through a small laparoscopic incision. In our case report parasitic leiomyoma is reported during pregnancy and causes emergency LSCS because of obstructed labor and there is no prior history of any open or laproscopic myomectomy in the past making it a rare case report.

Conclusion

Parasitic fibroid is a rare entity but it has been reported in the literature. Parasitic fibroid has a varied presentation. An obstetrician should consider the possibility of parasitic fibroid in case an unusual adnexal mass was found on ultrasound during pregnancy.

References

1. A. Theodoros, D. Konstantinos, P. Kalliopi. Cystic degenerated angioleiomyoma mimicking ovarian pathology. *Acta Obstet Gynaecol Scand.* (2001) 80, 863–65.
2. Luciano Di Tizio, Danilo Italo Pio Buca, Daniela Murgano, Carolina Iannantuono et al. *Journal of ultrasound in medicine.* December 1, (2014) 33(12), 2213–16.
3. Kelly HA, Cullen TS. *Myomata of the Uterus.* Philadelphia, PA: WB Saunders Co; 1909.
4. Nezhath C, Kho K. Iatrogenic myomas: a new class of myomas? *J Minim Invasive Gynecol.* (2010) 17, 544–50.
5. Van der Meulen JF, Pijnenborg JM, Boomsma CM, Verberg MF, Geomini PM, Bongers MY. Parasitic myoma after laparoscopic morcellation: a systematic review of the literature. *BJOG.* (2016 Jan) 123(1), 69–75.
6. Fasih N, Prasad Shanhogue AK, Macdonald DB, et al. Leiomyomas beyond the uterus: unusual locations, rare manifestations. *Radiographics.* (2008) 28, 1931–48.