

Flow Volume Graph: Diagnostic Use

Chaitali Hutke, M S Panse

VJTI Mumbai, Maharashtra.

Abstract— In the present document, the flow volume curve obtained from spirometer is studied and used for diagnosis of lung disorders. A Spirometer is the ideal instrument to allow the analysis, determination and monitoring of diverse human respiratory diseases like asthma, pulmonary embolism, respiratory bronchitis and others deficiencies. The flow-volume graphs are displayed by means of a virtual instrument developed in Labview. Flow volume curve is a graphic plot that provides useful information about lung functions and the relation-ship between lung volume and maximal rate of airflow. This is achieved during inspiration and expiration using maximum effort against relevant lung volumes. The test is simple, reproducible and objective.

Keywords— airflow, flow volume curve, forced vital capacity, forced expiratory flow, lung disorders, LabVIEW, spirometry.

INTRODUCTION

Spirometry is a method of assessing lung function by measuring the volume of air that the patient can expel from the lungs after a maximal inspiration. The flow-volume loop is the most important graph in spirometry [1]. A Flow-Volume loop begins at the intersection of the X-axis (volume) and Y-axis (flow). At the start of the test both flow and volume are equal to zero. Directly after this starting point the curve rapidly mounts to a peak: Peak (Expiratory) Flow. The Peak Flow is a measure for the air expired from the large upper airways (trachea-bronchi). After the PEF the curve descends (the flow decreases) as more air is expired. After 25% of the total expired volume, the parameter FEF25 is reached. Halfway the curve (when the patient has expired half of the volume) the FEF50 is reached: Forced Expiratory Flow at 50% of the FVC. After 75% the parameter FEF75 is reached. It is important to realize that there is no time axis on the flow-volume loop so one cannot interpret time intervals. A healthy patient will expire between 70 and 90% of the FVC in the first second of the test. This means that he takes roughly about 5 seconds to expire the last 10 to 30 % of the FVC. When the flow reaches zero, the FVC is reached (Force Vital Capacity): the patient has blown out as much air as he can.

VIRTUAL INSTRUMENTATION

A digital spirometer is designed in LabVIEW which contains three modules one of them is flow volume loop module. The model is constructed in LabVIEW which is graphical programming environment, a Graphical User Interface. It has advantage of fast processing and high detection rate [2]. In flow volume loop module, when LabVIEW runs, it asks to enter information. Database collected in spreadsheet is given as an input to read spreadsheet file. Database collected from patients having different lung disorders is compared with database of normal lung. A popup window is flashed on screen showing type of disease. Front panel of flow volume module is shown in figure 1. Various types of lung diseases which are detected are discussed below:

NORMAL LUNG

In normal flow volume loop, inspiratory limb of loop is symmetric and convex. Expiratory limb is linear. Airflow at the midpoint of inspiratory capacity and airflow at the midpoint of expiratory capacity are often measured and compared. Maximal inspiratory airflow at 50% of forced vital capacity (MIF 50% FVC) is greater than maximal expiratory airflow at 50% FVC (MEF 50% FVC) because dynamic compression of the airways occurs during exhalation [6]. Flow volume graph for normal lung is shown in fig. 2.

OBSTRUCTIVE DISORDER

In patients with obstructive lung disease, the small airways are partially obstructed by a pathological condition. The most common forms are asthma and COPD. A patient with obstructive lung disease typically has a concave F/V loop. The air in the large airways usually can be expired without problems, so PEF may be normal. When all the air is expired from the large airways, air from the smaller airways will be expired. With obstructive lung disease, these airways are partially blocked, so the air will come out slower. This will result in a lower flow and a (more or less) sharp fall in the flow-volume. FEV1 and FEF25-75 will be too low. Typically the patient will have a normal FVC at the early stages of his condition. Although all airflow is diminished, expiratory prolongation predominates, and $MEF < MIF$. Peak expiratory flow is sometimes used to estimate degree of airway obstruction but depends on patient effort [5]. Flow volume graph for obstructive disorder is shown in fig. 3.

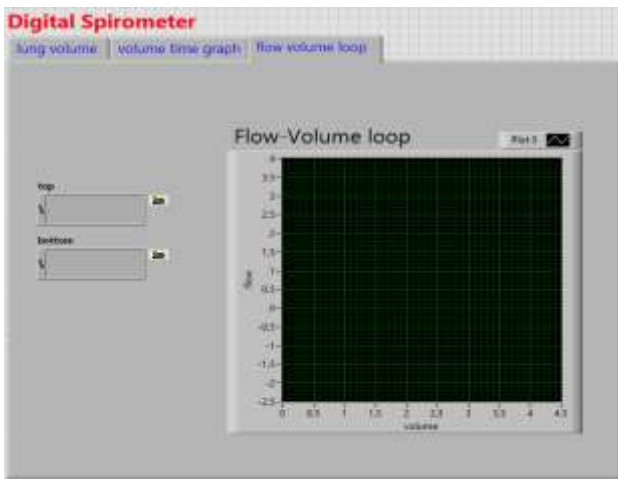


Fig 1: Front panel of flow volume loop

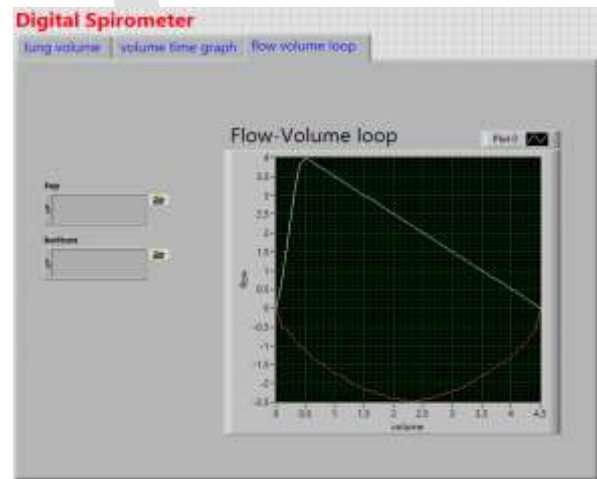


Fig 2: normal flow volume loop

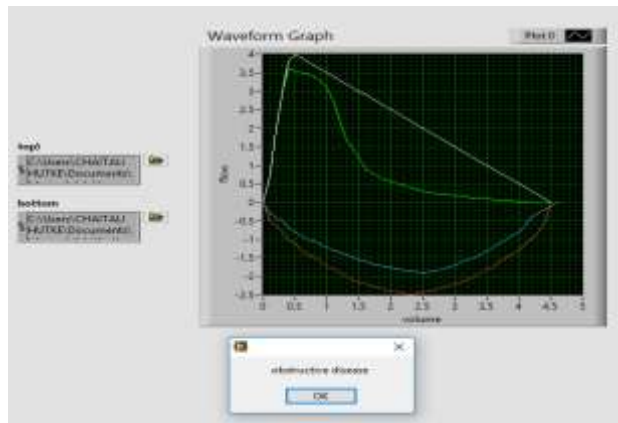


Fig 3: Flow-volume loop in obstructive lung disease

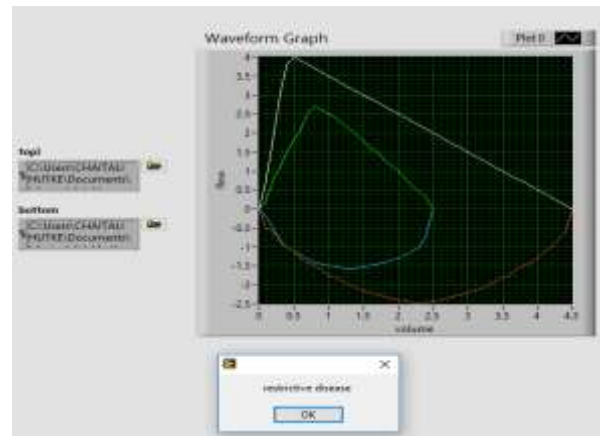


Fig 4: Flow-volume in restrictive lung disease

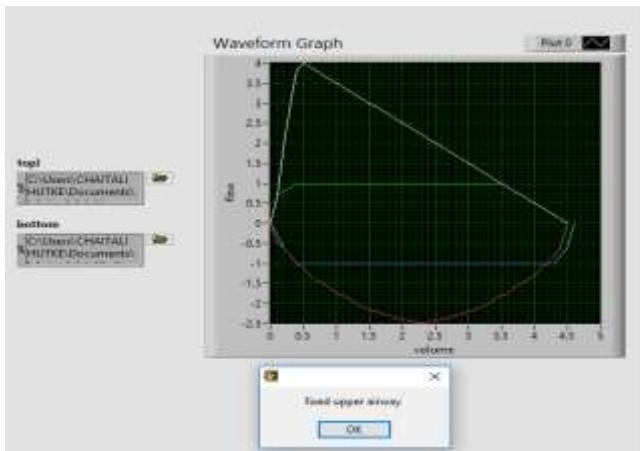


Fig 5: Typical flattening of flow-volume loop in fixed airway obstruction

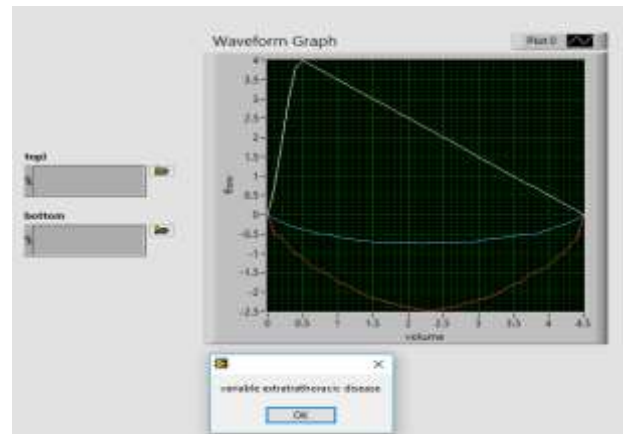


Fig 6: flow volume loop in variable extrathoracic obstruction

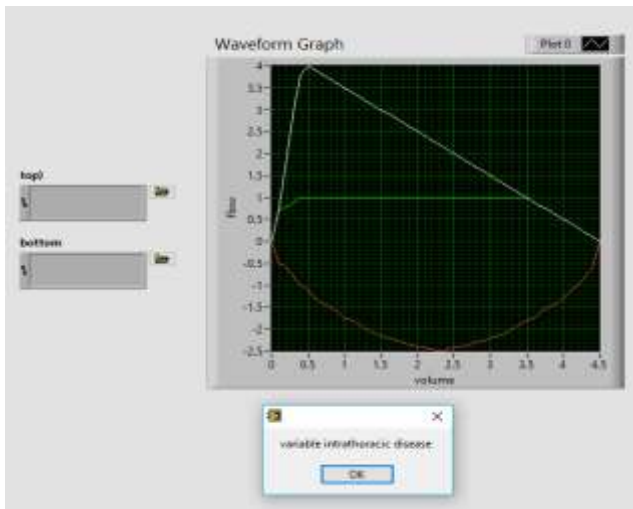


Fig 7: flow volume loop in variable intrathoracic obstruction

RESTRICTIVE DISORDER

Restrictive lung disease means that the total lung volume is too low. Although an accurate diagnosis of total lung volume is not possible with spirometry (residual lung volume cannot be measured with a spirometer) spirometry results can be very suggestive for a restrictive lung disease. Since the airways are normal, the flow volume loop will have a normal shape: the curve will descend in a straight line from the PEF to the X-axis. Total lung volume is low, which results in a low FVC. PEF can be normal or low. The loop is narrowed because of diminished lung volumes. Airflow is greater than normal at comparable lung volumes because the increased elastic recoil of lungs holds the airways open (e.g. interstitial lung disease, kyphoscoliosis) (fig. 4).

FIXED OBSTRUCTION OF THE UPPER AIRWAY

This can be both intrathoracic as extrathoracic. The flow-volume loop is typically flattened during inspiration and expiration. Examples are tracheal stenosis caused by intubation and a circular tracheal tumor. The top and bottom of the loops are flattened so that the configuration approaches that of a rectangle. Fixed obstruction limits flow equally during inspiration and expiration, and $MEF = MIF$ (e.g. tracheal stenosis, goiter) (fig 5).

VARIABLE EXTRATHORACIC OBSTRUCTION

Typically the expiratory part of the F/V-loop is normal: the obstruction is pushed outwards by the force of the expiration. During inspiration the obstruction is sucked into the trachea with partial obstruction and flattening of the inspiratory part of the flow-volume loop. When a single vocal cord is paralyzed, it moves passively with pressure gradients across the glottis. During forced inspiration, it is drawn inward, resulting in a plateau of decreased inspiratory flow. During forced expiration, it is passively blown aside, and expiratory flow is unimpaired. Therefore $MIF\ 50\% FVC < MEF\ 50\% FVC$ (e.g. unilateral vocal cord paralysis, vocal cord dysfunction) (fig. 6).

VARIABLE INTRATHORACIC OBSTRUCTION

This is the opposite situation of the extrathoracic obstruction. A tumor located near the intrathoracic part of the trachea is sucked outwards during inspiration with a normal morphology of the inspiratory part of F/V-loop. During expiration the tumor is pushed into the trachea with partial obstruction and flattening of the expiratory part of the F/V loop. During a forced inspiration, negative pleural pressure holds the floppy trachea open. With forced expiration, loss of structural support results in tracheal narrowing and a plateau of diminished flow. Airflow is maintained briefly before airway compression occurs (e.g. tracheomalacia) (fig. 7).

LIMITATIONS

Because each person's flow volume curve is different and also because disease or drugs may produce changes in the size and shape of the curve, it is extremely difficult to compare flow volume curves between individuals or even within the same individual on different occasions. Although various techniques have been proposed, any form of comparison of flow volume curve is difficult; such measurements from FV curves cannot be routinely recommended for use in lung function laboratories. But the shape of FV curves gives extremely useful information with regard to identification of the cause of airway obstruction and detection of early changes. Lung function studies should be used independently, but should be interpreted in conjunction with other clinical parameters. The variability of the curves at low lung volumes has made it difficult to interpret individual curves even in studies with large population [4].

ACKNOWLEDGMENT

We thank Ankit Sagar, Mtech student for assistance with LabVIEW, and for comments that greatly improved the manuscript.

CONCLUSION

Pulmonary function tests including flow-volume curves are now an essential part of clinical practice as any function tests of other organ systems. But pulmonary function has to be supplemented with other diagnostic procedures. Pulmonary function indicates only how disease has altered the function of lungs. They can-not make a specific pathologic diagnosis and they can reveal alterations only when the lesion disturbs function sufficiently in order to detect the deviation from normal values. Therefore pulmonary function tests supplement a good history, physical examination, radiologic, bacteriologic, bronchoscopic and pathologic studies in arriving at an achievable diagnosis. The results obtained in carrying out the simulation with normal conditions show that data and insights in the literature are validated.

REFERENCES:

- [1] Chaitali Hutke, M.S.Panse, "Lung Volume Measurements-Techniques, Comparison and LabVIEW Based Simulation", International Journal of Scientific & Engineering Research (IJSER), ISSN 2229-5518, Vol-7, Issue-3, March-2016, pg.136-139.
- [2] Poorti M. Vyas, Dr. M. S. Panse, "Various Methods To Detect Respiration Rate From ECG Using LabVIEW", International Conference on Biomedical Engineering and Assistive Technologies, 2010.
- [3] Zhe Cao, Rong Zhu, Member, IEEE, and Rui-Yi Que, "A Wireless Portable System With Microsensors for Monitoring Respiratory Diseases", IEEE transactions on biomedical engineering, Vol. 59, No. 11, November 2012.
- [4] Arora vk and raghu s, "Flow Volume Curves: Clinical Significance", Lung India (1996), Vol. XIV, No.4, Page no. 169-171.

- [5] T R Schermer, J E Jacobs, N H Chavannes, J Hartman, H T Folgering, B J Bottema, C van Weel “Validity of spirometric testing in a general practice population of patients with chronic obstructive pulmonary disease (COPD)”, Vol. 58:pages:861–866, Thorax 2003.
- [6] Renata Kalicka, Wojciech Słomiński, Krzysztof Kuziemski “The Modelling of Spirometry – the Application for Diagnostic Purposes”, 1st International Conference on Information Technology , 19-21 May 2008, Gdansk, Poland.
- [7] V.Brusasco, R.Crapo , G. Viegi, “ATS/ERS task force: standardisation of lung function testing”, Eur Respir J 2005; Vol. 26: pages:511–522.

IJERGS