

## *Pseudomonas Aeruginosa* without any Predisposing Factor in Brain and Lung Abscess

Mohammad Esmaeil Hejazi, Parisa Noorabadi<sup>✉</sup>, Sepideh Tahsini Tekantapeh, Veghar Hejazi and Yasin Hejazi

Respiratory Diseases, Tuberculosis and Lung Disease Research Center, Department of Internal Medicine, Tabriz University of Medical Sciences, Tabriz, Islamic Republic of Iran.

**ABSTRACT:** *Pseudomonas aeruginosa* is the most common cause of brain abscess with source of otitis media and pulmonary source is rare. The aim of present study was to investigate predisposing factors of isolated *Pseudomonas* infections; therefore, the brain and lung abscess caused by *Pseudomonas aeruginosa* in a patient without any predisposing factor is reported. The patient was a 57-year old male presented with headache, vomiting and seizure. He had a history of old myocardial infarction with no diabetes mellitus or immunosuppressed diseases. In the imaging he had abscess in brain and lung. Bronchoalveolar lavage culture and CSF culture were positive for *pseudomonas aeruginosa*. Intra venous broad spectrum antibiotics (ciprofloxacin, vancomycin and colistin) and intra ventricular colistin was administered for three weeks after that the culture of CSF and broncho alveolar lavage had been negative and abscesses were resolved. At fifth week after treatment the patient died because of acute myocardial infarction. According to the present findings more studies should be done about *Pseudomonas* infections.

**Keywords:** *Pseudomonas aeruginosa*, Brain abscess, Lung abscess, Immunosuppressed

CASE REPORT  
PII: S2322-47891500007-5  
Received 11 Nov. 2015  
Accepted 19 Dec. 2015

### INTRODUCTION

*Pseudomonas aeruginosa* is a Gram-negative, aerobic and Gamma Proteo Bacteria (Ryan and Ray 2004). *Pseudomonas aeruginosa* is an emerging opportunistic pathogen of clinical relevance (Bidzinski and Koszewski, 1990). Several different epidemiological studies showed that antibiotic resistance is increasing in clinical isolates of *Pseudomonas aeruginosa* (Brown and Izundu, 2004; Shigemura et al., 2015; Vaez, 2015). The bacterium usually infects compromised tissues. It can cause urinary tract infections, respiratory system infections, dermatitis, soft tissue, bone and joint infections and systemic infections, especially in patients with severe burns, cancer, AIDS, and immunosuppressed patient (Ikpeme et al., 2013). It occasionally causes meningitis after lumbar puncture and endocarditis after cardiac surgery (Mathisen and Johnson, 1997). An abscess is a focus of purulent infection. Brain abscesses often have a mixed flora of aerobic and anaerobic bacteria (Yang, 1981; Bidzinski and Koszewski, 1990). Abscesses usually begin when bacterial growth in sites of necrosis caused by infarction (Johnson, 1996; Aggarwal, 2010). Brain abscesses develop from either a contiguous focus of infection such as the sinuses, the teeth and the ears or hematogenous spread from the lungs or heart, subacute bacterial endocarditis and also cyanotic congenital heart disease. Brain abscess began with focal signs and seizures and also characteristic by Computed Tomography (CT) and Magnetic Resonance

Image (MRI) findings (Rosenblum et al., 1998). Sometimes the sources of abscess in infected cases are undetected. In present report, *Pseudomonas* infection in brain abscess has been isolated.

### CASE REPORT

The patient was a 57 year old man who complained of headache, vomiting and seizure, after admission he had seizure and loss of consciousness and was intubated. Upon examination he had upward gaze and sign of rising intra cranial pressure. The ear canal was erythematous and had pus in external ear. He had coarse crackles in right lung. Other examination was normal. He had history of ischemic heart disease and no diabetes mellitus. Written informed consent was obtained from the patient for publication of this case report and any accompanying images.

In chest x-ray, there was consolidation in right lower lobe (Figure 1). In brain MRI he had mass lesion about 20×21mm in right fronto temporal lobe which is hypersignal in T2W and hyposignal in T1 (Figure 2). In chest CT scan he had an abscess in right lower lobe of lung (Figure 3). Mastoid CT scan showed mild mastoiditis in tip of the mastoid that was not related to brain mass (Figure 4). In echocardiography ejection the fraction was 10-20 % with no vegetation and pericardial effusion. HIV test and viral hepatitis were negative and complement test was normal. ANA, ANTI DSDNA, C3, C4, CH50, CANCA and PANCA were normal. Bronchoalveolar lavage culture

and Cerebrospinal Fluid (CSF) culture were positive for *pseudomonas aeruginosa*. Intra venus broad spectrum antibiotic (ciprofloxacin, vancomycin, colistin) and intra ventricular colistin were administered and external ventricular shunt was put in the brain ventricle (Figure 5). After three weeks the lung abscess was resolved and

broncho alveolar culture and external brain ventricular shunt culture had been negative (Figure 6). The patient was afebrile and vital signs were stable. At the fifth week after treatment he had myocardial infarction; arrhythmia followed by cardiac arrest and was expired.

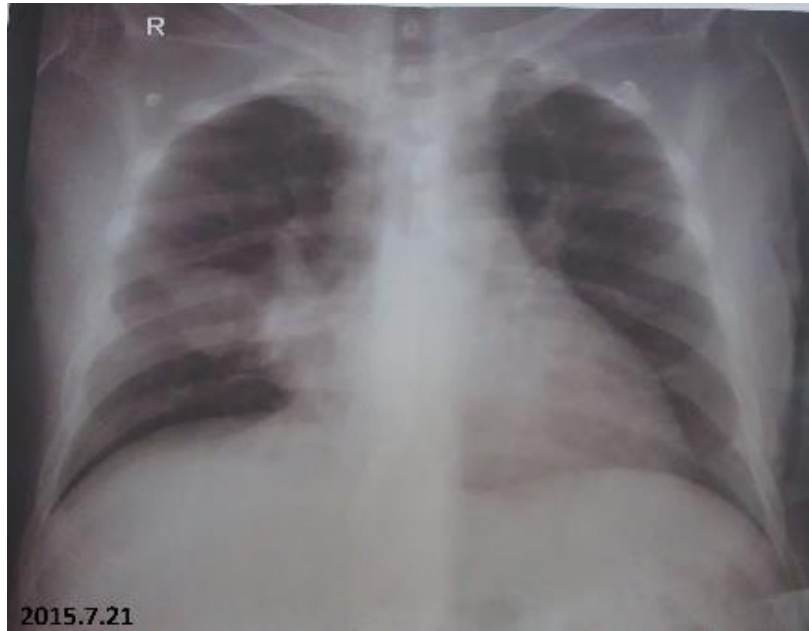


Figure 1. Chest x-ray revealed the consolidation in right lower lobe in an adult man

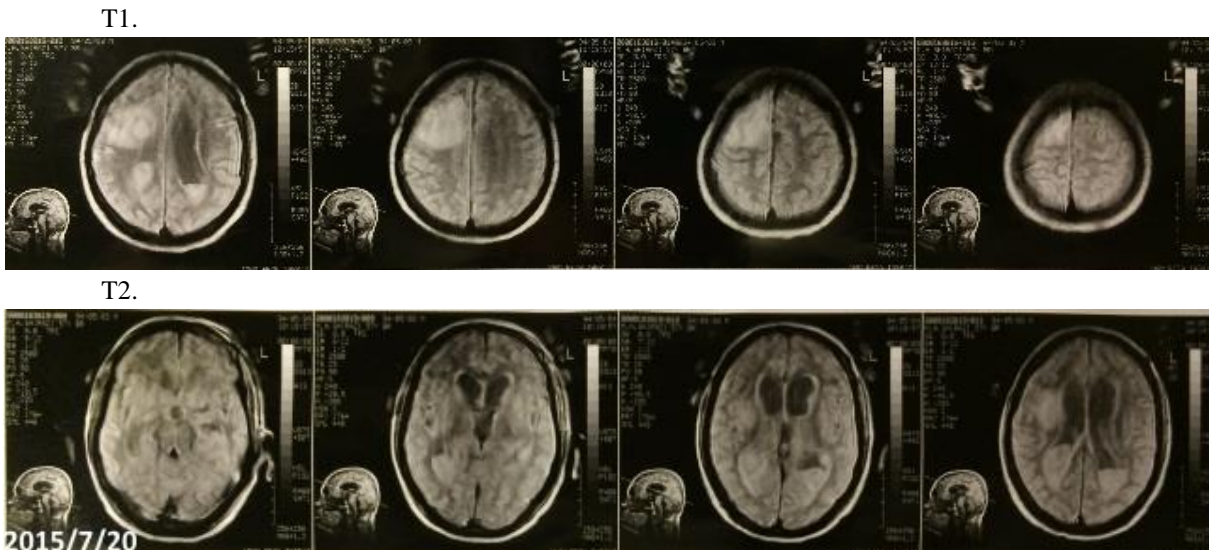
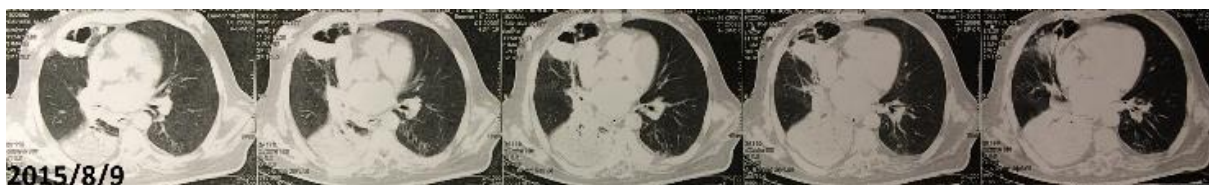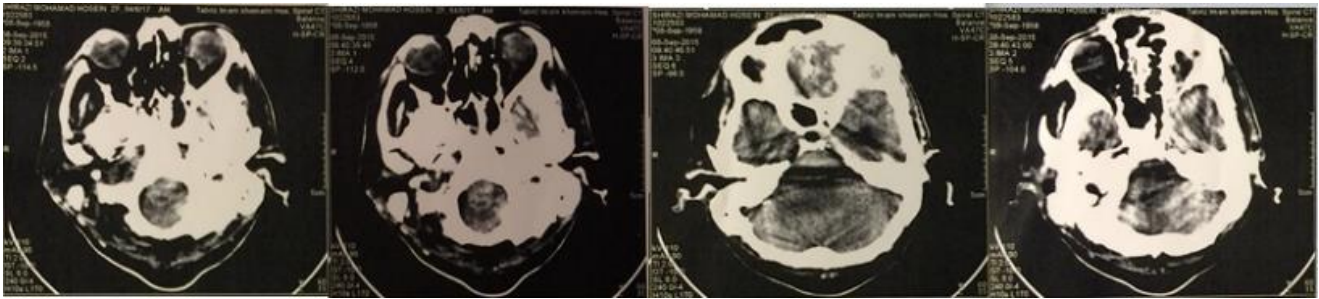


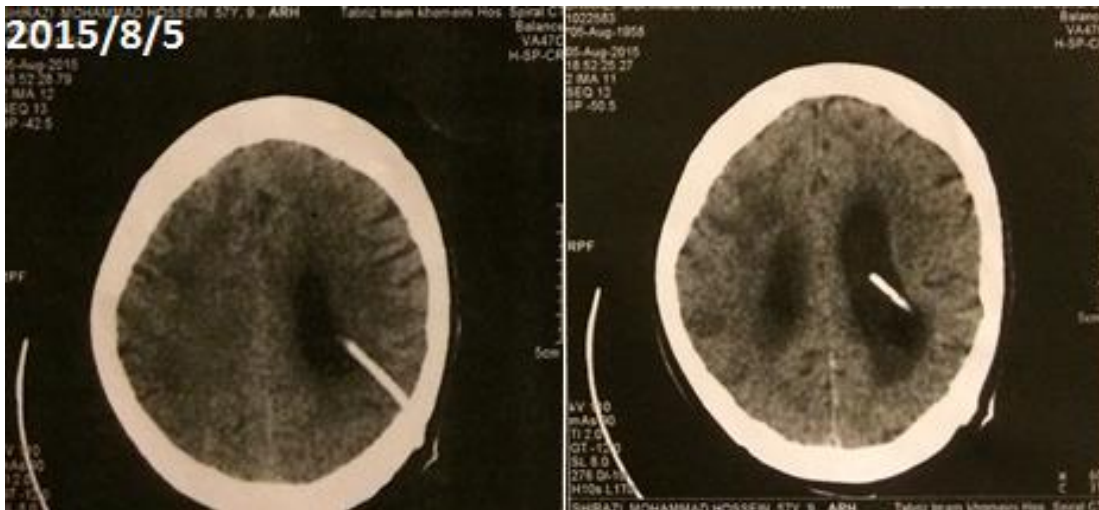
Figure 2. Mass lesion about 20×21mm in right fronto temporal lobe of brain in an adult man



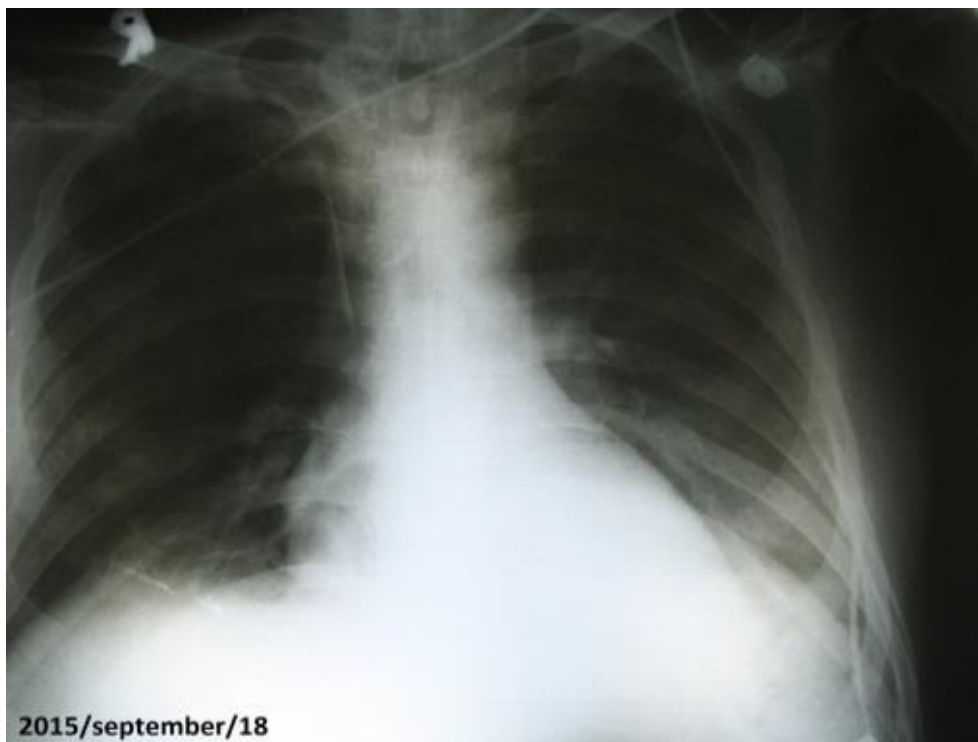**Figure 3.** Chest CT scan, Abscess in right lower lobe of lung in an adult man



**Figure 4.** Brain CT scan, mastoiditis in the tip of mastoid in an adult man



**Figure 5.** Shunt in left ventricle of brain in an adult man



**Figure 6.** Chest x-ray, resolving the lung abscess in an adult man

## DISCUSSION

The causative bacterial infections of brain abscess vary with age, geographic distribution, underlying medical and surgical conditions, period of time and type of pathogen. The frequency of mixed bacterial infections and limitation of anaerobic culture techniques also influence the pathogen prevalence in different studies (Yang, 1981; Bidzinski and Koszewski, 1990). In a study, 123 patients with brain abscess in Taiwan, Viridans streptococci and *Klebsiella pneumonia* were the two main pathogens associated with haematogenous spread (Lu et al., 2002). A Complication of *K. pneumonia* septicaemia is metastatic septic abscess that occurs in diabetic patients with a high mortality rate (Lu et al., 2002). Viridans streptococci were the most prevalent pathogens in paranasal sinusitis; head trauma and post neurosurgical states have become important predisposing factors (Lu et al., 2002). In a study from China indicated that Gram-negative bacilli, with *Proteus*, *Enterobacter* and *Alcaligenesspecies* being common, accounted for 21% (82.400) of the implicated pathogens of brain abscess from 1952 to 1972 (Yang et al., 1981). In a report from Taiwan, Gram-negative bacilli, *Staphylococcus* species and *Streptococcus* species were the major causative pathogens and *K. pneumonia*, *E. coli*, *P. aeruginosa* were the most Gram-negative bacilli associated with haematogenous spread or post neurosurgical states and the scores of multiple metastatic septic abscesses (Kao, 1973). In other reports from Taiwan, association of *Klebsiella* infection with metastatic abscesses has been noted (Tang et al., 1997). In present study *Pseudomonas aeruginosa* in brain and lung abscess was detected. It shows that lung abscess maybe caused the brain abscess. This patient had no risk factor of immunosuppression such as diabetes mellitus, AIDS, hypogamaglobinemia etc. Thus the *Pseudomonas aeruginosa* isolated from brain abscess had no predisposing factor. While *Pseudomonas aeruginosa* was the rare reason of brain abscess after neurosurgery procedure (Yang, 1981; Mathisen GE, Johnson, 1997).

## CONCLUSION

The most common cause of brain abscess is *Pseudomonas aeruginosa* with source of otitis media and rarely causative agent is pulmonary source. Neurosurgical procedure and immunosuppression state such as diabetes mellitus, AIDS, hypogamaglobinemia are the predisposing factor of *Pseudomonas* brain infection but in this study,

brain abscess detected by the source of lung abscess in a patient without any predisposing factors. These results indicate that more studies should be done about *Pseudomonas* infections.

### Competing interests

The authors have declared that no competing interest exists.

## REFERENCES

- Aggarwal A (2010). Medical Microbiology. International Scientific Publishing Academy, Chapter 96, Pp.295.
- Bidzinski J, and Koszewski W (1990). The value of different methods of treatment of brain abscess in the CT era. Acta Neurochir (Wien), 105: 117–20.
- Brown PD and Izundu A (2004). Antibiotic resistance in clinical isolates of *Pseudomonas aeruginosa* in Jamaica. Rev Panam Salud Public, 16(2): 125-30.
- Ikpeme EM, Enyi-Idoh KH, Nfongeh JF, Etim LB and Akubueyi FC (2013). Prevalence, antibiogram profile and cross transmission of *Pseudomonas aeruginosa* in a tertiary burn unit. Mal. J. Microbiol., 9: 116-9.
- Johnson RT (1996). Microbiology of the Nervous System. In: Baron S, editor. Medical Microbiology. 4th edition. Galveston (TX): University of Texas Medical Branch at Galveston; Chapter 96.
- Kao MC (1973). Brain abscess: a clinical analysis of 26 cases with surgical treatment. Bull Tokyo Med., Dent. Univ., 20: 35–50.
- Lu CH, Chang WN, Lin UC, Tsai NW, Liliang PC, Su TM, Rau CS, Tsai UD, Liang CL, Chang CJ, Lee PY, Chang HW and Wu JJ (2002). Bacterial brain abscess: microbiological features, epidemiological trends and therapeutic outcomes, 95 (8): 501-509.
- Mathisen GE, Johnson JP (1997). Brain Abscess, Clinical Infections Disease. Clin. Infect. Dis., 25 (4): 763–81.
- Rosenblum ML, Hoff JT, Norman D, Weinstein PR, Pitts L (1978). Decreased mortality from brain abscess since advent of computerized tomography. J Neurosurg., 59: 658–63.
- Ryan KJ and Ray CJ (2004). Sherris Medical Microbiology, 4<sup>th</sup> ed, McGraw Hill.
- Shigemura K, Osawa K, Kato A, Tokimatsu I, Arakawa S, Shirakawa T and Fujisawa M (2015). Association of overexpression of efflux pump genes with antibiotic resistance in *Pseudomonas aeruginosa* strains clinically isolated from urinary tract infection patients. The Journal of Antibiotics, 68: 568-572.

- Stephanov S (1988). Surgical treatment of brain abscess. *Neurosurgery*, 22: 724–30.
- Tang LM, Chen ST, Hsu WC and Chen CM (1997). *Klebsiella meningitis* in Taiwan: an overview. *Epidemiol Infect.*, 119:135–42.
- Vaez H, Faghri J, Esfahani BN, Moghim S, Fazeli H, Sedighi M and Safaei HG (2015). Antibiotic Resistance Patterns and Genetic Diversity in Clinical Isolates of *Pseudomonas aeruginosa* Isolated From Patients of a Referral Hospital, Isfahan, Iran. *Jundishapur Journal of Microbiology*, 8 (8): e20130.
- Yang SY (1981). Brain abscess: a review of 400 cases. *J Neurosurg*, 55: 794–9.