

## Multidisciplinary approach to anemia

Anca Ghițău<sup>1</sup>, Eduard Dănăilă<sup>1</sup>, Romelia Sfetcu<sup>1</sup>, Lavinia Bârsan<sup>1</sup>, Mihai Șotcan<sup>1</sup>

**Abstract:** *Introduction: We present the case of a 65 years- old woman who was admitted with a severe macrocytic anemia Hb= 5.7g/dl and diffuse bone pain. Biologically she has moderate thrombocytopenia 35 000/μl, a hepatic cytolysis and cholestatic syndrome.*

*Material and method: The patient was extensively evaluated before presentation for a mild iron - deficiency anemia for which she underwent endoscopic examination of the upper and lower gastrointestinal tract- normal. The bone marrow aspiration on admission revealed a marked hyperplasia of the erythroblastic line with ~50% basophilic erythroblasts suggesting a regenerative erythroid hyperplasia. These changes along with the marked reticulocytosis on the peripheral blood smear oriented us towards a hemolytic anemia; Folic acid, vitamin B12, autoimmune tests and hemolytic tests were all normal. We continued the investigations with a thoraco-abdomino-pelvic computed tomography which identified diffuse demineralization, vertebral compactation and pelvic stress fractures. The breast examination revealed a right breast nodule, but the breast ultrasonography pleaded for benignity. Lacking a clear definitive diagnosis we decided to perform a bone marrow biopsy.*

*Results: The osteo- medullary biopsy pointed towards a medullar invasion from a lobular mammary carcinoma; In these circumstances we performed an ultrasound guided biopsy of the right mammary lump thus histologically confirming a tumoral invasion of the bone marrow with subsequent anemia. The patient started chemotherapy in the Oncology ward.*

*Conclusion: The particularity of this case consists in the pattern of anemia, which initially seemed iron deficient and afterwards macrocytic – apparently hemolytic and was actually due to the tumoral medullar invasion and also the nonspecific ultrasonographic appearance of the breast tumor.*

**Keywords:** *anemia, breast cancer, Evans syndrome*

### INTRODUCTION

Anemia is a clinical feature in many emergency admissions to hospital. It is associated with increased mortality, morbidity and length of hospital stay in patients presenting with a range of conditions. If discovered in primary care it is seldom incompletely investigated. Although the most frequent cause of anemia is blood loss, as clinicians, we often find ourselves in front of complex and intricate causes

which lead to a severe deficit. Therefore the management of such patients remains problematic. The prevalence of anemia under widely different conditions and the fact that anemia is managed by clinicians with a broad variety of backgrounds have fostered the need of multidisciplinary teams of experts (primary care physician, gastroenterologist,

<sup>1</sup> Carol Davila Central Emergency Military Hospital, Bucharest

hematologist) to manage such cases.

The most important aspect of treating anemia lies not in correcting it and discharging the patient when stable, but in identifying the cause and reversing it in order to prevent recurrences.

## CASE PRESENTATION

### Disease history

We present the case of a female patient aged 65, living in the country area, whose history began in January 2015. She consulted her family physician for fatigability and after having a series of blood test taken was prescribed iron substitution for 4 months. She had microcytic hypochromic anemia – her hemoglobin was 9.1g/dl, MCV = 72.5 fL, MCH = 24.3 pg and low blood level of iron = 39 ug/dl. Her family physician also recommended some tumor markers (aFP, CEA, CA 19.9) which turned out to be negative.

The patient thoroughly followed the treatment, but at the end of the treatment, when she performed a control full blood count her hemoglobin level was lower. This is the moment when she was referred to us.

### Gastroenterology admission

On admission she was pale, stable hemo- dynamically BP = 120/70 mmHg and HR = 90 bpm and alert, asthenic . She reported not loosing any blood and on rectal examination there were no signs of fresh blood or melena.

Her laboratory data showed anemia with hemoglobin 7.1 g/dl, MCV 110 fl, MCH 35.6pg, blood iron 155 micrograms/dl, platelets 39.000/ $\mu$ l. So we are now facing a macrocytic anemia with a normal iron level and associated thrombocytopenia. Peripheral smear shows macrocytosis, numerous polychromatophylic red cells agglutination, erythroblasts 8% and 7.9% reticulocytes, in conclusion hyperplasic marrow with pronounced erythropoiesis – regenerative erythroid hyperplasia.

Endoscopic examination were performed: upper endoscopy showed duodeno-gastric reflux and small diaphragmatic hernia and colonoscopy revealed hemorrhoidal disease with absent signs of bleeding.

After excluding a bleeding site and because the anemic syndrome was now macrocytic protein electrophoresis, folic acid and vitamin B12 levels were also performed and both were normal.

Because the patient was feeling worse and the hemoglobin was dropping despite blood transfusion and iron supplementation she was transferred to Hematology for further investigation.

### Hematology admission

In addition to fatigability, after 4 days in the gastroenterology ward, the patient now reports bone pain, without loss of range of motion. The pain responds to usual analgesics. On examination she is stable and on physical examination we discover superficial bilateral axillary lymph nodes 1.5 cm diameter, mobile and non tender and a right mammary nodule on breast examination .

Laboratory test now shows a worsening anemia and thrombocytopenia with a hemoglobin of 5.7 g/dl, MCV 114 fl, platelets 35.000/ $\mu$ l, Iron 304 micrograms/dl and hepatocytolytic and cholestatic syndrome: AST 108 UI/l, ALT 45 UI/l, GGT 228 UI/l (N 7-50), alkaline phosphatase 180 UI/l (N 38-91 UI/l), LDH 1081 (N 266-500). Hepatic viral serology was negative for hepatic viruses B and C. Coombs test and cold agglutinins test were also negative.

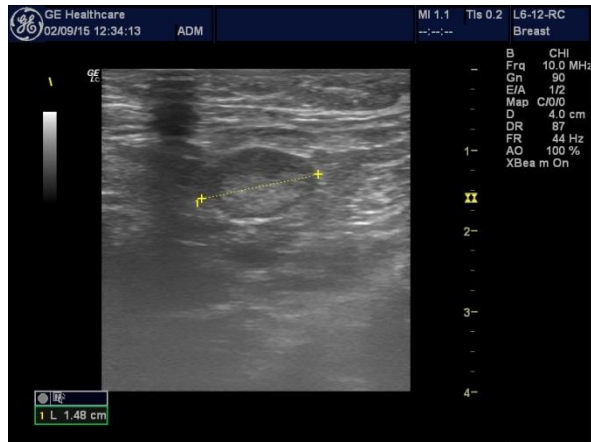
Ultrasonography was also performed and showed fatty liver and normal sized spleen without abdominal adenopathy, the heart was normal. Soft tissue ultrasonography shows bilateral axillary lymph nodes with a possible non-inflammatory character and 1.5 cm diameter. We also identified smaller lymphadenopathy bilaterally in the cervical area, resembling the appearance. On breast examination we described fibromatous placard in the supero-external area of the right breast with the long axis parallel with the skin, 4a BIRADS classification.

The biological panel strongly resembled Evans syndrome on admission, so we immediately decided to start treatment with high doses of dexamethasone while continuing investigations.

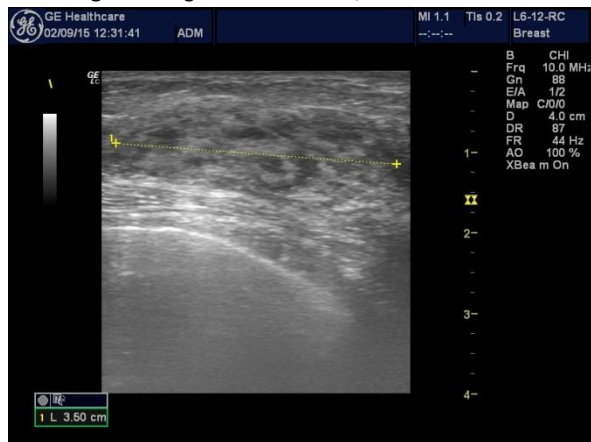
The non-inflammatory character of the axillary adenopathies prompts searching for additional lymph

nodes. Therefore tomography of the thorax and abdomen was performed and it identified diffuse demineralization of the scanned bones, numerous vertebral compression fractures and stress fractures of both iliac wings, during consolidation.

**Figure 1.** Right axillary lymph node, 1.48 cm diameter



**Figure 2.** Right breast nodule, 3.5 cm diameter

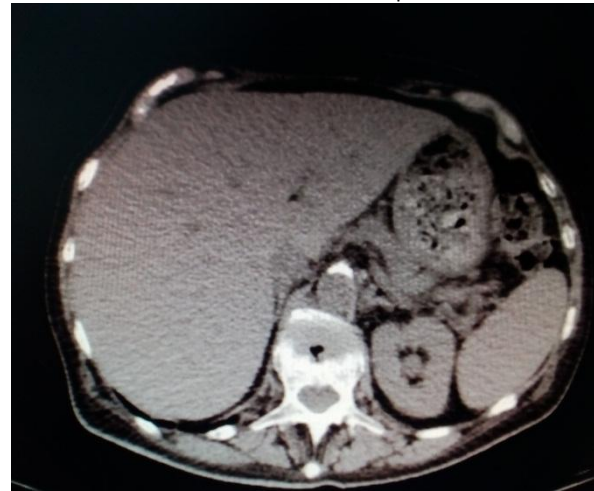


Not having a definite diagnosis and because our patient was feeling worse and her hemoglobin was stationary despite treatment, we performed a diagnostic test.

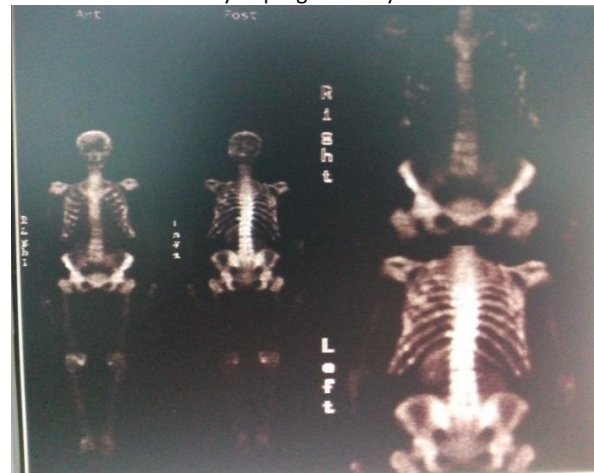
A bone marrow biopsy was performed. Histologically and imuno-histochemically a metastatic lobular carcinoma of the breast was identified. Faced with a metastasis from a still not identified tumor, we returned to the fibromatous placard we saw in the right breast and an echo-guided biopsy of the nodule was performed. The biopsy revealed a lobular carcinoma strongly positive for estrogen receptors

(ER) and negative for progesterone receptors (PR) and E-cadherin by immunohistochemical staining. The tumor marker was intensely elevated – CA 15-3 530 mg/dl.

**Figure 3.** Thoraco-abdominal CT showing diffuse demineralization and vertebral compression fracture



**Figure 4:** Whole body bone scintigraphy: low visualization of kidneys>> “super-scan” pattern pleading for secondary bone determinations with a possible paraneoplastic medullary impregnation syndrome



### Oncology admission

The patient was referred to oncology and she started chemotherapy with capecitabine and zoledronic acid after stabilization. The oncologist further investigated the implication of the bone system through a whole body bone scintigraphy. The result pleaded for multiple secondary bone determinations with a possible paraneoplastic medullary impregnation syndrome. Three months after initiation of

appropriate systemic treatment for metastatic disease we see a partial recovery of hematopoietic function – her hemoglobin rose to 9 g/dl and platelets are around 90.000/ $\mu$ l.

## COMMENTS

In conclusion, in front of a typical anemia that doesn't respond to typical treatment, as clinicians, we are obliged to search for additional causes and "cut the weed at the root".

The particularities of this case reside in the biochemical profile of the anemia – iron deficient at first encounter, then suggestive of Evans syndrome which delayed the diagnosis. In addition the ultrasonographic appearance of the breast tumor – more typical of a fibromatous degeneration did not raise suspicion at the first glance.

Breast cancer is the most common malignancy in

women. Approximately 80% of women with metastatic breast cancer have skeletal metastases, which are often the result of bone marrow infiltration of malignant cells with subsequent progression and invasion of the skeletal cortex [1][2][3][4][5]. The most common complications of skeletal metastases are pathologic fractures, spinal cord compression as the result of vertebral compression fracture or extension of the tumor beyond the epidural space, and hypercalcemia [3][4][5]. Furthermore, skeletal metastases sometimes require surgery or radiation therapy to treat pain or an impending fracture. Bone marrow metastases result in the invasion and destruction of the bone tissue matrix by tumor cells [2]. Although bone marrow infiltration with micro metastasis is commonly present among breast cancer patients, total bone marrow infiltration – bone marrow carcinomatosis, BMC – resulting in profound pancytopenia is extremely rare.[2][6][7]

## References:

1. Marks PW, Rosenthal, DS. - Hematologic manifestations of systemic disease: infection, chronic inflammation, and cancer. In: Hoffman R, Benz EJ, Shattil SJ, et al, eds. Hematology: Basic Principles and Practice. 5th ed. Philadelphia, PA: Churchill Livingstone Elsevier. 2009;2309-2319
2. C. Kamby, B. Guldhammer, I. Vejborg, et al. - The presence of tumor cells in bone marrow at the time of first recurrence of breast cancer Cancer, 60 (1987), pp. 1306–1312
3. R.E. Coleman, R.D. Rubens - The clinical course of bone metastases from breast cancer Br. J. Cancer, 55 (1987), pp. 61–66
4. C.S. Galasko - Skeletal metastases- Clin. Orthop. Relat. Res., 210 (1986), pp. 18–30
5. C.S. Galasko - The development of skeletal metastases- Nihon Seikeigeka Gakkai Zasshi, 63 (1989), pp. 667–676
6. M.B. Klevesath, K. Pantel, O. Agbaje, et al. - Patterns of metastatic spread in early breast cancer Breast, 22 (2013), pp. 449–454
7. Kopp HG, Krauss K et al. - Symptomatic bone marrow involvement in breast cancer – clinical presentation, treatment, and prognosis: a single institution review of 22 cases. Anticancer Res, 2011, Nov; 31(11):4025-30