



## Thyroxin-binding globulin deficiency in a boy with fragile X syndrome: a case report

Raheleh Mirsadraee (MD)<sup>1</sup>, Saba Vakili (MD)<sup>1</sup>, Mohammad Reza Abbaszadegan (PhD)<sup>2</sup>,  
Rahim Vakili (MD)<sup>1,3\*</sup>

<sup>1</sup>Department of Pediatric Endocrinology and Metabolism, School of Medicine, Mashhad University of Medical Sciences, Mashhad, Iran.

<sup>2</sup>Medical Genetic Research Center, Department of Human Genetics, Imam Reza Hospital, School of Medicine, Mashhad University of Medical Sciences, Mashhad, Iran.

<sup>3</sup>Immunology Research Center, Department of Human Genetics, Avcinna Research Institute, Mashhad University of Medical Sciences, Mashhad, Iran.

### ARTICLE INFO

#### Article type

Case report

#### Article history

Received: 25 May 2016

Revised: 6 Jun 2016

Accepted: 29 Jun 2016

#### Keywords

Fragile X syndromes

Hypothyroidisms

TBG deficiency

Thyroid function test

### ABSTRACT

Fragile X syndrome (FXS) is the most common known genetic cause of male intellectual disability. A wide variety of medical problems has been reported in FXS syndrome including seizures, facial abnormalities, macroorchidism, and autistic disorders. Here we reported a 9-year-old boy with fragile X syndrome that was confirmed through karyotyping and mental retardation. Initially, he was diagnosed as hypothyroidism when he was 15 months old. However, due to unusual clinical presentation, we re-evaluated the patient according to his history and clinical findings. Subsequently, targeted laboratory tests were performed and the results were indicative for thyroxin-binding globulin (TBG) deficiency in our patient. Therefore, levothyroxine was discontinued and one month later, laboratory tests were repeated and his diagnosis confirmed. As inherited TBG deficiency might also be X-linked, FXS and TBG deficiency may be coincidental findings in the patient.

Please cite this paper as:

Mirsadraee R, Vakili S, Abbaszadegan MR, Vakili R. Thyroxin-binding globulin deficiency in a boy with fragile X syndrome: a case report. Rev Clin Med. 2016;3(4):171-174.

## Introduction

Fragile X syndrome (FXS) is a common genetic disorder, which is considered as the most common cause of male mental retardation. It might be presented in various clinical manifestations including mental retardation, cognitive and behavioral disorders, macroorchidism, joint hyperlaxity, and some facial abnormalities such as large forehead, narrow face, prominent chin, and large and anteverted ears (1-3). Approximately, the FXS incidence is about one out of 2000-5000 individuals (4), and it is more prevalent in males than females (1).

FXS is a chromosome X-linked disorder caused by a dynamic mutation in exon 1 of the FMR-1 (Fragile X-linked Mental Retardation type 1) gene. This gene is located on the band q27.3 of the chromosome X.

This dynamic mutation occurs as a result of an expanded CGG (cytosine-guanine-guanine) trinucleotide repeats (5).

However, 25-30% of these patients do not present the typical characteristics of FXS (1). Several studies have investigated the role of thyroid dysfunction in FXS (6-8). It has been hypothesized that thyroid dysfunction may contribute to macroorchidism in males with FXS (9,10).

Thyroxin-binding globulin (TBG), a 54 kilodalton glycoprotein, is the major transporting protein of thyroid hormone in human serum (11). TBG consists of 395 amino acids, and it is located on the long arm of the X chromosome between bands xq21 and xq22 (xq22.2) (12). Therefore, most of

\*Corresponding author: Rahim Vakili.

Department of Pediatric Endocrinology and Metabolism, School of Medicine, Mashhad University of Medical Sciences, Mashhad, Iran.

E-mail: vakilir@mums.ac.ir

Tel: 09151145830

This is an Open Access article distributed under the terms of the Creative Commons Attribution License (<http://creativecommons.org/licenses/by/3.0>), which permits unrestricted use, distribution, and reproduction in any medium, provided the original work is properly cited.

the TBG abnormalities are inherited in X-linked manner (13). Whereas, estrogen excess is among the causes of increased serum TBG concentration, corticosteroids administration decrease the serum TBG concentration independently (14,15).

TBG deficiency is either acquired or inherited through X-linked inheritance. The cause of both is defects in TBG gene. Mutations in this gene may result in partial or complete TBG deficiency, which is sometimes accompanied by other genetic defects such as carbohydrate deficient glycoprotein syndrome type 1 (CDG1), an autosomal recessive disease. Some of the TBG deficiency acquired causes include hyperthyroidism, chronic renal or liver failure, malnutrition, HIV/AIDS, and severe systemic illness (16).

### Case presentation

A 9-year-old boy was referred to our pediatric endocrinology clinic, Imam Reza Hospital, Mashhad, Iran with an initial diagnosis of hypothyroidism. According to his past medical history, he was born via normal vaginal delivery with a normal Apgar score at birth. His birth weight was 3450 grams. His mother stated that he had weakness, delayed crying, and poor feeding in infancy. His growth pattern seemed to be normal, whereas his development was retarded as he was unable to sit before 15 months. In addition, his speech was retarded, he was easily irritated, and frequently cried and knocked his head. He was not toilet-trained (voiding control) before 4 years old.

In his familial history, he was the second child in a family of four. The parents were not related by blood. His mother and elder sister were receiving levothyroxine for hypothyroidism.

At 15 months, a total T4 of 3.1  $\mu$ IU/ml (normal range: 5.1-12.5  $\mu$ IU/ml for 7-16 y) and a TSH of 6.8  $\mu$ IU/ml (normal range: 0.6-5.2  $\mu$ IU/ml for 7-12 y) were noted and accordingly, the patient was treated with levothyroxine. Periodic laboratory results are listed in Table 1. In addition, it should be noted that the patient previously received clonidine, risperidone, biperiden, and carbamazepine due to his behavioral disorders. No abnormalities were reported in his brain CT scan.

At the time of admission to pediatric endocrinology clinic, the patient's height was 150 cm (Height Z-score: 2.54), his weight was 42 kg (weight Z-score: 1.6), and his body mass index was 18.6. Physical examination revealed macroorchidism, as the testes size with orchidometer was more than 3cc (normal size in prepubertal boys is 1-3 cc), and puberty was in Tanner stage one. Based on his initial examination and past medical history, TBG deficiency was suspected. Therefore, levothyroxine was discontinued and laboratory tests were repeated after one month. The results were as the followings: TSH: 3.2  $\mu$ IU/ml, Total T4: 4.8  $\mu$ IU/ml, T3RU: 42%, Free T4: 24 pmol/L.

Thyroid laboratory profiles in the patient's mother and sister also indicated TBG deficiency. Following confirmation, their levothyroxine was discontinued as well. One year after cessation of

**Table 1.** Thyroid functional tests in the patient.

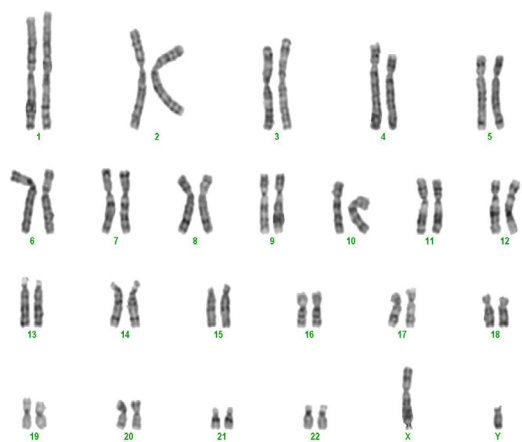
Date	TSH ( $\mu$ IU/ml) (Normal range: 0.6-5.2 $\mu$ IU/ml for 7-12y)	T4 ( $\mu$ g/dl) (Normal range: 5.1-12.5 $\mu$ g/dL for 7-16 y)	T3 ( $\mu$ g/dl) (Normal range: 90-240 ng/dL for 5-10 y)	T3RU (%) (Normal range: 25-37%)	Free T4 Index (ratio) (Normal range: 1.2-4.5)	Free T4 (pmol/l) (Normal range: 10.3-23)
2002 Aug	6.8	3.1	67			
2002 Sep	1.2	4	110			
2002 Oct	1.5	5.2	170			
2003 Jun	1.8	4.2				
2003 Nov	1.3	4.8	32			
2004 Apr	0.9					
2009 May	0.6					
2009 Oct	2.7					
2009 Nov	3.2	4.8		42(H)	2	24(H)
2012 Mar	3.7	<2		44(H)		15.4

H: high

therapy, the mother's laboratory results were as the following: TSH: 2  $\mu$ IU/ml, Total T4: 2.9  $\mu$ IU/ml, T3RU: 29%, Free T4: 9.1 pmol/L. Considering the probable diagnosis of FXS based on mental retardation and macroorchidism, genetic evaluation requested for the patient and FXS 46, XY, Fra(x)(q27.3) was reported.

In the latest follow-up, when he was 10 years old, the patient's height was 152 cm and his weight was 60 kg. The thyroid profile was as follow: TSH: 3.7  $\mu$ IU/ml, Total T4: <2  $\mu$ IU/ml, T3RU: 44%, FT4: 15.4 pmol/l. He was under observation by pediatric psychologists for 5 years because of his developmental delay.

Peripheral blood samples were collected from the patient for karyotyping evaluation. With GBG banding (G-bands after trypsin and Giemsa) in 100 metaphases in a folate deficient medium, fragile site was observed (Figure 1).



**Figure 1.** The karyotype of the patient, 46, Y, fraX(q27.3) with X chromosome showing fragile site at Xq27.3 (arrow shows this site on terminal end of X chromosome long arm).

## Discussion

FXS is a common chromosomal disorder, and understanding new aspects of this syndrome is likely to be useful for diagnosis and treatment. It is responsible for about 30% of all mental retardations and is associated with diverse clinical manifestations (1,2). However, 25-30% of patients with FXS do not present typical clinical signs (1). The patient reported in this study was a 9-year-old boy with macroorchidism and TBG deficiency whom karyotyping result was compatible with FXS.

Several studies have investigated the role of thyroid dysfunction in FXS (6-8), but up to our best knowledge, this is the first report of TBG deficiency accompanied by FXS syndrome.

Coincidence or association of FXS with TBG deficiency is quite rare. It seemed that as the inherited TBG deficiency may be X-linked, FXS and TBG defi-

ciency might be associated. However, it remained controversial and requires further investigation whether they are coincidental or associated.

Some investigators have evaluated thyroid function in FXS (9,10). Bregman and colleagues (9) evaluated thyroid profiles in twelve 3-28 years old males with FXS. Their study demonstrated that T4, TBG, and EFT (estimated free thyroxin) values were within normal ranges. No correlations between age with serum T4 and EFT levels were observed. TSH response to thyrotropin releasing hormone (TRH) was blunted and baseline prolactin was elevated in these patients. These results supported hypothalamic-pituitary abnormalities in FXS (9). In our case, EFT, TSH, and T3RU were normal, but total T4 was low due to TBG deficiency.

FMR1 and TBG genes are located on Xq27.3 and Xq22.3, respectively. Togetherness of these conditions would be possible if they were part of contiguous gene syndrome due to a large deletion on this site. But, the gene sites are not contiguous. Moreover, FXS is a triplet repeat (allelic expansion) disorder, not a deletion syndrome. There is no reported similar case so far. Therefore, coincidence is the most probable explanation for this togetherness.

## Conclusion

In summary, we presented a 9-year-old boy with FXS and TBG deficiency in his mother, sister and himself. Because TBG deficiency may be inherited X-linked, FXS might be associated with TBG deficiency. However, it is controversial and requires further investigations whether they are coincidental or associated. In many syndromes with mental retardation in boys such as Down syndrome, FXS and Klinefelter syndrome, thyroid functional tests are abnormal. We should interpret thyroid functional tests carefully because misinterpretation of tests in mental retarded patients may lead to delayed or overlooked diagnosis of hypothyroidism.

## Consent

Written informed consent was obtained from the patient's father for the publication of this report and any accompanied images.

## Conflict of Interest

The authors declare no conflict of interest.

## References

1. Terracciano A, Chiurazzi P, Neri G. Fragile X syndrome. *Am J Med Genet C Semin Med Genet.* 2005;137C:32-37.
2. Rousseau F, Labelle Y, Bussi eres J, et al. The fragile x mental retardation syndrome 20 years after the FMR1 gene discovery: an expanding universe of knowledge. *Clin Biochem Rev.* 2011;32:135-162.
3. Ridaura-Ruiz L, Quinteros-Borgarello M, Berini-Ayt es L, et al. Fragile X-syndrome: literature review and report of two cases. *Med Oral Patol Oral Cir Bucal. Med Oral Patol Oral Cir*

- Bucal. 2009 Sep;14:e434-439.
4. Hessel D, Glaser B, Dyer-Friedman J, et al. Social behavior and cortisol reactivity in children with fragile X syndrome. *J Child Psychol Psychiatry*. 2006;47:602-610.
5. Jacquemont S, Curie A, des Portes V, et al. Epigenetic modification of the FMR1 gene in fragile X syndrome is associated with differential response to the mGluR5 antagonist AFQ056. *Sci Transl Med*. 2011;3:64ra1.
6. Indumathi CK, Bantwal G, Patil M, et al. Primary hypothyroidism with precocious puberty and bilateral cystic ovaries. *Indian J Pediatr*. 2007;74:781-783.
7. Mann DR, Plant TM. The role and potential sites of action of thyroid hormone in timing the onset of puberty in male primates. *Brain Res*. 2010;1364:175-185.
8. Wajner SM, Wagner MS, Maia AL. Clinical implications of altered thyroid status in male testicular function. *Arq Bras Endocrinol Metabol*. 2009;53:976-982.
9. Bregman JD, Leckman JF, Ort SI. Thyroid function in fragile-X syndrome males. *Yale J Biol Med*. 1990;63:293-299.
10. Wagner MS, Wajner SM, Maia AL. The Role of Thyroid Hormone in Testicular Development and Function. *J Endocrinol*. 2008;199:351-365.
11. Mannavola D, Vannucchi G, Fugazzola L, et al. TBG deficiency: description of two novel mutations associated with complete TBG deficiency and review of the literature. *J Mol Med (Berl)*. 2006;84:864-871.
12. Jehee FS, Rosenberg C, Krepischi-Santos AC, et al. An Xq22.3 duplication detected by comparative genomic hybridization microarray (Array-CGH) defines a new locus (FGS5) for FG syndrome. *Am J Med Genet A*. 2005;139:221-226.
13. Seo H. Thyroxine-binding globulin gene and variants. *Nihon Rinsho*. 2006;Suppl 1:508-512.
14. Shifren JL, Desindes S, McIlwain M, et al. A randomized, open-label, crossover study comparing the effects of oral versus transdermal estrogen therapy on serum androgens, thyroid hormones, and adrenal hormones in naturally menopausal women. *Menopause*. 2007;14:985-994.
15. Tahboub R, Arafah BM. Sex steroids and the thyroid. *Best Pract Res Clin Endocrinol Metab*. 2009;23:769-780.
16. Tarm Ö. Thyroid hormones and growth in health and disease. *J Clin Res Pediatr Endocrinol*. 2011;3:51-55.