



The use of magnetic resonance imaging to study the brain size of young children with autism

Farah Ashrafzadeh (MD), Mehran Beiraghi Toosi (MD), Mohammad Hasan Mohammadi (MD)*

¹Department of Pediatric Neurology, Ghaem Hospital, Mashhad University of Medical Sciences, Mashhad, Iran.

ARTICLE INFO

Article type

Systematic review article

Article history

Received: 12 May 2015

Revised: 7 Jun 2015

Accepted: 20 Jun 2015

Keywords

Autism
Brain size
Children

ABSTRACT

Introduction: Autism spectrum disorder (ASD) is a syndrome of social communication deficits and repetitive behaviors or restricted interests. While the impairments associated with ASD tend to deteriorate from childhood into adulthood, it is of critical importance that the syndrome is diagnosed at an early age. One means of facilitating this is through understanding how the brain of people with ASD develops from early childhood. Magnetic resonance imaging (MRI) is the method of choice for in vivo and non-invasive investigations of the morphology of the human brain, especially when the subjects are children. In this study, we conducted a systematic review of existing structural MRI studies that have investigated brain size in ASD children of up to 5 years old.

Methods: In this study, we systematically reviewed published papers that describe research studies in which the brain size of ASD children has been examined. PubMed and Scopus databases were searched for all relevant original articles that described the use of MRI techniques to study ASD patients who were between 1 and 5 years old. To be included in the review, all studies needed to be cohort and case series that involved at least 10 patients. No time limitations were placed on the searched articles within the inclusion criteria. The exclusion criteria were non-English articles, case reports, and articles that described research involving subjects that were not within the qualifying age range of 1-5 years old.

Result: After an initial screening process through which the title, abstracts, and full text of the articles were reviewed to confirm they met the inclusion criteria, a total of 10 relevant articles were studied in depth. All studies found that children with ASD who were within the selected age range had a larger brain size than children without ASD.

Discussion: The findings of recent studies indicate that the vast majority of ASD patients exhibit an enlarged brain; however, the extent of the enlargement varies from study to study. As such, further studies are required to develop an understanding of the areas of the brain in which enlargement manifests in children with ASD before the age of five and to verify the significance of the prognostic value of MRI as a non-invasive diagnostic technique that can be employed to detect ASD in young children.

Conclusion: Based on the extracted data, brain size was related to the emergence and presence of autism in children who were below school age. The use of MRI represents a functional and non-invasive method of confirming ASD in children who have an initial ASD diagnosis.

Please cite this paper as:

Ashrafzadeh F, Beiraghi Toosi M, Mohammadi MH. The use of magnetic resonance imaging to study the brain size of young children with autism. *Rev Clin Med.* 2016;3(3):105-110.

***Corresponding author:** Mohammad Hasan Mohammadi.
Department of Pediatric Neurology, Ghaem Hospital, Mashhad
University of Medical Sciences, Mashhad, Iran.
E-mail: dr.mohammadimh@yahoo.com
Tel: 09153427393

This is an Open Access article distributed under the terms of the Creative Commons Attribution License (<http://creativecommons.org/licenses/by/3.0>), which permits unrestricted use, distribution, and reproduction in any medium, provided the original work is properly cited.

Introduction

Autism spectrum disorder (ASD) is a heterogeneous and persistent neurodevelopment disease that affects 1 in 150 children (1,2). It is associated with various symptoms: 1) severe and sustained impairment in social interaction, 2) reduced and impaired communication abilities, and 3) restricted and/or stereotyped patterns of behavior and interest. These behaviors typically present by the time the child reaches the age of 3 years old (3,4).

There is a general agreement that children who have autism tend to exhibit signs of developmental delay within the first 18 months. However, 25-45% of children with autism initially demonstrate near-normal development until 18-24 months or beyond (2). On the whole, the disease emerges prior to the point at which children reach the age of 3; however, clinical presentation of the disorder is complex and can vary from one patient to the next (3,5).

Although the causes of autism remain relatively unknown, some researchers have suggested that genetic, developmental, and environmental factors could contribute to the development of autism (4). While the exact etiopathological mechanisms of ASD are still not comprehensively understood, a variety of data indicates that the condition can be attributed to disturbances in brain growth and maturation as a significant pathomechanism (3).

Over the course of the last three decades, several magnetic resonance imaging (MRI) studies have examined the brain anatomy of patients with autism in order to identify structural abnormalities and enlargement in some parts of the brain. Through these studies, frontal lobes, amygdala, and cerebellum were highlighted as pathological in autism; as such, these areas of the brain have attracted significant attention in studies that investigate the morphology of the brain (2-4). MRI is considered to represent the gold-standard technique for the identification of structural brain alterations in patients with neuropsychiatric disorders such as autism, and it is widely regarded as a valuable method through which a neuroanatomic model of pathophysiology can be developed, and ultimately, effective therapeutic interventions can be identified (4). Through the use of imaging technology, researchers have observed that the overall brain weight of children (2- 4.5 years) with autism is statically heavier than that of age and gender-matched controls (6). Furthermore, there is also evidence from child and adolescent samples to suggest that much can be learned by examining the impact of early variation in the trajectories of anatomical brain development and their influence on later outcomes (9).

While a great deal of research and discussion has focused on whether the brain size of people

with autism is abnormal, the majority of research studies have not mentioned age-related changes in brain development. Those that do, have raised the possibility that the brain of younger children with ASD is enlarged (5). Although there is a common perception that the brain development of children with ASD is abnormal, there is little evidence of this disorder in the published literature (13).

In a word, a further understanding of the brain size and development of children with ASD during the first five years of life is of utmost importance in supporting early clinical diagnosis and developing early behavioral interventions. To contribute to knowledge in this area, this study aimed to review and summarize existing morphometric brain investigations that employed MRI with patients with autism as a means of examining the structural brain anatomy and development of autistic children who were aged 1 to 5 years.

Methods

To review the literature, we followed the PRISMA guidelines to query the PubMed and Scopus databases using the following search terms: (magnetic resonance imaging OR MRI) AND ((Autism spectrum disorder (ASD) OR Autism) AND brain structure) AND (magnetic resonance imaging" OR MRI AND "Autism spectrum disorder" (ASD) OR Autism AND brain size) AND (brain MRI AND Autism AND "brain volume").

The last search was conducted between the 21st and 26th March 2015. The title and abstracts of all identified articles were studied and then irrelevant articles were omitted. The full text of the remaining articles was then reviewed, and any articles that were deemed to be irrelevant in terms of the objectives of this systematic review were also omitted. The reference list of the relevant articles was screened to detect any further articles that had not been identified during the database search process.

There were no constraints in terms of the dates of the research papers employed within the research; however, only English-language articles were considered as part of the systematic review. Reviews were not included in the selection, but were used to identify any additional original studies. We searched all the selected papers to include studies in which the mean age of the ASD sample was below five years of age. Studies that focused only on ASD subjects with known etiology (e.g., Fragile-X, syndrome, tuberous sclerosis) were not included. Any studies that involved less than 10 patients and all case reports were excluded.

Data about the authors, publication data, country, patient characteristics (age, gender, duration of the diseases), and the results of the MRI were extracted.

The initial search strategy yielded a total of 757

records. After the removal of duplicates, 63 remained. Of these, only 10 met the inclusion criteria and were case-control studies. The search procedure was summarized in a PRISMA Chart and can be seen in Figure 1.

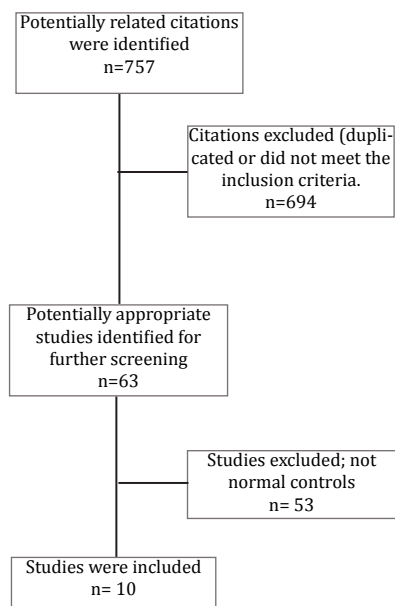


Figure 1. PRISMA flow diagram: the screening process of articles in the current study.

Data synthesis

The evidence table presented in Table 1 presents a summary of the data that was extracted from the eligible studies. The results were organized according to the data that provided an association between the incidence of ASD patients and MRI study parts, and information on sample demographics, authors, and the brain size are reported in Table 1.

Results

Based on the methodology, a total of 757 articles were obtained in our initial search. After deleting the duplicate and irrelevant articles, only 10 studies remained that were deemed to be relevant to our inclusion criteria.

The population size of the included studies ranged between 492 and 338 ASD/control and the mean age of the patients and controls ranged between 1 and 5 years. Overall, 492 ASD patients were considered in this systematic review. Their brain size and volume as measured by MRI are presented in Table 1.

Discussion

Over the last few decades, structural MRI studies in children have increasingly been used to identify relations between brain size and behavioral brain abnormalities like autism (9). In this regard, several studies have found that children with autism

exhibit an enlarged brain during childhood (7,8). Within the current study, all 10 selected articles, with the exception of one, demonstrated that the vast majority of ASD patients exhibited an enlarged brain size; however, the extent of this enlargement varied in different studies and for different parts of the brain. Therefore, further studies are required to develop further insights into the areas of the brain that are most likely to be enlarged in the case of children under the age of five who have ASD. In addition, further analysis of the use of MRI as a non-invasive diagnostic technique for diagnosing ASD is also worth further attention.

Several MRI studies involving very young children with autism report a 5-10% abnormal enlargement in total brain volume that persists into early childhood (10-12). Similarly, Hazlett et al. (2005) and Courchesne et al. (2001) found that children with autism exhibit enlargement of the whole brain size (25,10). On the other hand, a study by Hashimoto et al. (1999) found that the whole brain size of children with ASD who were aged between 3-5 years old was smaller than that of the healthy controls (27). To the best of our knowledge, that particular study is the only one to correlate smaller brain size with ASD children in this age range.

The timing of brain enlargement in autism is of particular importance given new evidence from prospective behavioral studies involving ASD infants (15). Some researchers have concluded that an abnormal accelerated rate of growth may serve as an early warning signal that there is a risk for autism (16). In light of this important issue, the study population involved in this review was limited to children who were under the age of 5 years old. Nevertheless, it is overwhelmingly accepted that the brain size of children with autism is slightly reduced at birth and that it dramatically increases within the 4-5 first years of life before eventually reaching a plateau by adulthood (14).

Researchers consistently agree that people with ASD exhibit an accelerated brain volume growth in early childhood of around 10%. This enlargement appears to peak at around 2-4 years of age (18). Ninety percent of 2- and 3-year-old children have brain volumes that are larger than the healthy average (16). Consequently, based on the importance of the first five years of life in terms of brain development as a potential indication of ASD, we selected children aged from 1-5 years as the inclusion criteria for the study selection. Thus, at the age of typical clinical diagnosis of the disorder (i.e., 3-4 years old), the period of pathological growth and arrest has likely already passed, leaving clinicians and researchers with an outcome, rather than a process of pathology by which treatment intervention can be studied (14).

Author Country Year Reference	No. of ASD pa- tients	No. of health control	Age range	Sex	MRI findings	Evaluated brain parts by MRI
Sparks USA 2002 (7)	45	40	3-4 Y	M/F	Increased cerebral volume and amygdala enlargement	Volumes of the cerebrum and cerebellum and amygdala
Ortiz-Mantilla Japan 2010 (9)	15	12	1 Y	M/F	Increase in total and right Amygdala volume but NOT left one.	Amygdala volume
Courchesne USA 2001 (10)	30	52	2-4 Y	M	By age 2-4 Y 90% of ADS boys had a brain volume larger than normal	Cross-sectional, multistage, complex sample survey
Hazlett USA 2011 (15)	59	38	2-4 Y	M/F	Cerebral cortical and tempo- ral enlargement	Cerebral gray and white , matter plus cortical thick- ness
Courchesne USA 2003 (16)	48	15	2-5 Y	M	Excessive increase in cere- bral gray matter	Cerebral gray matter and cerebral cortex
Hazlett USA 2005 (25)	51	25	1.5-3 Y	M/F	Cerebral cortical enlarge- ment (both white and gray matters)	Whole brain
Nordahl Canda 2011 (26)	114	66	2-4 Y	M/F	Abnormal brain enlargement was seen in boys	Whole brain
Hashimoto Japan 1992 (27)	21	24	3-5 Y	M/F	Smaller mid brain Pons, me- dulla oblongata and vermis lobule	Whole brain
Bloss USA 2007 (28)	36	27	3-5 Y	F	Enlargement in whole brain, cerebral, gray and cerebella white matter volume	Gray and white matter (whole cerebrum, cerebral lobes and cerebellum)
Akshoomoff USA 2004 (29)	52	15	2-5 Y	M	Larger whole brain volume	Gray and white matter volumes (cerebellum and cerebrum) and total brain volume

M; Male; F; Female; Y; Year; MRI; Magnetic resonance imaging.

The amygdale plays an important role in language ability, and this region of the brain has heterogeneous structure and function. Moreover, it is intimately connected with the hypothalamus and has dense projections to the brain stem, the frontal and temporal lobes, and to the thalamus (9). As such, the structural evaluation of this region has importance through the diagnostic procedure and, as per the findings of Sparks et al. (2002), Ortiz Mantilla et al, (2010) found that this area of the brain was enlarged in the case of children with ASD who were in this age range (7,9).

As a result, abnormal brain growth was reported in several studies. This abnormal development might be characterized by an increased rate of

brain growth from early infancy (2- to 3-year-old) through the preschool period (particularly in the frontal, temporal, parietal lobes, and cerebellum), followed by an abnormally slow cerebral and cerebellar volume increase during late childhood or even puberty and adolescence (19-22). Similarly, the results of the studies by Hazlett et al. (2011), Courchesne et al. (2003), Bloss et al. (2007), and Akshoomoff et al. (2004) that were identified as part of this systematic review, all showed an enlargement in cerebral and cerebellar volume (15,16,28,29).

Additionally, it was found that mostly white matter (WM) increases during childhood and adolescence in the case of children with ASD, while the

trajectories of grey matter (GM) volumes follow an inverted U-shaped developmental trajectory. The different developmental curves of WM and GM belie the intimate connections among neurones, glial cells, and myelin, which are fellow components in neural circuits and are linked by lifelong (17). According to our results, Hazlett et al. (2005), Courchesne et al. (2001), Courchesne (2003) and Bloss et al. (2007) found the WM and GM increased size in ASD children. Similarly, other studies reported that brain size in 4-year-old children with autism exceeded the healthy average, and that excessive brain size was primarily due to increased WM volumes in the cerebellum and cerebrum and increased GM volume in the cerebrum, within which frontal lobes were the most abnormal (10,16,23-25,28).

More broadly, the early and transient period of brain overgrowth and understanding the mechanisms and influences on structural and functional brain development across childhood must be an important factor in the emergence of autistic behavior and may help us to harness the brain's developmental plasticity to help guide interventions for clinical disorders and to elucidate the path by which optimal development can be promoted (16,17).

Conclusion

On the basis of the existing literature, we can conclude that autism is associated with generalized enlargements of the cerebral hemispheres, the cerebellum, and amygdala. Alternatively, apparent differences in the results of some studies may result from differences in age range selected and image processing. Furthermore, some regions have abnormal developmental trajectories that could point towards particular etiopathological factors and timeframes for possible interventions using trajectories (i.e., morphometric measures by age) because an endophenotype may provide discriminating power where static measures do not. Overall, the findings of the studies included in this systematic review were in agreement with the exception of just one 1991 study, which contradicted the results of the others. Therefore, 9 out of 10 articles demonstrated that the use of MRI and brain imaging can predict autism in children aged between 1-5 years.

Acknowledgement

This study was the result of a medical resident thesis with approval number 930563. It was financially supported by the Research Vice Chancellor of Mashhad University of Medical Sciences.

Conflict of Interest

The authors declare no conflict of interest.

References

- Conti E, Calderoni S, Marchi V, et al. The first 1000 days of the autistic brain: a systematic review of diffusion imaging studies. *Front Hum Neurosci*. 2015;9:159.
- Amaral DG, Schumann CM, Nordahl CW. Neuroanatomy of autism. *Trends Neurosci*. 2008; 31:137-145.
- Nickl-Jockschat T, Habel U, Michel TM, et al. Brain Structure Anomalies in Autism Spectrum Disorder-A Meta-Analysis of VBM Studies Using Anatomic Likelihood Estimation. *Hum Brain Mapp*. 2012; 33:1470-1489.
- Brambilla P, Hardan A, di Nemi SU, et al. Brain anatomy and development in autism: review of structural MRI studies. *Brain Res Bull*. 2003;61:557-569.
- Bolton P, Macdonald H, Pickles A, et al. A case-control family history study of autism. *J Child Psychol Psychiatry*. 1994;35:877-900.
- Bauman ML, Kemper TL. Neuroanatomic observations of the brain in autism: a review and future directions. *Int J Devl Neuroscience*. 2005;23:183-187.
- Sparks BF, Friedman SD, Shaw DW, et al. Brain structural abnormalities in young children with autism spectrum disorder. *Neurology*. 2002;59:184-192.
- Aylward EH, Minshew NJ, Field K, et al. Effects of age on brain volume and head circumference in autism. *Neurology*. 2002;59:175-183.
- Ortiz-Mantilla S, Choeb MS, Flaxa J, et al. Associations between the size of the amygdala in infancy and language abilities during the preschool years in normally developing children. *NeuroImage*. 2010;49:2791-2799.
- Courchesne E, Karns CM, Davis HR, et al. Unusual brain growth patterns in early life in patients with autistic disorder: An MRI study. *Neurology*. 2001;57:245-254.
- Hazlett H. Magnetic resonance imaging and head circumference study of brain size in autism: Birth through age 2 years. *Arch Gen Psychiatry*. 2005;62:1366-1376.
- Schumann CM, Bloss CS, Barnes CC, et al. Longitudinal magnetic resonance imaging study of cortical development through early childhood in autism. *J Neurosci*. 2010;30:4419-4427.
- Lange N, Travers BG, Bigler ED, et al. Longitudinal Volumetric Brain Changes in Autism Spectrum Disorder Ages 6-35 Years. *Autism Res*. 2015;8:82-93.
- Redcay E, Courchesne E. When Is the Brain Enlarged in Autism? A Meta-Analysis of All Brain Size Reports. *Biol Psychiatry*. 2005;58:1-9.
- Hazlett HC, Poe M, Gerig G, et al. Early Brain Overgrowth in Autism Associated with an Increase in Cortical Surface Area Before Age 2. *Arch Gen Psychiatry*. 2011;68:467-476.
- Courchesne E, Carper R, Akshoomoff N. Evidence of Brain Overgrowth in the First Year of Life in Autism. *JAMA*. 2003;290:337-344.
- Giedd JN, Rapoport JL. Structural MRI of Pediatric Brain Development: What Have We Learned and Where Are We Going? *Neuron*. 2010;67:728-734.
- Anagnostou E, Taylor MJ. Review of neuroimaging in autism spectrum disorders: what have we learned and where we go from here. *Mol Autism*. 2011;2:4.
- Bailey A, Luthert P, Bolton P, et al. Autism and megalencephaly. *Lancet*. 1993;341:1225-1226.
- Carper RA, Courchesne E. Inverse correlation between frontal lobe and cerebellum sizes in children with autism. *Brain*. 2000;123:836-844.
- Carper RA, Moses P, Tigue ZD, et al. Cerebral lobes in autism: early hyperplasia and abnormal age effects. *Neuroimage*. 2002;16:1038-1051.
- Ciesielski KT, Harris RJ, Hart BL, et al. Cerebellar hypoplasia and frontal lobe cognitive deficits in disorders of early childhood. *Neuropsychologia*. 1997;35:643-655.
- Cooke R, Lucas A, Yudkin P, et al. Head circumference as an index of brain weight in the fetus and newborn. *Early Hum Dev*. 1977;1:145-149.
- Courchesne E. Abnormal early brain development in autism. *Mol Psychiatry*. 2002;7:S21-S23.
- Hazlett HC, Poe M, Gerig G, et al. Magnetic Resonance Imaging and Head Circumference Study of Brain Size

- in Autism Birth Through Age 2 Years. *Arch Gen Psychiatry*. 2005;62:1366-1376.
26. Nordahl CW, Lange N, Li DD, et al. Brain enlargement is associated with regression in preschool-age boys with autism spectrum disorders. *Proc Natl Acad Sci U S A*. 2011;108:20195-200.
 27. Shimoto T, Murakawa K, Miyazaki M, et al. Magnetic resonance imaging of the brain structures in the posterior fossa in retarded autistic children. *Acta Paediatr*. 1992;81:1030-1034.
 28. Bloss CS, Courchesne E. MRI Neuroanatomy in Young Girls With Autism: A Preliminary Study. *J Am Acad Child Adolesc Psychiatry*. 2007;46:515-523.
 29. Akshoomoff N, Lord C, Lincoln AJ, et al. Outcome Classification of Preschool Children With Autism Spectrum Disorders Using MRI Brain Measures. *J Am Acad Child Adolesc Psychiatry*. 2004;43:349-357.
 30. Romieu I, Sienra-Monge JJ, Ramirez-Aguilar M, et al. Antioxidant Supplementation and Lung Functions among Children with Asthma Exposed to High Levels of Air Pollutants. *Am J Respir Crit Care Med*. 2002;166:703-709.