



The effect of intravitreal bevacizumab injection on the corneal endothelial cells : systematic review

Akbar Derakhshan (MD), Alireza Eslampour (MD), Esmail Safinezhad (MD)*,
Samira Hasanzadeh (MD)

¹Cornea Research Center, Department of Ophthalmology, Khatam Al-Anbia Eye Hospital, Mashhad University of Medical Sciences, Mashhad, Iran.

ARTICLE INFO

Article type

Systematic review article

Article history

Received: 11 Mar 2015

Revised: 10 Apr 2015

Accepted: 15 Apr 2015

Keywords

Avastin

Endothelial Cells

Eye Diseases

ABSTRACT

Introduction: Bevacizumab (Avastin), as an effectiveness treatment modality, is currently used in patients with various ocular disease. However the results have been promising, the use of bevacizumab in the treatment of ocular disease is an off-label application. Hence, the aim of this study was to systematically review the effectiveness of intravitreal injection of bevacizumab on various ocular tissues, especially corneal endothelial cells.

Methods: The articles related to the effect of application of Avastin in the treatment of ophthalmic diseases and especially its effect on corneal endothelial cells were collected and reviewed. We searched PubMed, Google scholar, and Scopus databases and used Avastin, ocular diseases and corneal endothelial cells as search keywords.

Result: Of all 55 articles found in all databases, only 10 were relevant to the purpose of this study, and 45 articles were excluded in several step by step process of article selection according to the inclusion/exclusion criteria. The results revealed that intracameral bevacizumab injection caused no changes in specular microscopy and corneal pachymetry. Moreover, it had no significant toxicity on corneal endothelial cells.

Discussion: Effectiveness of bevacizumab as a new modality in the treatment of different ophthalmic diseases have been suggested. Recent data on both human and animal models showed that intravitreal injection of bevacizumab resulted in no significant toxicity on various ocular cells, and it could be considered as a suitable therapeutic approach in clinical use.

Conclusion: According to the results of included documents, bevacizumab was not toxic to corneal endothelial cells at various clinically relevant doses.

Please cite this paper as:

Derakhshan A, Eslampour A, Safinezhad E, Hasanzadeh S. The effect of intravitreal bevacizumab injection on the corneal endothelial cells. *Rev Clin Med.* 2016;3(2):78-83.

Introduction

Bevacizumab with the trade name of Avastin is a humanized monoclonal antibody with various therapeutic applications. Bevacizumab is mostly known as an anti-angiogenesis agent, which inhibits the growth and the development of new blood vessels. Its anti-angiogenesis property is thought to be mediated through inhibiting vascular endothelial growth factor A (VEGF-A) (1). Hence, the most acceptable

mechanistic pathway of bevacizumab antitumor activity is the binding to VEGF and inhibiting its signal pathway (2). The relative efficiency of bevacizumab in the treatment of several tumor and non-tumor diseases has been confirmed. Food and Drug Administration (FDA) of the United States has approved bevacizumab as an effective medication for the treatment of various medical conditions such as

*Corresponding author: Esmail Safinezhad.

Cornea Research Center, Khatam Al-Anbia Eye Hospital, Mashhad University of Medical Sciences, Mashhad, Iran.

E-mail: safinezhade901@mums.ac.ir

Tel: 09173750423

This is an Open Access article distributed under the terms of the Creative Commons Attribution License (<http://creativecommons.org/licenses/by/3.0>), which permits unrestricted use, distribution, and reproduction in any medium, provided the original work is properly cited.

different types of cancers and eye diseases. In 2004, FDA approved Avastin as an effective medication for the treatment of metastatic colorectal cancer in combination with some other conventional chemotherapeutic agents (3). Soon after, and during 2006 to 2010, it was the first-line clinical management for the treatment of other types of malignancies such as lung, breast, brain, and renal cancers (4).

Bevacizumab is now widely used for treating several ophthalmic complications including retinal neovascularization, macular edema, neovascular glaucoma, and other ocular problems (5-7). Moreover, it is demonstrated that intravitreal injection of bevacizumab is an effective therapy in patients with intraocular neovascular complications and macular edema (8). However the results reported for the clinical applications are promising, the use of Avastin for therapeutic purpose in ocular diseases is an off-label application. Therefore, it is of great importance to reevaluate its efficacy and safety in ocular tissues (2). Several studies have shown that bevacizumab at therapeutic quantities that is typically used for treating retinal disorders, had no significant toxicity to the retinal pigment epithelial (RPE) cells, retinal ganglion cells, or corneal endothelial cells (2,7,9). Since VEGF and its receptors (Flt-1 and Flk-1) are highly expressed in inflamed and vascularized corneal tissues, and therefore they may have crucial role in corneal neovascularization. Bevacizumab is suggested as possible therapeutic agent for the treatment of corneal neovascularization, thus it is recommended to evaluate the efficacy and potentially cytotoxicity of bevacizumab on corneal endothelial cells (2,9,10). According to the results in databases, we did not find any meta-analysis or systematic review article about the effect of Avastin injection on corneal endothelial cells. In this study, we aim to systematically review various clinical studies to evaluate the effect of intravitreal bevacizumab injection on the corneal endothelial cells.

Methods

Search methods

We studied the articles related to the application of Avastin in the treatment of ophthalmic diseases and specially its effect on corneal endothelial cells. We searched PubMed and Scopus databases using the terms: Avastin (bevacizumab), ocular diseases and corneal endothelial cells. Related articles with the following search term "(Intravitreal Bevacizumab injection) AND Corneal Endothelial" was used to find studies in which the Avastin has been used to treat ocular tissues. Google Scholar was also searched with the earlier described search strategy to include other relevant documents. The search was performed with the last update on March 2015. As well, the reference list of each

included document was screened to include other additional suitable and related documents.

Study selection and inclusion/exclusion criteria

No time limitation was defined for the included articles, but only articles in English language were selected and used for further data extraction to avoid any possible errors and misinterpretation during the whole process of data extraction. Different types of the articles with various study designs including case-controls, case reports, clinical trials, cross-sectional, and prospective cohort studies were included in this review study. However, conference papers, letters, review articles, and meta-analysis were excluded from further assessment. Inclusion criteria were all the documents in which the efficacy of intravitreal bevacizumab injection on corneal endothelium had been evaluated. Duplicated documents and papers with subject or language irrelevancy were excluded by reviewing the title, keywords, and abstract in the first step of article selection. Studies on animals or in vitro studies were excluded from further assessment.

Data extraction

Data including publication date, study design, country of origin, name of the first author, method of assessment, and critical findings were extracted and systematically sorted based on the main purpose of this study. All existing data including total number of patients and demographic data of studied individuals were collected in regard to the previously defined inclusion and exclusion criteria. Data were systematized based on the results of selected studies reporting the effects and therapeutic value of intravitreal bevacizumab injection on corneal endothelium. We extracted the data reporting the qualitative, quantitative, and morphological changes of ocular endothelium after administration of different doses of bevacizumab. All processes including data extraction and selection of the articles were performed according to the recommendation of PRISMA 2009 checklist (11).

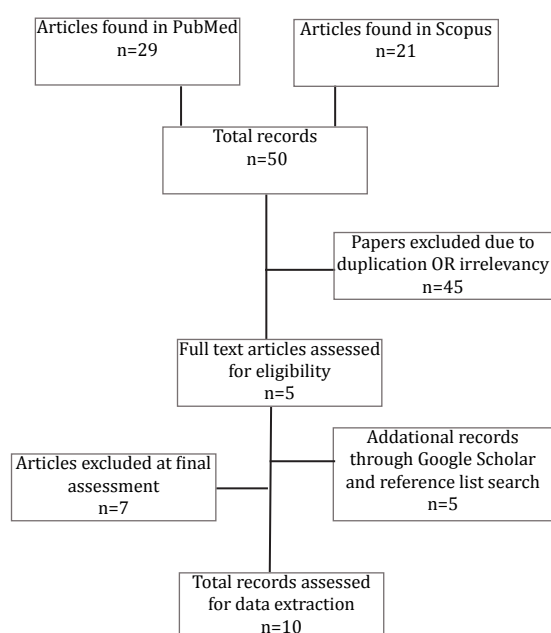
Results

Study search results

From total of 29 articles found in PubMed, and 21 records in Scopus search, we omitted 25 articles in the first step by reviewing the abstract of articles due to irrelevancy. Moreover, 20 duplicated documents or articles with language irrelevancy were excluded in subsequent process of article selection, and only 5 unique records seemed related to the main subject of this study. Two additional documents were also included by manual reference

screening of the previously included articles. Three unique records were also included by searching Google Scholar. Finally, according to the previously defined inclusion/exclusion criteria, and after comprehensive reviewing of the included articles, only 10 relevant papers, which fully met the inclusion criteria, were selected and the desired data were carefully extracted based on the results reporting the effects of bevacizumab injection on corneal endothelium. Figure 1 shows the step by step process of literature search and study selection.

Figure 1. Flowchart for selection of studies



General characteristics of the included articles

The total number of patients were 1375, participated in the selected studies in which the effects of intravitreal bevacizumab injection had been evaluated on corneal endothelium. Mean age of the studied patients was 56.8 years, but it should be noted that the age of studied patients had not been mentioned in two studies (12,13). Minimum and maximum ages of all participants were 21 and 89 years, respectively. Of these patients, 565 were males and 778 were females. In one study with 32 studied patients, the sex ratio was unknown (12). The duration of the studies varied from 1 month to 1 year. Different doses of Avastin ranging from 0.5 mg to 25 mg were used for the treatment of different ocular diseases. In the selected articles, different methods including specular microscopy images, central corneal thickness (CCT) measuring, multifocal electrophysiologic testing, intraocular pressure (IOP) changes, the mean diameter of the corneal vessels, and endothelial cell counting were used to assess the effects of intravitreal injection

of bevacizumab on corneal endothelium. In Table 1, general characteristics of included studies are summarized.

Study results

Data showed complete safety for intravitreal bevacizumab injection in the corneal endothelium. In addition, according to the results of included studies, injection of different doses of bevacizumab seemed to have no destructive effects on the corneal endothelium. Up to 12-month follow-up in patients with various ocular diseases such as diabetic retinopathy and macular degeneration who had been treated with intravitreal injection of bevacizumab showed no significant changes in the corneal endothelium after bevacizumab injection (17). Table 2 shows the main clinical outcomes of treatment with different doses of Avastin. According to the results of included studies, bevacizumab injection does not cause ocular toxicity, especially on corneal endothelial cells. But, the results of a study that had been conducted on 45 eyes of 32 patients showed that treatment with intravitreal bevacizumab may possibly cause systemic side effects (12).

Discussion

So far, several clinical trials have been conducted on the effect of Avastin injection in the treatment of ophthalmic diseases (21,22). The results of some studies showed that bevacizumab did not cause considerable cytotoxicity on human retinal pigment epithelium, rat retinal ganglions, and pig choroidal endothelial cells (7,23). In addition, majority of experimental findings supported the efficacy and safety of intravitreal bevacizumab injection at different doses. However, some studies demonstrated that bevacizumab might have adverse effects on the proliferation of primary retinal epithelial cells and cell viability at higher concentration of around 2,500 microg/ml (24). Moreover, findings were suggestive of clear anti-angiogenic activity and anti-fibrotic effects of bevacizumab after corneal burn (25). Pharmacological and toxicological assessment of the topical bevacizumab showed that topical administration of bevacizumab has no adverse effects on epithelium and endothelium if used in the treatment of corneal neovascularization (17). Therapeutic potency of bevacizumab has also been evaluated in iris rubeosis (12,26). The results of these studies demonstrated that no inflammation or relapse occurred within the short-term follow-up of up to four weeks.

Bevacizumab has anti-proliferative dose-dependent effects on bovine corneal endothelial cells; in addition, it is not cytotoxic at therapeutic

Table 1. General characteristics of the included articles.

No	Author Year Reference	Country	Number of patients	Sex ratio	Age (year) (Mean)	Study design *
1	Oshima 2006 (14)	Japan	5	Male: 3 Female: 2	55.8 (48.6-72)	NCICS
2	Avery 2006 (12)	USA	32	NR [©]	NR	RCS
3	Spaide 2006 (15)	USA	2	Male: 1 Female: 1	68 and 38	CR
4	Minnella 2008 (16)	Italy	10	Male: 6 Female: 4	49.6 (33-65)	PCS
5	Chiang 2008 (2)	Taiwan	50	Male: 37 Female: 13	68 (42-80)	PCS
6	Wu 2008 (17)	Costa Rica [®]	1173	Male: 470 Female: 703	54 (41-89)	RUICS
7	Dastjerdi 2009 (18)	USA	10	Male: 4 Female: 6	46.7 (23-71)	PNC
8	Pe´rez-Rico 2010 (19)	Spain	52	Male: 29 Female: 23	70.5 (61-80)	PCS
9	Torres-Soriano 2012 (13)	Mexico	31	Male: 12 Female: 19	NR	PIUCS
10	Lichtinger 2014 (20)	Canada	10	Male: 3 Female: 7	46 (21-85)	CR

* NCICS: Non-comparative, interventional case series, RCS: Retrospective case series, CR: Case Report, PCS: Prospective case series, RUICS: Retrospective, uncontrolled interventional case series, PNC: Prospective, non-comparative, PIUCS: Prospective, interventional, uncontrolled, clinical study. [®] This study is conducted as a joint research in 7 countries including Mexico, Venezuela, Puerto Rico, Brazil, Peru, Colombia and Costa Rica. [©] NR: Not reported.

concentrations (27). Similarly, no significant effect on cell proliferation was reported in cells treated with bevacizumab in combination with 50 ng/ml of VEGF. Morphological studies of cells showed that there was no significant changes in corneal endothelial cells after the treatment with bevacizumab (27,28). Several studies conducted in vitro and on animal models demonstrated that bevacizumab was a safe and nontoxic agent to human fibroblast and corneal epithelial at pharmacological concentrations (22,29,30).

In vitro studies has confirmed the safety of bevacizumab in various ocular cells, including photoreceptor cells, human optic nerve head astrocytes, human trabecular meshwork cells, rat neurosensory retinal cells, human microvascular

endothelial cells, and human corneal cells (23,24,31). Furthermore, studies suggested that bevacizumab could be considered as a safe and alternative therapeutic strategy for iris rubeosis in neovascular glaucoma. These findings were supported with several studies conducted on both human and animals. Because there are some limited documents reporting the adverse effects of intravitreal bevacizumab injection on corneal endothelial cells, the efficacy and therapeutic value of Avastin is suggested to be evaluated in a well-designed clinical trials.

Conclusion

In sum, the results of this systematic literature review showed that the use of bevacizumab is

Table 2. Variables and methods of assessment in the selected studies.

No	Author Year Reference	Variables	Mean follow-up	Method of assessment	Dose	Main findings
1	Oshima 2006 (14)	VA, IOP	2 months	VA, IOP, RINV	1 mg	No inflammation or complications were observed after intravitreal injection of bevacizumab.
2	Avery 2006 (12)	FA leakage, Snellen visual acuity	11 weeks	VA, FA, OCT	6.2 µg-1.25 mg	Systemic side effects are possible in patients undergoing treatment with intravitreal bevacizumab.
3	Spaide 2006 (15)	VA, FA, ophthalmoscopic examination	1 month	VA, FA	1.25 mg	No short-term safety concerns were observed after intravitreal injection of bevacizumab.
4	Minnella 2008 (16)	Planimetric analysis of new vessels	3 months	FA	1.25 mg	No side-effects were observed on vitreous haemorrhages after intravitreal injection of bevacizumab.
5	Chiang 2008 (2)	CCT, endothelial cell count	6 months	SM	2.5 mg	The intravitreal injection of bevacizumab seemed to have no harmful effects on the corneal endothelium.
6	Wu 2008 (17)	cumulative systemic and ocular adverse events	12 months	SBP, CM	1.25 and 2.5 mg	Bevacizumab appears to be safe and well tolerated.
7	Dastjerdi 2009 (18)	vessel caliber (VC), corneal vessels diameter, invasion area (IA)	6 months	VA, CCT	1.0%	Topical bevacizumab was well-tolerated with no adverse events.
8	Pe´rez-Rico 2010 (19)	endothelial cell density, and the central corneal thickness	6 months	SM	0.5 mg	Intravitreal injections of ranibizumab do not seem to cause substantial changes in the corneal endothelium.
9	Torres-Soriano 2012 (13)	VA, OCT, MEPT	1 month	MEPT	2.5 mg	No short-term cone photoreceptor toxicity was observed after intravitreal bevacizumab.
10	Lichtinger 2014 (20)	endothelial cell counts, morphological changes	6 months	SM	25 mg	Injection of bevacizumab appears to be safe for corneal endothelial cells.

SM: Specular microscopy, VA: Visual acuity, FA: Fluorescein angiography, OCT: Optical coherence tomography, MEPT: Multifocal electro-physiological testing, IOP: Intraocular pressure, RINV: Regression of iris neovascularization, SBP: Systemic blood pressure, CM: Cardiac measurement, CCT: Central corneal thickness.

a safe treatment method with no considerable toxicity to corneal endothelial cells at therapeutic doses.

Acknowledgement

We would like to thank Clinical Research Development Unit of Ghaem Hospital for their assistant in this manuscript.

Conflict of Interest

The authors declare no conflict of interest.

References

1. Los M, Roodhart JM, Voest EE. Target practice: lessons from phase III trials with bevacizumab and vatalanib in the treatment of advanced colorectal cancer. *Oncologist*. 2007;12:443-450.
2. Chiang CC, Chen WL, Lin JM, et al. Effect of bevacizumab on human corneal endothelial cells: a six-month follow-up study. *Am J Ophthalmol*. 2008;146:688-691.
3. Ellis LM. Bevacizumab. *Nat Rev Drug Discov*. 2005;8-9.
4. Shih T, Lindley C. Bevacizumab: an angiogenesis inhibitor for the treatment of solid malignancies. *Clin Ther*. 2006;28:1779-1802.
5. Gunther JB, Altaweel MM. Bevacizumab (Avastin) for the treatment of ocular disease. *Surv Ophthalmol*. 2009;54:372-400
6. Spitzer MS, Yoeruek E, Sierra A, et al. Comparative anti-proliferative and cytotoxic profile of bevacizumab (Avastin), pegaptanib (Macugen) and ranibizumab (Lucentis) on different ocular cells. *Graefes Arch Clin Exp Ophthalmol*. 2007;245:1837-1842.
7. Spitzer MS, Wallenfels-Thilo B, Sierra A, et al. Antiproliferative and cytotoxic properties of bevacizumab on different ocular cells. *Br J Ophthalmol*. 2006;90:1316-1321.
8. Adamis AP, Shima DT. The role of vascular endothelial growth factor in ocular health and disease. *Retina*. 2005;25:111-118.
9. Philipp W, Speicher L, Humpel C. Expression of vascular endothelial growth factor and its receptors in inflamed and vascularized human corneas. *Invest Ophthalmol Vis Sci*. 2000;41:2514-22.

10. Zaki AA, Farid SF. Subconjunctival bevacizumab for corneal neovascularization. *Acta Ophthalmol.* 2010;88:868-871.
11. Liberati A, Altman DG, Tetzlaff J, et al. The PRISMA statement for reporting systematic reviews and meta-analyses of studies that evaluate health care interventions: explanation and elaboration. *Annals Intern Med.* 2009;151:65-94.
12. Avery RL, Pearlman J, Pieramici DJ, et al. Intravitreal bevacizumab (Avastin) in the treatment of proliferative diabetic retinopathy. *Ophthalmology.* 2006;113:1695.1-15.
13. Torres-Soriano ME, Cubas-Lorenzo V, García-Aguirre G, et al. Multifocal electrophysiologic findings after intravitreal bevacizumab (avastin) treatment. *Retina.* 2012;32:972-976.
14. Oshima Y, Sakaguchi H, Gomi F, et al. Regression of iris neovascularization after intravitreal injection of bevacizumab in patients with proliferative diabetic retinopathy. *Am J Ophthalmol.* 2006;142:155-158.
15. Spaide RF, Fisher YL. Intravitreal bevacizumab (Avastin) treatment of proliferative diabetic retinopathy complicated by vitreous hemorrhage. *Retina.* 2006;26:275-278.
16. Minnella AM, Savastano CM, Ziccardi L, et al. Intravitreal bevacizumab (Avastin) treatment of proliferative diabetic retinopathy complicated by vitreous hemorrhage. *Retina.* 2006;26:275-278.
17. Wu L, Martínez-Castellanos MA, Quiroz-Mercado H, et al. Twelve-month safety of intravitreal injections of bevacizumab (Avastin): results of the Pan-American Collaborative Retina Study Group (PACORES). *Graefes Arch Clin Exp Ophthalmol.* 2008;246:81-87.
18. Dastjerdi MH, Al-Arfaj KM, Nallasamy N, et al. Topical bevacizumab in the treatment of corneal neovascularization: results of a prospective, open-label, noncomparative study. *Arch Ophthalmol.* 2009;127:381-389.
19. Pérez-Rico C, Benítez-Herreros J, Castro-Rebollo M, et al. Effect of intravitreal ranibizumab on corneal endothelium in age-related macular degeneration. *Cornea.* 2010;29:849-852.
20. Lichtinger A, Yeung SN, Kim P, et al. Corneal endothelial safety following subconjunctival and intrastromal injection of bevacizumab for corneal neovascularization. *Int Ophthalmol.* 2014;34:597-601.
21. de Moraes CG, Facio AC, Costa JH, et al. Intracameral bevacizumab and mitomycin C Trabeculectomy for eyes with neovascular glaucoma: a case series. *J Ocul Biol Dis Infor.* 2009 31;2:40-46.
22. Shin JP, Lee JW, Sohn BJ, et al. In vivo corneal endothelial safety of intracameral bevacizumab and effect in neovascular glaucoma combined with Ahmed valve implantation. *J Glaucoma.* 2009;18:589-594.
23. Luthra S, Narayanan R, Marques LE, et al. Evaluation of in vitro effects of bevacizumab (avastin) on retinal pigment epithelial, neurosensory retinal, and microvascular endothelial cells. *Retina.* 2006;26:512-518.
24. Kernt M, Welge-Lussen U, Yu A, et al. Bevacizumab is not toxic to human anterior- and posterior-segment cultured cells. *Ophthalmologe.* 2007;104:965-971.
25. Yoeruek E, Ziemssen F, Henke-Fahle S, et al. Safety, penetration and efficacy of topically applied bevacizumab: evaluation of eyedrops in corneal neovascularization after chemical burn. *Acta Ophthalmol.* 2008;86:322-328.
26. Grisanti S, Biester S, Peters S, et al. Intracameral bevacizumab for iris rubeosis. *Am J Ophthalmol.* 2006;142:158-160.
27. Rusovici R, Sakhalkar M, Chalam KV. Evaluation of cytotoxicity of bevacizumab on VEGF-enriched corneal endothelial cells. *Mol Vis.* 2011;17:3339-3346.
28. Park HY, Kim SJ, Lee HB, et al. Effect of intracameral bevacizumab injection on corneal endothelium in rabbits. *Cornea.* 2008;27:1151-1155.
29. Shalam KV, Agarwal S, Brar VS, et al. Evaluation of Cytotoxic Effects of Bevacizumab on Human Corneal Cells. *Cornea.* 2009;28:328-333.
30. Bayar SA, Altinors DD, Kucukerdonmez C, et al. Severe corneal changes following intravitreal injection of bevacizumab. *Ocul Immunol Inflamm.* 2010;18:268-274.
31. Maturi RK, Bleau LA, Wilson DL. Electrophysiologic findings after intravitreal bevacizumab (Avastin) treatment. *Retina.* 2006;26:270-274.