



Diagnostic value of performing endocervical curettage at the time of colposcopy procedure; a systematic review

Shabnam Imannezhad (MD)¹, Alireza Sabzevari (MD)², Ali Rahdari (MD)^{*2}, Mohsen Akhondi (MD)²

¹Department of Gynecology, School of Medicine, Mashhad University of Medical Science, Mashhad, Iran.

²Department of Anesthesiology, School of Medicine, Mashhad University of Medical Sciences, Mashhad, Iran.

ARTICLE INFO

Article type

Systematic review article

Article history

Received: 27 Jan 2015

Revised: 26 Jun 2015

Accepted: 13 Aug 2015

Keywords

Cervical Intraepithelial Neoplasia

Colposcopy

Endocervical Curettage

ABSTRACT

Introduction: The importance of high-grade cervical intraepithelial neoplasia (CIN) as a precursor to invasive cervical cancer suggests a considerable need for accurate screening of the patients for the risk of these lesions. This systematic review aimed to study the diagnostic significance of endocervical curettage (ECC) at the time of colposcopy in the detection of CIN 2, 3, and preinvasive lesions.

Methods: PubMed was searched to obtain the relevant articles based on the following search term: (endocervical curettage OR ECC) AND colposcopy. The most relevant articles were included after studying the title, abstract, and full text of the obtained articles at initial search. Only English language articles published after 1992 with at least 500 patients were included in this study.

Result: Among 300 articles identified by the first search, only seven articles were in line with the purpose of this systematic review. Majority of the included studies were retrospective observational studies.

Conclusion: Performing ECC has higher sensitivity in women older than 40 years and those with unsatisfactory colposcopy results. However exact diagnostic usefulness of ECC at the time of colposcopy needs to be investigated in further studies.

Please cite this paper as:

Imannezhad S, Sabzevari A, Rahdari A, Akhondi M. Diagnostic value of performing endocervical curettage at the time of colposcopy procedure; a systematic review. Rev Clin Med. 2016;3(2):58-62.

Introduction

Due to the importance of high-grade cervical intraepithelial neoplasia (CIN), as a precursor to invasive cervical cancer, it is vital to accurately screen patients for the risk of these lesions.

Based on gynecology guidelines, colposcopy examinations are performed in women with abnormal cervical cytology during screening protocols for cervical cancer to evaluate the cervical histopathology. Colposcopy is associated with pain, bleeding, physical, and mental distress (1).

Endocervical curettage (ECC) which uses circumferential scraping of the endocervical canal

with a curette, reveals the presence of hidden CIN; it is also proposed as a diagnostic method which might increase the accuracy and sensitivity of colposcopy results, especially in older patients (2).

The advantages of using ECC has been a controversial issue for almost 50 years. An evidence-based guideline regarding the performance of ECC at the time of colonoscopy can improve diagnostic strategies in patients with cervical malignancy at different stages.

Some physicians perform both colposcopy and ECC to increase the accuracy of diagnosis and to

***Corresponding author:** Ali Rahdari.

Department of Anesthesiology, School of Medicine, Mashhad University of Medical Science, Mashhad, Iran.

E-mail: rahdaria901@mums.ac.ir

Tel: 09155067902

This is an Open Access article distributed under the terms of the Creative Commons Attribution License (<http://creativecommons.org/licenses/by/3.0>), which permits unrestricted use, distribution, and reproduction in any medium, provided the original work is properly cited.

prevent missing any preinvasive lesions in endocervical canal, even in patients with normal colposcopy results. However, ECC is recommended only for patients with positive colposcopy results; otherwise, it is an unnecessary procedure which is associated with minimal advantages in all patients. Performing ECC is not cost-effective and might be associated with some disadvantages such as difficult pathological interpretation, adequate specimen, and complications such as hypotensive attack, and syncope. According to literature, performing ECC is not recommended for patients with specific features including adolescents, immunocompromised patients, and pregnant women (3).

In this systematic review, we study the advantages of ECC at the time of colposcopy in the diagnosis of high-grade CIN by screening the capability of ECC in detecting dysplastic lesion in women with atypical squamous cells of undetermined significance (ASC-US) that could not be visualized in colposcopy.

Methods

Literature search strategy

PubMed was used as the database for retrieving articles regarding the efficacy of ECC at the time of colposcopy. The following search term was used to obtain articles based on the purpose of this review: (endocervical curettage OR ECC) AND colposcopy. The last search was done on 1 January 2015. Title and abstract of the articles were screened to exclude the irrelevant articles obtained at initial search. Full text of the remaining articles studied for extracting the appropriate data. The reference lists of the included articles were searched to avoid missing any relevant article.

Low-grade intraepithelial lesion (LSIL) and ASC-US were characteristics of patients studied in the included articles. Colposcopy satisfactory was used when entire squamocolumnar junction and the margin of any visible lesion could be visualized with colposcope. Unsatisfactory colposcopy was used when squamocolumnar junction could not be visualized.

Selection criteria

Inclusion criteria were all types of studies which investigated the efficacy of performing ECC during colposcopy-directed biopsy procedure on at least 500 patients who were candidate for cervical excisional biopsy. CIN 2 is regarded as a clinically relevant endpoint and indicator of high risk population that need specific intense treatments. The last systematic review on this topic was conducted in 1992, thus we included only English language articles published after 1992. Exclusion criteria were studies before 1992, and those consist of a sample size of less than 500 patients.

Extracted data

Data regarding the author name, publication year, patients' age, number of lesions detected by colposcopy and ECC were extracted from each article.

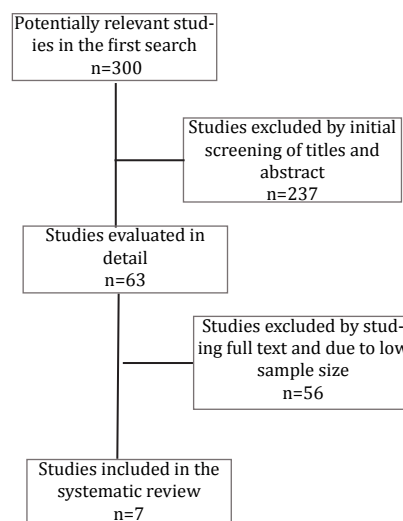
Data synthesis

Results were prepared based on comparing the diagnostic accuracy of ECC compared with colposcopy procedure.

Results

This systematic review consisted of seven articles. The provided flowchart shows the pattern of excluding irrelevant articles to the study purpose (Figure 1).

Figure 1. PRISMA flowchart of the study



Majority of the included studies were retrospective observational studies. Only one randomized trial was conducted on this subject in 2007 by Solomon et al. (2). Data regarding the number of lesions identified by ECC compared with colposcopy in each of the included studies are summarized in Table 1.

Discussion

Several factors can lead to the clinicians' decision for performing ECC, including patients' older age, severe cytological symptoms, and colposcopy results. In one recent study, performing ECC at the time of colposcopy was suggested to be cost-effective and beneficial in reducing the number of cancer-related deaths on women over 50 years old compared to patients less than 50 years old (10). The association between patients' age and the incidence of CIN 2 during the ECC has been studied in some of the included articles (2,4,6,8). According to the studies, the incidence of endocervical canal abnormalities detected through ECC was

Table 1. Quality assessment of the included study

Author Year Reference	Patients	Age (years) CIN 2/total CIN 2	Colposcopy results	ECC ¹ results
Goksedef 2013 (4)	N: 846 for ECC	By ECC 21-30 (3/38) 31-40 (14/38) 41-50 (12/38) >50 (9/38)	Satisfactory col: 419 (49.5%) Normal Col: 238/419 Abnormal: 181/419 Unsatisfactory col: 427 Normal Col: 58.3% Abnormal Col: 41.7%	Only in ECC: CIN ⁴ 2: 18.4% of normal satisfactory Col and normal unsatisfactory Col Normal: 9.6% of abnormal satisfactory Col Normal: 75.4% of abnormal unsatisfactory Col
Gage 2010 (5)	N: 13,115 col and ECC	Satisfactory Col 16-45 (1559/1722) 46-96 (163/1722)	CIN 2 or cancer 1797/13115 only Col	Only in ECC: CIN 2: 0.7% CIN 3: 0.3% Cancer: 0.07%
Solomon 2007 (2)	N: 1,119 col and ECC <40y: 888	<40 (7/312) for ECC >40 (3/23) for ECC	CIN 2 only in Col 212/1119	Only in ECC CIN 2: 10/1119
Gage 2013 (6)	N: 1902 ASC-US/LSIL: 1613 HSIL or worse: 289 Age: 19-29: 626 30-44: 805 >45y: 471	19-29: Biopsy: CIN 1: 478 (34.4) ECC: CIN 1: 96 (26.7) 30-44: Biopsy: CIN 1: 596 (42.9) ECC: CIN 1: 147 (40.9) >45: Biopsy: CIN 1: 315 (22.7) ECC: CIN 1: 116 (32.3)	Normal: 420 (81.9) CIN 1: 1193 (85.9)	Only ECC CIN 1: 5.9%
Massad 2003 (7)	N: 2287 ECC and Col	Women with ECC were older than Col (mean age: 39 versus 33)	---	ECC in 27% of unsatisfactory Col 12% of satisfactory Col 51% of Col CIN 2-3 25.6% of Col CIN negative
Moniak 2000 (8)	N: 2126 ECC and Col	Increased abnormal ECC with increasing age	---	Negative: 1849 (87%) Abnormal: 33% with unsatisfactory Col Abnormal: 10% with satisfactory Col Abnormal: 21% with negative biopsy Abnormal: 42% not performing biopsy
Pretorius 2012 (9)	N: 4635 Col and ECC	CIN 3 by ECC: 25-34: 4/111 (3.6) 34-44: 5/92 (5.4) 45-54: 5/38 (13.2) >55: 3/18 (16.7)	CIN 3: 274 (5.9%) Invasive: 21 (0.5%)	Only in ECC CIN 3: 5.1%

¹ECC: endocervical curettage; ²N: number; ³Col: colposcopy; ⁴CIN: cervical intraepithelial neoplasia.

not significantly different between patients at different aging groups. Solomon et al. proposed that performing ECC would increase the sensitivity of CIN 2 diagnosis in patients ≥40 years old compared with younger patients (7/653). Unlike ECC, biopsy has higher sensitivity in patients younger

than 40 years old compared to older women (2). Based on American Society for Colposcopy and Cervical Pathology, ECC is preferred to be conducted in patients with low-grade cytological and satisfactory colposcopy findings or those with high-grade cytological and unsatisfactory results (11).

The exact technique used for performing ECC and circumferential scraping of the endocervical canal was not described in most of the included studies.

In some studies, unsatisfactory colposcopy results were associated with abnormal ECC results. Therefore, colposcopy was regarded as a predictor of poor ECC outcomes. In these studies, ECC was suggested to be performed in order to increase the diagnostic accuracy of colposcopy, especially in detecting preinvasive and invasive lesions missed by colposcopy. Several studies proposed the ECC as an integral part of colposcopy procedure which should be performed at the time of colposcopy to increase the accuracy and sensitivity of the results; these studies could not be included in our systematic review due to their low sample size (12-15). In the study of Moniak et al., ECC led to the detection of the diseased missed through routine colposcopy and biopsy (8).

A previous systematic review and meta-analysis performed in 1992 investigated the association of ECC with the diagnostic accuracy of colposcopy procedure. In this regard, they suggested limit clinical efficacy of ECC implication at the time of colposcopy. They revealed positive results of ECC in 31% patients with unsatisfactory colposcopies. It was also proposed that the diagnostic accuracy of satisfactory colposcopy was not dependent on ECC. According to the results obtained through that study, applying ECC increased the diagnostic rate of invasive carcinoma lesions; however, this increased diagnostic accuracy was not significantly important (16).

Performing ECC at the time of colonoscopy is a debating subject which has not been studied in large clinical trials or prospective studies, and there is not enough evidence regarding the value of ECC in the detection of CIN or invasive lesions in patients with satisfactory colposcopy results.

In the following studies, unsatisfactory colposcopy results could not be considered as predictive factor of poor ECC outcomes (7,17,18). This means that ECC cannot significantly increase the accuracy of colposcopy and it is not significantly related with the increased detection rate of invasive lesions.

In the study of Massad and Collins, the exact data regarding the colposcopy results could not be extracted, however, omitting the ECC procedure in patients with satisfactory colposcopy or normal colposcopy impression did not resulted in missing patients with cancer. According to their study, ECC findings led to the alternation of the treatments in only 105 out of 2287 patients on colposcopy (4.6%). This was higher than the obtained result by Solomon et al. that revealed 3% higher sensitivity of ECC in patients under colposcopy. The authors revealed a positive relation between ad-

vanced age and positive results of ECC (2,7).

According to studies, difference between two methods results were not statistically significant, however ECC could reveal the presence of high grade endocervical dysplasia in women with satisfactory colposcopy. Thus, it is proposed that ECC is associated with the identification of small number of patients with high grade endocervical dysplasia (CIN 2-3) in patients with satisfactory colposcopy results (4,6,17,19). Results obtained by these mentioned studies came to an agreement that performing ECC as a routine procedure was not necessary for all patients and it would better to be used only in patients with unsatisfactory colposcopy results who are suspected for high grade lesion on colposcopy findings. Moreover, it has been proposed that ECC was associated with lower usefulness in revealing additional CIN 2 or worse lesions in women with ASC-US or LSIL smear results, and normal colposcopy findings.

According to the studies, ECC is a blind procedure which is associated with some drawbacks in patients, including patients' distress, low quality, inadequate sample, and the possibility of contamination with ectocervical lesion (20).

Conclusion

Performing ECC in patients with ASC-US, AGUS or LSIL cytology, younger than 45 years old, and those with satisfactory colposcopy results would have the lowest beneficial effects, compared with those older than 45 years old with unsatisfactory outcomes. Applying ECC in patients with unsatisfactory colposcopy would increase the diagnostic accuracy of invasive disease, however there is still debate regarding the value of performing ECC at the time of colposcopy which needs further studies.

Acknowledgement

We would like to thank Clinical Research Development Unit of Ghaem Hospital for their assistant in this manuscript.

Conflict of Interest

The authors declare no conflict of interest.

References

1. Takeda T, Wong TF, Adachi T, et al. Guidelines for office gynecology in Japan: Japan Society of Obstetrics and Gynecology and Japan Association of Obstetricians and Gynecologists 2011 edition. *J Obstet Gynaecol Res.* 2012;38:615-631.
2. Solomon D, Stoler M, Jeronimo J, et al. Diagnostic utility of endocervical curettage in women undergoing colposcopy for equivocal or low-grade cytologic abnormalities. *Obstet Gynecol.* 2007;110:288-295.
3. Driggers RW, Zahn CM. To ECC or not to ECC: the question remains. *Obstet Gynecol Clin North Am.* 2008;35:583-597.
4. Goksedef BP, Akbayir O, Numanoglu C, et al. Evaluation of endocervical canal in women with minimal cervi-

- cal cytological abnormalities. *J Low Genit Tract Dis.* 2013;17:261-266.
5. Gage JC, Duggan MA, Nation JG, et al. Detection of cervical cancer and its precursors by endocervical curettage in 13,115 colposcopically guided biopsy examinations. *Am J Obstet Gynecol.* 2010;203:481.e1-9.
 6. Gage JC, Duggan MA, Nation JG, et al. Comparative risk of high-grade histopathology diagnosis after a CIN 1 finding in endocervical curettage versus cervical biopsy. *J Low Genit Tract Dis.* 2013;17:137-141.
 7. Massad LS, Collins YC. Using history and colposcopy to select women for endocervical curettage. Results from 2,287 cases. *J Reprod Med.* 2003;48:1-6.
 8. Moniak CW, Kutzner S, Adam E, et al. Endocervical curettage in evaluating abnormal cervical cytology. *J Reprod Med.* 2000;45:285-292.
 9. Pretorius RG, Belinson JL, Azizi F, et al. Utility of random cervical biopsy and endocervical curettage in a low-risk population. *J Low Genit Tract Dis.* 2012;16:333-338.
 10. Shepherd JP, Guido R, Lowder JL. Should endocervical curettage routinely be performed at the time of colposcopy? A cost-effectiveness analysis. *J Low Genit Tract Dis.* 2014;18:101-108.
 11. Wright TC Jr1, Massad LS, Dunton CJ, et al. 2006 consensus guidelines for the management of women with abnormal cervical cancer screening tests. *Am J Obstet Gynecol.* 2007;197:346-355.
 12. Saltzman DH, Evans MI, Warsof SL, et al. Endocervical curettage as a routine part of colposcopic examinations for abnormal cervical cytology. *J Reprod Med.* 1985;30:871-873.
 13. Puntachai P, Darojn D, Chumworathayi B, et al. Comparing visual inspection with acetic acid plus random cervical biopsy plus endocervical curettage to colposcopic directed biopsy plus endocervical curettage in detecting cervical lesions in low-resource settings. *Asian Pac J Cancer Prev.* 2011;12:2665-2668.
 14. Pretorius RG, Zhang WH, Belinson JL, et al. Colposcopically directed biopsy, random cervical biopsy, and endocervical curettage in the diagnosis of cervical intraepithelial neoplasia II or worse. *Am J Obstet Gynecol.* 2004;191:430-434.
 15. Hatch KD, Shingleton HM, Orr JW Jr, et al. Role of endocervical curettage in colposcopy. *Obstet Gynecol.* 1985;65:403-408.
 16. Helmerhorst TJ. Clinical significance of endocervical curettage as part of colposcopic evaluation. A review. *Int J Gynecol Cancer.* 1992;2:256-262.
 17. Poomtavorn Y, Suwannarurk K, Thaweekul Y, et al. Diagnostic value of endocervical curettage for detecting dysplastic lesions in women with atypical squamous cells of undetermined significance (ASC-US) and low grade squamous intraepithelial lesion (LSIL) Papanicolaou smears. *Asian Pac J Cancer Prev.* 2014;15:3461-3464.
 18. Irvin W, Flora S, Andersen W, et al. Endocervical curettage. Does it contribute to the management of patients with abnormal cervical cytology? *J Reprod Med.* 2004;49:1-7.
 19. Nakamura Y, Matsumoto K, Satoh T, et al. Optimizing biopsy procedures during colposcopy for women with abnormal cervical cancer screening results: a multicenter prospective study. *Int J Clin Oncol.* 2015;20:579-585.
 20. Gibson CA, Trask CE, House P, et al. Endocervical sampling: a comparison of endocervical brush, endocervical curette, and combined brush with curette techniques. *J Low Genit Tract Dis.* 2001;5:1-6.