

## Evaluation of the concavity depth and inclination in jaws using CBCT

Mehrdad Panjnoush<sup>1</sup>, Nakisa Eil<sup>2</sup>, Yasaman Kheirandish<sup>1✉</sup>,  
Niloufar Mofidi<sup>3</sup>, Ahmad Reza Shamshiri<sup>4</sup>

1. Assistant Professor, Department of Oral and Maxillofacial Radiology, School of Dentistry, Tehran University of Medical Sciences, Tehran, Iran.
2. Assistant Professor, Department of Oral and Maxillofacial Radiology, School of Dentistry, Zahedan University of medical sciences, Zahedan, Iran.
3. Assistant Professor, Department of Oral and Maxillofacial Radiology, School of Dentistry, Kurdistan University of Medical Sciences, Sanandaj, Iran.
4. Assistant Professor, Department of Community Oral Health, Dental Research Center, Dentistry Research Institute, School of Dentistry, Tehran University of Medical Sciences, Tehran, Iran.

✉Corresponding Author: Yasaman Kheirandish, School of Dentistry, Tehran University of Medical Sciences, Tehran, Iran.

Email: kheirandish@sina.tums.ac.ir

Tel: +982188351154

Received: 23 Jul 2016 Accepted: 10 Sept 2016

### Abstract

**Introduction:** Nowadays, using implants as a choice in patient's treatment plans has become popular. The aim of this study was to determine the prevalence of mandibular lingual and maxillary buccal concavity, mean concavity depth and angle and its relation to age and gender.

**Materials & Methods:** In 200 CBCT, concavity depth and angle were measured in 2 mm superior to the inferior alveolar canal in the mandibular first molar area and in 1 mm distance from nasal floor in the midpoint region of maxillary lateral incisor and canine. Concavity depth and angle relationships with age and gender have been evaluated using Spearman Correlation and a t-test.

**Results:** Mean and standard deviation of lingual concavity, concavity angle and ridge angle in mandible were  $1.3 \pm 1.54$  mm,  $15.45 \pm 16.19$  and  $10.13 \pm 6.1$ . Mean and standard deviation of buccal concavity and concavity angle in maxilla were  $5.35 \pm 1.03$  mm and  $30.6 \pm 5.75$ . Mandibular concavity depth was zero in 44% of subjects and more than zero in 56%. Results were more than 3 mm in maxillary samples. There was a linear relationship between mandibular concavity depth and age equaled to  $-0.27$ ,  $p=0.007$  and for mandibular concavity angle and age equaled to  $-0.25$ ,  $p=0.01$ . There was no significant relationship between mandibular ridge angle and age. In maxilla, there was no linear relationship between age and gender with any other variables.

**Conclusion:** It is necessary to provide more information on these regions' anatomy using CBCT cross sections before implant placement.

**Keywords:** Cone Beam Computed Tomography, Dental implants, Anatomy, Mandible

**Citation for article:** Panjnoush M, Eil N, Kheirandish Y, Mofidi N, Shamshiri AR. Evaluation of the concavity depth and inclination in jaws using CBCT. Caspian J Dent Res 2016;5: 17-23.

## بررسی میزان عمق و شیب تفر در فکین با استفاده از CBCT

مهرداد پنجنوش، نکسا ایل، یا سمن خیراندیش<sup>\*</sup>، نیلوفر مفیدی، احمد رضا شمشیری

### چکیده

**مقدمه:** امروزه استفاده از ایمپلنت در درمان بیماران بسیار مرسوم شده است. هدف از این مطالعه بررسی شیوع افراد دارای تفر در لینگوال مندیبل و باکال ماگزایلا و میانگین اندازه و زاویه و همچنین رابطه آن با سن و جنس افراد بود.

**مواد و روش ها:** در ۲۰۰ فایل cbct عمق و زاویه تفر در ۲ میلی متر بالاتر از کانال الوئولار تحتانی در ناحیه دندان مولر مندیبل و در فاصله ۱ میلی متری از کف بینی در ناحیه midpoint دندان لترال و کانین در ماگزایلا به دست آمد. رابطه عمق و زاویه تفر با سن و جنس به ترتیب توسط t-test و spearman correlation محاسبه شد.

**یافته ها:** میانگین و انحراف معیار تفر لینگوال، زاویه تفر و زاویه ریج در مندیبل به ترتیب  $15/45 \pm 16/19^\circ$  و  $1/13 \pm 1/54$  mm و  $10/13 \pm 6/1^\circ$  و میانگین و انحراف معیار تفر باکال و زاویه تفر در ماگزایلا به ترتیب  $5/35 \pm 10/3$  mm و  $30/6 \pm 5/75^\circ$  به دست آمد. در مندیبل عمق تفر در ۴۴ درصد موارد صفر و ۵۶ در صد بیشتر از صفر بود. در ماگزایلا تفر در تمامی موارد بالای ۱ mm گزارش شد. بین سن افراد و تفر مندیبل رابطه خطی  $p = 0/007$  و بین سن و زاویه تفر لینگوالی مندیبل رابطه خطی  $p = 0/01$  برقرار است. رابطه بین سن و زاویه ریج مندیبل معنی دار نیست. در ماگزایلا رابطه خطی بین سن و جنس و هیچ کدام از متغیرها وجود ندارد.

**نتیجه گیری:** جمع آوری اطلاعات بیشتر از آناتومی این نواحی با استفاده از مقاطع CBCT قبل از قرار دادن ایمپلنت لازم به نظر می رسد.

**واژگان کلیدی:** توموگرافی کامپیوتری با پرتو مخروطی، ایمپلنت، آناتومی، فک پایین

### Introduction

Nowadays, proper diagnosis and treatment plan of most implant surgeries could be achieved without any difficulties and patient's function and esthetic would be provided after osteointegration. [1] Bone perforations during implant placement, is one of the unavoidable complications which can damage critical structures. [2] Inflammation, infection and implant loss are other consequences of bone perforation. [3] Controlling the ridge angle, during implant placement, in practice or even in radiographic assessment, is a difficult and time consuming process for surgeon. [4] Although different methods are used to show different anatomic regions such as alveolar ridge palpation using osteometer and diagnostic casts, they are not very efficient in special sites for instance posterior mandible as mylohyoid muscle prevents the proper assessment of that area. [5]

Most of these perforations occur in submandibular fossa region. Hofschneider et al. and Bavitz et al. mentioned that sublingual and submental arteries might

be very close to lingual cortical plate in mouth floor. [6,7] Dehiscence and fenestration are defects resulted from wrong direction of implants in these regions which lead to implant failure. [3]

Presence of undercuts in anterior aspect of maxilla (lateral fossa), is a permanent danger for buccal plate perforations. Due to high probability of lateral missing and canine impactions, many implant surgeries are performed in this region. In a study, Zarb evaluated the morphology and contour of mandible, he did not assess buccolingual dimensions and concavities. [8] Quirynen et al. have conducted a cross-sectional study on interforaminal morphology and presence of lingual concavity. [9] Chan et al. measured the degree of this concavity at the first molar region. In this study, according to ridge morphology, subjects were classified into three types of C (convex), P (parallel) and U (undercut). [4] Parnia et al. measured mean submandibular gland fossa depth. [5] Some authors also

evaluated posterior mandibular lingual concavity.<sup>[10-15]</sup> In order to be informed about ridge concavities and select a proper size fixture, having an accurate radiograph as a guide for the surgeon is critical. Using Spiral/Helical CT helps to obtain more data for three dimensional images<sup>[12]</sup> although CT radiation dose is relatively high and it costs too much for the patient. CBCT is a recent imaging modality and image acquisition time varies from 10 to 40 seconds. Besides, CBCT resolution is higher than CT theoretically and radiation dose is obviously lower than multislice CT.<sup>[13]</sup>

The objective of this retrospective study was to determine the prevalence of mandibular lingual and maxillary buccal concavity and also to evaluate the mean concavity's depth, angle and its relationship with age and gender using CBCT.

## Materials&Methods

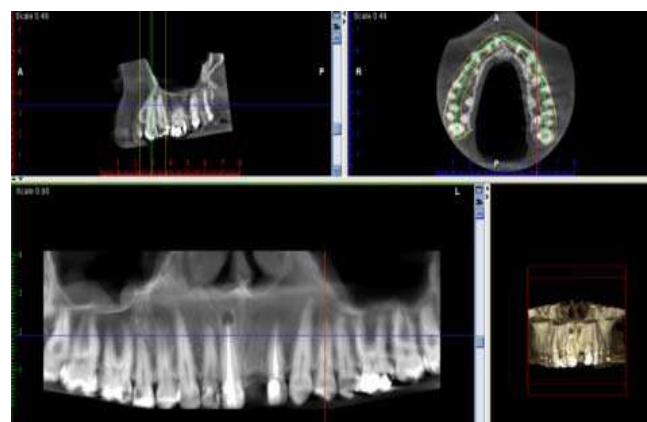
Based on a cross-sectional study, this research was performed using 200 CBCT samples of patients referred to a private radiology center. Areas of attention in this study were mandibular first molar and midpoint of maxillary lateral and canine. Concerning the fact that a minimum implant dimension as a guide should be 3×8 mm, the inclusion criteria were as follows:

1. Minimum mandibular bone height 10 mm higher than superior border of inferior alveolar canal
2. Minimum maxillary bone height 10 mm from sinus floor or nasal fossa floor
3. Minimum maxillary and mandibular width 3.5 mm. (2 mm apical to alveolar ridge crest)
4. Minimum age of 18 years due to the complete development of jaws

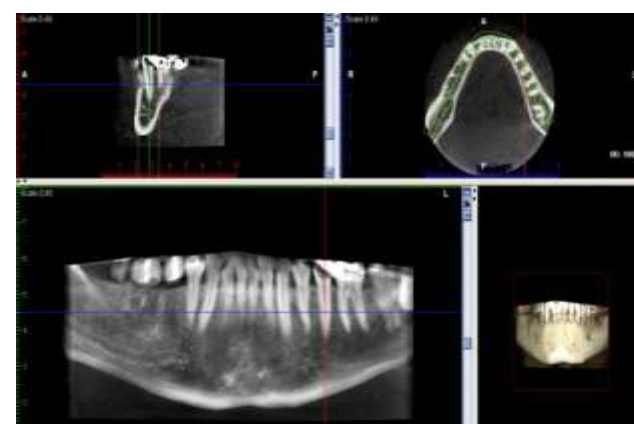
All samples had been prepared by Planmeca Promax 3D CBCT (Helsinki, Finland). Exposure parameters were current (mA) =12, voltage (KVp) =84, time(S) =12 in high resolution mode. All measurements were assessed by a single operator. Software used in this study was PLANMECA ROMEXIS, 2.3.1 version. Regions of interest were occlusal plan to inferior border in mandible and occlusal plan to nasal fossa floor in maxilla.

At First, brightness, contrasts were tuned, then maxillary and mandibular plan angle related to horizontal line in sagittal and coronal planes were corrected. In the next stage, in panoramic view, adjacent teeth's position was located along the perpendicular line as far as it was possible in order to correct the

mandibular and maxillary plan angle related to the horizontal line.

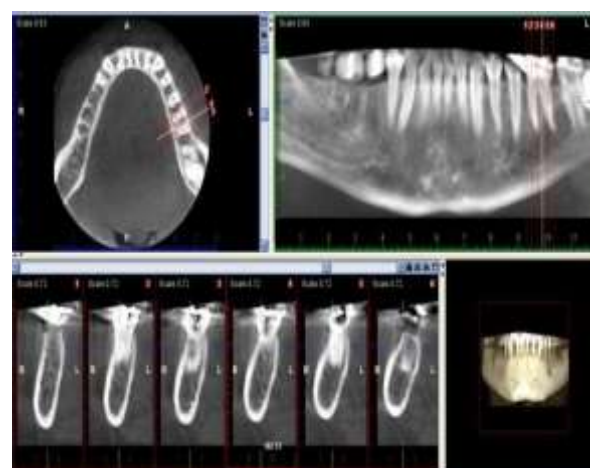


**Figure 1. Adjusting maxillary plane angle in relation to horizontal line**



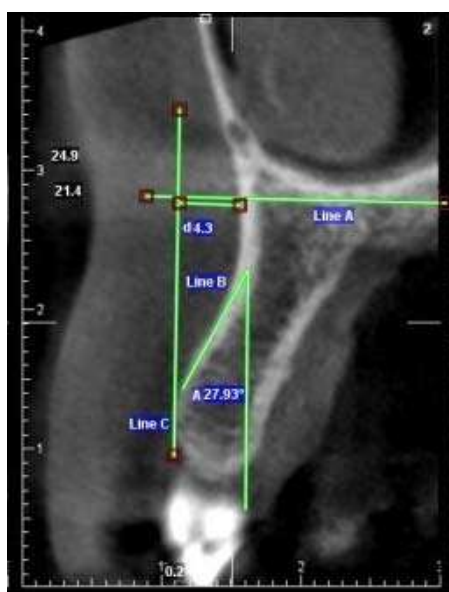
**Figure 2. Adjusting mandibular plane angle in relation to horizontal line**

Next, in mandible, the section crossed the midpoint of first molar area would be selected.(figure 3).

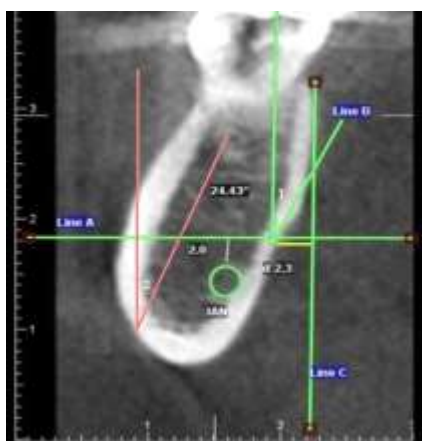


**Figure 3. Choose proper cross-sectional view in the selected area**

The location of inferior alveolar canal was defined in mandible and a horizontal line placed 2mm superior to the canal was specified on the section (line A). In maxilla, a section located in midpoint of lateral incisor and canine was selected and line A was located in 1mm distance to the sinus floor. Line B is perpendicular to line A. Point A is where lingual plate meets line A in mandible. In maxilla, point A is where buccal plate meets line A (figure4, 5).



**Figure 4. Two dimensional cross-sectional view of central and lateral teeth in midpoint area**



**Figure 5. Two dimensional cross-sectional view of first molar tooth in midpoint area.**

The angle between line B and a tangent line passes point A is considered as concavity angle. The concavity depth is the horizontal distance between point A and line C (a line that is perpendicular to line A, from the most prominent point of lingual and buccal surfaces).

Regarding mandibular concavity depth, subjects were classified into three types of I (lower than 2 mm), II (2-3 mm) and III (more than 3 mm) and frequency of each group was determined.<sup>[5]</sup>

Following consultation with maxillofacial surgeons who believe that depth in lateral fossa region is remarkable, we conducted a pilot study on 20 cases and measured concavity depth and then classified it into three groups in order to classify maxillary concavity depth. This classification in maxilla was as follows; type I (lower than 3 mm), II (3-5 mm) and III (more than 5 mm). Then the relationship of concavity depth and angle with age and gender was calculated. Measurements of concavity angle and depth are similar to Chan et al. study.<sup>[4]</sup>

To assess operator's reliability, 20 samples were randomly selected. All variables were determined twice. The interval between two evaluations was two weeks and the order of images was changed in a way not similar to the last time. Degree of reliability was determined using Interclass correlation coefficient (ICC) and SPSS software.

Regarding to the objectives of this study, data analysis was performed using SPSS 16 and descriptive statistics (Mean and standard deviation measurement for quantitative data). In order to assess the relationship between age and variables, Spearman Correlation was used. A T-Test was applied to evaluate the relationship between gender and other variables. P-value=0.05 was considered as significant level.

## Results

200 CBCT samples were evaluated (100 in maxilla and 100 in mandible). Mandibular samples were belonged to 52 females and 48 males and maxillary samples were 50 for both genders. Mean age of study subjects was  $50.8 \pm 12.9$  for mandibular cases and  $47.5 \pm 11.3$  for maxillary ones.

The results of evaluating the variables are as shown in table 1.

According to mandibular ridge classification, 68% of subjects were included in type I (less than 2 mm), 20% in type II (2-3 mm) and 12% in type III (more than 2 mm). These results for maxillary ridge classification were as follows: 0% were in type I (less than 3 mm), 45% in type II (3-5 mm) and 55% in type III (more than 5 mm). Mandibular concavity angle was zero in 44% of subjects and more than zero in 56%. Mean



concavity depth, was  $2.32 \pm 1.36$ . The results for maxillary concavities were more than 3 mm in all cases. There is a linear relationship of -0.27 between mandibular concavity and age ( $p=0.007$ ). For mandibular lingual concavity angle and age, this linear relationship equals to  $-0.25(p=0.01)$ . No significant relationship was found between mandibular ridge angle and age ( $-0.14$ ,  $P=0.18$ ). There was no linear relationship between age and concavity depth

(Spearman correlation=  $-0.03$ ,  $p=0.81$ ) and between age and concavity angle (Spearman Correlation =  $-0.07$ ,  $p=0.47$ ) in maxilla. None of the variables, including concavity depth ( $p=0.55$ ), concavity angle ( $p=0.85$ ) and ridge angle ( $p=0.7$ ), in maxilla and mandible had a relationship with gender.

Intraobserver reliability (ICC) was calculated and the results were 99.4 for concavity depth, 99.8 for concavity angle and 99.8 for ridge angle.

**Table 1: Mean and standard deviation of concavity depth, concavity angle and ridge angle of mandible and maxilla of both genders.**

	Male(n=48)	Female(n=52)	Total(n=100)	P value
	Mean±SD	Mean±SD	Mean±SD	
<b>Mandible</b>				
Concavity depth (mm)	$1.40 \pm 1.66$	$1.20 \pm 1.40$	$1.30 \pm 1.54$	0.52
Concavity angle (°)	$15.10 \pm 17.00$	$15.70 \pm 15.45$	$15.45 \pm 16.19$	0.85
Ridge angle (°)	$10.37 \pm 6.10$	$9.90 \pm 6.20$	$10.13 \pm 6.10$	0.70
<b>Maxilla</b>				
Concavity depth (mm)	$5.35 \pm 1.05$	$5.33 \pm 1.01$	$5.35 \pm 1.03$	0.92
Concavity angle (°)	$29.90 \pm 4.97$	$31.30 \pm 6.39$	$30.60 \pm 5.75$	0.20

SD=standard deviation

## Discussion

Mandibular ridge angle was measured in this study. In addition to ridge height and width, ridge angle is one of the other important factors to be considered in implant placement and it definitely helps to direct the drill properly during drilling osteotomy.<sup>[5]</sup>

In this study, mean mandibular lingual concavity depth was  $1.3 \pm 1.54$  mm, which was lower than the results of Chan et al. study that was 2.4 mm.

56% of subjects in present study showed mandibular lingual concavity depth more than zero, which was lower than Chan et al. study (66%) and Nickenig et al. (68%).<sup>[4,14]</sup> In Chan et al. article, subjects were classified into three types C (convex), P (parallel), U (undercut) according to ridge morphology, which was 66% in U type group, whereas U type group was not the only group which had the risk of possible perforations. P type ridge that had a significant angle might be considered as a U type one. Therefore, this morphologic classification had not been used in this current study. Mean concavity depth in 56% of subjects was  $2.32 \pm 1.36$  which was consistent with the studies of Chan et al. and Kamburoğlu et al.<sup>[4, 15]</sup>

In a study performed by Watanabe et al., 36-39% of Japanese subjects had mandibular lingual concavity which was less than the results of current study (56%).

In Braut et al. study, concavity prevalence was 38.93% but in these two studies, mandibular lingual concavity depth was not calculated.<sup>[11]</sup>

In addition, Parnia et al. studied on Iranian subjects and they found that concavity prevalence and its mean were 80%,  $2.6 \pm 0.85$  mm which was more than that in the current study. The method of concavity measurement was different and this different measurement method led to different results compared to current study. Since most of implant surgeries are done about 2mm above the alveolar canal, being aware of fossa depth in the areas lower than alveolar nerve canal limits is not important in implant surgeries.<sup>[5]</sup>

The Prevalence of three defined types (I,II,III) in this study (lower than 2 mm, between 2mm and 3 mm, more than 3 mm) was 68%, 20% and 12%, respectively, which is inconsistent with the results of Parnia et al. study (20%, 52%, 28%). Using various measurement methods are the reasons of this difference.

In addition, mean mandibular lingual concavity angle was  $15.45 \pm 16.19$  with the range of 0-60, which was lower than the findings of Chan et al. study (32.3 degrees). Mandibular lingual concavity angle has not been measured in previous articles. Mean mandibular ridge angle was  $10.13 \pm 6.1$  degrees which has not been

measured in reference articles and is a proper guide in implant drilling. Different results can be explained by four reasons the first one is difference in races (Japanese in Watanabe et al. study<sup>[10]</sup> and African Americans in Chan et al. study<sup>[4]</sup>, the second was presence or absence of teeth (people with dentition in Watanabe et al. study and edentulous patients in Chan et al. study), the third reason is different types of imaging modalities (Medical CT scan in Parina et al. study<sup>[5]</sup>) and the last reason can be different measurement methods. However, all studies have shown the significant number of lingual concavity in mandible of subjects.

Mean concavity depth and angle of midpoint region of maxillary lateral and canine were  $5.35 \pm 1.03$  mm, which was more than that in Zhang et al. study  $30.60 \pm 5.75$  degrees.<sup>[16]</sup> Moreover, the concavity angle in this region related closely to the ridge angle. Different measurement methods are the reasons of this difference. With concern to people classification in 3 groups of I (lower than 3 mm), II (3 to 5mm) and III (more than 5 mm) the results were 0%, 45% and 55%. These results indicated that the concavity depth and angle in maxilla were significant in all subjects and implant placement in this region must be carefully performed. There were no similar study, which reported depth and angle in anterior maxillary region and considering the importance of these regions, especially in patients who suffer from ridge resorption with exposed labial undercuts, more assessment and more studies are necessary.

The relationship among age and concavity depth and angle was reported -0.27 and -0.25, respectively and it showed that mandibular lingual concavity depth and angle decrease with aging process. Although as ridge resorption progress, these undercuts become closer to the ridge surface. These results are inconsistent with Parnia et al. study in which no relationships were found between lingual concavity parameters and age. Nevertheless, the relationship between mandibular ridge angle and age was not significant in this study. In addition, no significant relationships were found between concavity depth and its angle with age in maxilla. In addition, there were no significant relationships among gender and concavity depth, angle and ridge angle in mandible and also among gender and concavity depth and angle in maxilla. These results are similar to those of Parnia et al and Quirynen et al. and indicate that being either male or female has no effects on discussed parameters.<sup>[5, 9]</sup>

## Conclusion

It seems that it is necessary to provide more information of these regions anatomy using CBCT cross sections before implant placement.

## Acknowledgments

Hereby, the cooperation of all the staff of private radiology center is appreciated.

**Conflict of interest:** We declare no conflict of interest.

## Authors' Contributions

The study was designed by Mehrdad Panjnoush. The study data were collected by Nakisa Eila. Analysis and interpretation of data, drafting of the manuscript, and critical revision of the manuscript for important intellectual content were pre-formed by Mehrdad Panjnoush, Nakisa Eil, Yasaman kheirandish, Ahmad Reza Shamshiri and Niloufar Mofidi. Study supervision was performed by Mehrdad Panjnoush.

## References

1. White SC, Pharoah MJ, editors. Oral radiology: principles and interpretation. 7<sup>th</sup> ed. St. Louis, Missouri: Elsevier; 2014. p.597-611.
2. Givol N, Chaushu G, Halamish-Shani T, Taicher S. Emergency tracheostomy following life-threatening hemorrhage in the floor of the mouth during immediate implant placement in the mandibular canine region. J Periodontol 2000; 71:1893-5.
3. Annibali S, Ripari M, La Monaca G, Tonoli F, Cristalli MP. Local accidents in dental implant surgery: prevention and treatment. Int J Periodontics Restorative Dent 2009; 29:325-31.
4. Chan HL, Brooks SL, Fu JH, Yeh CY, Rudek I, Wang HL. Cross sectional analysis of the mandibular lingual concavity using cone beam computed tomography. Clin Oral Implants Res 2011; 22:201-6.
5. Parnia F, Fard EM, Mahboub F, Hafezeqoran A, Gavvani FE. Tomographic volume evaluation of submandibular fossa in patients requiring dental implants. Oral Surg Oral Med Oral Pathol Oral Radiol Endod 2010; 109:e32-6.
6. Hofschneider U, Tepper G, Gahleitner A, Ulm C. Assessment of the blood supply to the mental region

- for reduction of bleeding complications during implant surgery in the interforaminal region . *Int J Oral Maxillofac Implants* 1999;14:379-83.
7. Bavitz JB, Harn SD, Homze EJ. Arterial supply to the floor of the mouth and lingual gingiva. *Oral Surg Oral Med Oral Pathol* 1994;77:232-5.
  8. Zarb G. The promise of osseointegration: two decades later. *Clin Implant Dent Relat Res* 2002;4:57-9.
  9. Quirynen M, Mraiwa N, Van Steenberghe D, Jacobs R. Morphology and dimensions of the mandibular jaw bone in the interforaminal region in patients requiring implants in the distal areas. *Clin Oral Implants Res* 2003;14:280-5.
  10. Watanabe H, Mohammad Abdul M, Kurabayashi T, Aoki H. Mandible size and morphology determined with CT on a premise of dental implant operation. *Surg Radiol Anat* 2010;32:343-9.
  11. Braut V, Bornstein MM, Lauber R, Buser D. Bone dimensions in the posterior mandible: a retrospective radiographic study using cone beam computed tomography. Part 1--analysis of dentate sites . *Int J Periodontics Restorative Dent* 2012;32:175-84.
  12. Kawamata A, Ariji Y, Langlais RP. Three-dimensional computed tomography imaging in dentistry . *Dent Clin North Am* 2000;44:395-410.
  13. Naitoh M, Hirukawa A, Katsumata A, Ariji E. Evaluation of voxel values in mandibular cancellous bone: relationship between cone beam computed tomography and multislice helical computed tomography . *Clin Oral Implants Res* 2009;20:503-6.
  14. Nickenig HJ, Wichmann M, Eitner S, Zöller JE, Kreppel M. Lingual concavities in the mandible: a morphological study using cross-sectional analysis determined by CBCT. *J Craniomaxillofac Surg* 2015 ;43:254-9.
  15. Kamburoğlu K, Acar B, Yüksel S, Paksoy CS. CBCT quantitative evaluation of mandibular lingual concavities in dental implant patients. *Surg Radiol Anat* 2015 ;37:1209-15.
  16. Zhang W, Skrypczak A, Weltman R. Anterior maxilla alveolar ridge dimension and morphology measurement by cone beam computerized tomography (CBCT) for immediate implant treatment planning. *BMC Oral Health* 2015;15:65.