

Copyright © 2016 by Academic Publishing House *Researcher*



Published in the Russian Federation
European Journal of Medicine. Series B
Has been issued since 2014.
ISSN: 2409-6296
E-ISSN: 2413-7464
Vol. 7, Is. 3, pp. 70-75, 2016

DOI: 10.13187/ejm.s.b.2016.7.70
www.ejournal27.com



Articles and Statements

Interim Restoration for Endodontically Treated Tooth Using Fiber-Reinforced Composite: A Case Report

¹ Maricar Joy T. Andres

² Pearly P. Lim

³ Aleriza Marya L. Trias

¹⁻³ School of Dentistry, Centro Escolar University, Philippines

¹ D.M.D., PhD

E-mail: maricarjoyandres@yahoo.com

² D.M.D., PhD

E-mail: pplim@ceu.edu.ph

³ D.M.D., M.S.

E-mail: amltriasdmd@yahoo.com

Abstract

The best restoration for an endodontically treated tooth has long been debated on by dental practitioners and is considered an essential part of restorative practice. Tooth fracture following root canal therapy is a concern for patients and dentists alike. Recent advances in Dentistry have left dentists with a variety of treatment options which can be tailored to the needs of the patient. Interim restoration of an endodontically treated tooth using fiber-reinforced composite (FRC) is a suitable alternative to conventional restorations because it greatly contributes to the strength and resistance of a tooth. Shivanna and Gopeshetti (2012) concluded in their study that composite restorations reinforced with polyethylene fibers showed increased fracture resistance of root filled teeth and had favorable fracture lines. This paper presents the promising use of the fiber-reinforced composite to treat an endodontically treated mandibular permanent first molar which was completed in one appointment. This technique offers a cost-efficient alternative which does not compromise esthetics and function of the tooth.

Keywords: fiber-reinforced composite, fracture resistance, interim restoration, endodontically treated tooth.

1. Introduction

There are various opinions of dental practitioners on the restoration of an endodontically treated tooth. Various techniques have been proposed for different problems involving this treatment. More so, this continues to be a point of research and discussion by professional and has become a basis for the manufacturers of dental materials to come up with products that respond to the different needs associated with the procedure. Factors that can affect each dental case presented by the patient can be of number. According to the American Association of Endodontists' selected list of local and systemic factors to consider in treatment planning, restorability of the tooth should be taken into account (Hargreaves, 2007). Upon the completion of root canal

treatment, posterior tooth may have been weakened due to the loss of tooth structure. A tooth then requires further treatment to restore function as well as aesthetics. At this point, if a patient withdraws consent, it is mainly due to the time factor and cost. The introduction of fiber-reinforced composite paved a new way in the field of Dentistry. One of the early definitions of fiber-reinforced composite restorations is that it is a resin-based restoration containing fibres aimed at enhancing their physical properties. (Butterworth C, 2003) The capacity of fiber-reinforced composites to strengthen weakened tooth structure is the highlight for practitioners restoring an endodontically treated tooth. With the advent of this material, an interim restoration of the endodontically treated tooth makes a viable option.

This paper presents the promising use of the fiber-reinforced composite (FRC) to treat an endodontically treated mandibular permanent first molar.

2. Discussion

Clinical Report

A 23-year-old female patient presented to the dental clinic with a chief complaint of caries on the cuspal areas of the mandibular permanent first molar (Figure 1). The opposing teeth had no caries. The patient was advised to receive a porcelain onlay but refused the treatment when given the time frame for the treatment. This was due to the reason that the patient was set to leave the country the following week and will be coming back in 2 months' time. The patient had the tooth endodontically treated in another dental office four (4) months ago and expressed her loss of confidence in masticating on that area. Given the situation, the option of having an interim restoration using fiber-reinforced composite was recommended and the patient readily consented. The treatment was completed in one day.

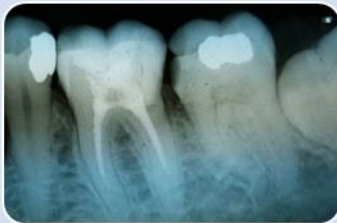

Figure 1
Pre-operative
radiograph

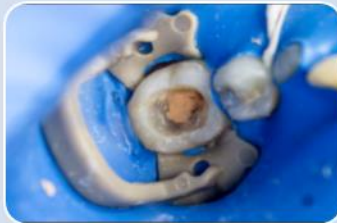

Figure 2
Occlusal view of
tooth #46 after
placement of the
rubber dam and
removal of caries

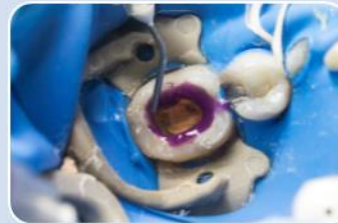


Figure 3
Etching using
37% phosphoric
acid

The tooth was isolated using a rubber dam and the previous filling was removed. Caries lesions on the cuspal area were removed using a round bur. A straight bur was then used for the extension of tooth structure. Sharp angles on the periphery were rounded-off with a tapered bur (Figure 2). Bevelling of the tooth structure was not done because studies show that this particular step weakens tooth structure. The enamel and dentin after assessment and evaluation of determined the type of interim restoration done. Fiber-reinforced composite using the direct technique was deemed appropriate. The shade of the tooth was taken with a vita shade guide and the shade #66 was selected.

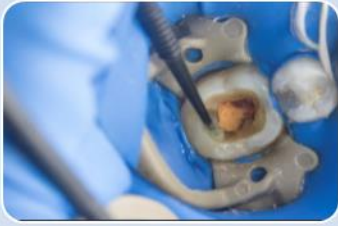

Figure 4
Application of adhesive




Figure 5
Fiber being wetted with resin

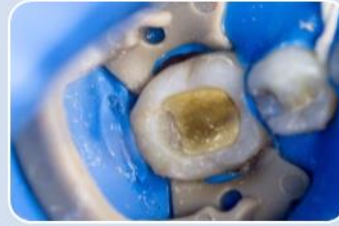

Figure 6
Placement of fiber on the buccal wall, pulpal floor and lingual wall

The enamel and dentin were etched using the total etching technique (Figure 3) wherein 37 % phosphoric acid (Gel etchant, Kerr) was used for 15 seconds. The etchant was removed by washing with water. The primer of the bonding agent (Optibond Versa primer, Kerr) was applied to the preparation using a scrubbing motion. The bonding agent (Optibond Versa adhesive, Kerr) was then placed (Figure 4) and was cured for 10 seconds using a conventional quartz tungsten halogen curing light (QHL 75 Curing Light, Dentsply).

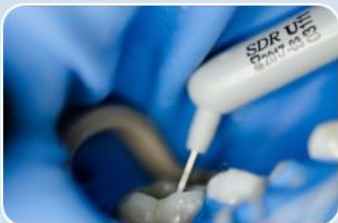

Figure 7
Placement of intermediary base

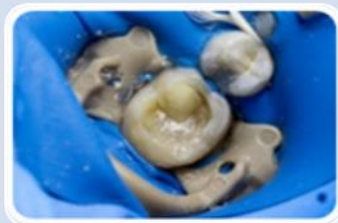

Figure 8
Cusp build-up

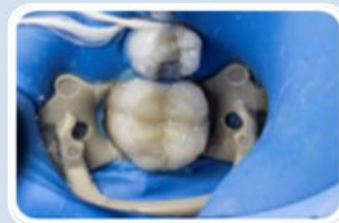


Figure 9
Development of occlusal contours

A 10mm length from the 3mm spool of fiber (Construct, Kerr) was cut using the indicated scissors which is included in the kit. This amount of material was enough to cover the bucco-lingual and mesio-distal width respectively while making sure the weak structure on the buccal, lingual and pulpal surfaces in line with the path of stress of occlusion was covered.

A glass slab was taken and the fiber was impregnated with low viscosity resin (Figure 5) that came with the kit. Excess material was removed with a hand instrument before placement on the buccal wall, pulpal floor and lingual wall (Figure 6). It was terminated on the occlusal third of the

buccal and the occlusal third of the lingual wall. A 4mm thickness of flowable intermediary base (Smart Dentin Replacement, Dentsply) was placed on the pulpal floor (Figure 7) and was cured for 40 seconds.

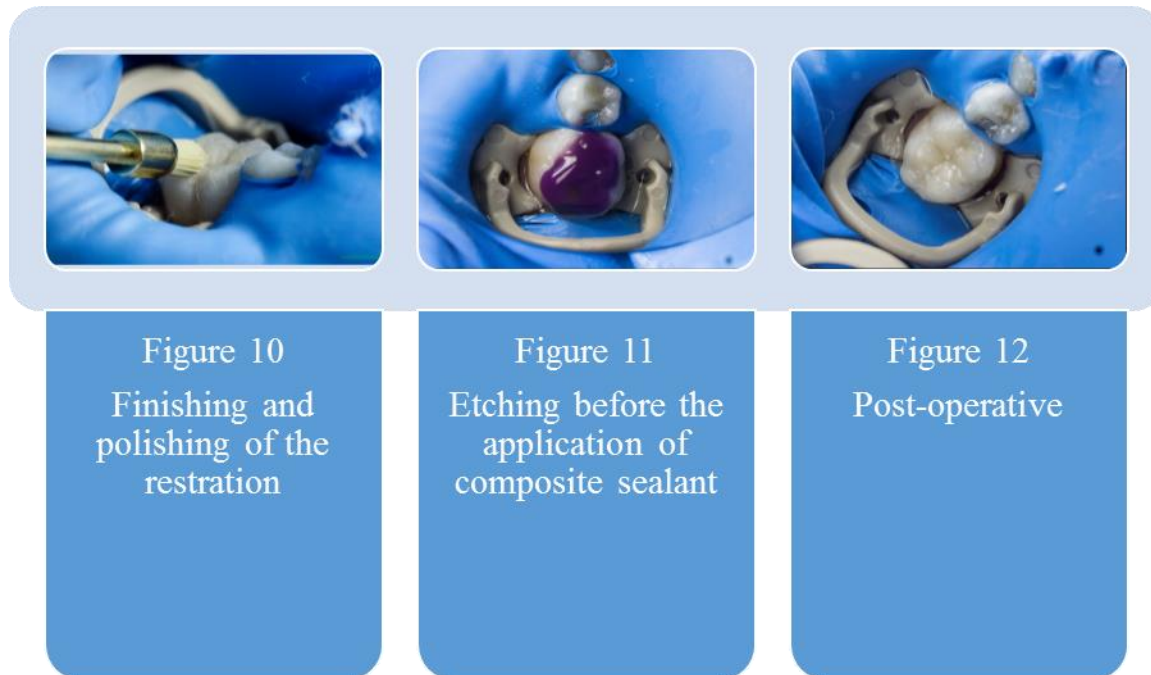


Figure 10
Finishing and
polishing of the
restoration

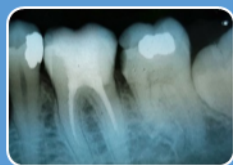Figure 11
Etching before the
application of
composite sealant

Figure 12
Post-operative

To reduce stress build-up, incremental and layering technique using a packable type of composite resin (Premisa, Kerr) was done. Cusp build-up of the restoration (Figure 8) by placement of 2.5 mm composite until occlusal anatomy was achieved (Figure 9). Occlusal adjustment was made where premature contacts were detected with the use of an articulating paper. Occlusal details using resin type finishing materials (Enhance Finishing System, Dentsply) was then carried out (Figure 10).

Sealing of the composite resin was done as a final step by the application of 37% phosphoric acid on the surface (Figure 11) for 15 seconds, was washed then gently air-dried. The composite sealant (OptiGuard Surface Sealant, Kerr) on the restoration then cured for 20 seconds (Figure 12).

According to Polesel, the biomechanical changes due to the root canal therapy and the degree of healthy dental tissue lost because of pathology and iatrogenic factors are the critical points leading the clinician to the restorative treatment planning (Polesel, 2014). A tooth, when treated endodontically, loses tooth structure and is a critical factor in treatment planning. Tooth fracture following endodontic treatment is a common complication faced by dentists. It is generally accepted that the strength of an endodontically treated tooth is directly related to the amount of remaining sound tooth structure (Jyothi Mandava, 2014). Therefore, efforts geared towards strengthening the tooth was made in this case to avoid failure or even tooth extraction. A good final restoration for an endodontically treated tooth plays a major role in the success of a treatment. Some options for restoring an endodontically treated tooth are the use of one or more posts, a crown, an onlay or an inlay. An inlay was not an option for this treatment because of the involvement of cusps. The crown was neither a choice for a final restoration because of the amount tooth structure left. An onlay was the treatment of choice for the final restoration given the condition of the tooth. Posts were not used because studies show that the use of posts after endodontics should be avoided because of the risk it poses. It should only be used when a core is needed because it predisposes tooth to tooth fracture. In fact, the American Association of Endodontics gave advice to practitioners in one of their newsletters stating that premolar and mandibular molar teeth are more prone to medico legal claims related to vertical root fracture following root canal treatment. Post should be placed only when essential for additional core support to avoid medico-legal risk (American Association of Endodontists, 2014).



Post-operative
radiograph

An interim restoration provides structural integrity until a definitive treatment can be done. In this case, the patient will be coming back after 2 months therefore this type of restoration is necessary. The need to reinforce a tooth after root canal therapy is a must depending on the nature of the treatment. According to the study of Nagasiri and Chitmongkolsuk, longevity for the tooth is greater where there is greater remaining tooth structure (Faria, Rodrigues, Antunes, de Mattos, & Riberio, 2011). In this case report, Construct by Kerr was used. The opaque resin was used over the endodontic restoration to make it more esthetically pleasing. The 3mm braid was used for the endodontically treated molar due to its mesio-distal width. Construct was placed from the buccal wall along the pulpal floor then terminated on the lingual wall. This was done because these walls are prone to fracture because of the forces of mastication. Moreover, the mesial and distal walls were still intact after the root canal therapy thus there was no need to reinforce these areas. Different fiber types such as glass fibers, carbon fibers, kevlar fibers, vectran fibers, polyethylene fibers have been added to composite materials. Polyethylene fibers used in the case improves the impact strength, modulus elasticity, and flexural strength of composite materials. Unlike carbon and kevlar fibers, polyethylene fibers are almost invisible in a resinous matrix and for these reasons, seem to be the most appropriate and esthetic strengtheners of composite materials (Tuloglu, Bayrak, & Tuncb, 2009). After 8 weeks of follow-up, the treated tooth was observed to be useful and successful. The integrity of the occlusal one-third was restores with the patient regaining confidence in using the tooth. No undesirable reactions were observed.

3. Conclusion

It has been proven in numerous studies that fiber-reinforced composites increases fracture strength. This makes an ideal material for an interim restoration for an endodontically treated because it was stated by Wagnil and Mueller in 2002 that a Root canal treatment should not be considered complete until the coronal restoration has been placed (Wagnild & Mueller, 2002). Awareness of the biological needs, long term prognosis and understanding of the limitations of available materials goes a long way to providing the ideal restoration for endodontically treated teeth (Eliyas, Jalili, & Martin, 2015). *There is still a scarcity in the literature of long-term use of fiber-reinforced composites, but given the condition of the tooth after treatment coupled with high patient acceptance of the material, the use of fiber-reinforced composited for interim restorations proves promising.*

Disclosure: The Authors have no financial interest in any of the companies mentioned in this article.

References

- American Association of Endodontists. (2014, Spring/Summer). Restoration of Endodontically Treated Teeth: The Endodontist's Perspective, Part I. Chicago, Illinois, USA.
- Butterworth C, E. A. (2003). Fibre-reinforced composites in restorative dentistry. *Dental Update*, 300-306.
- Eliyas, S., Jalili, J., & Martin, N. (2015). Restoration of the Root Canal Treated Tooth. *British Dental Journal*, 53-62.
- Faria, A. C., Rodrigues, R. C., Antunes, R. P., de Mattos, M. d., & Riberio, R. F. (2011). Endodontically Treated Teeth: Characteristics and Considerations to Restore Them. *Journal of Prosthodontic Research*, 69-74.
- Gopeshetti, V., & Shivanna, P. B. (2012). Fracture resistance of endodontically treated teeth restored. *Edodontology*, 71-77.
- Hargreaves, K. M. (2007). American Association of Endodontics. Retrieved April 2, 2016, from American Association of Endodontics: https://www.aae.org/uploadedfiles/publications_and_research/endodontics_colleagues_for_excellence_newsletter/summer07ecfe.pdf

Jyothi Mandava, P. C. (2014). Comparative evaluation of fracture resistance of root dentin to resin sealers and a MTA sealer: An in vitro study. *Journal of Conservative Dentistry*, 53–56.

Polesel, A. (2014). Restoration of the Endodontically Treated Posterior Tooth. *Giornale Italiano di Endodonzia*, 2-16.

Tuloglu, N., Bayrak, S., & Tuncb, E. S. (2009). Different Clinical Applications of Bondable Reinforcement Ribbond in Pediatric Dentistry. *European Journal of Dentistry*, 329–334.

Wagnild, G., & Mueller, K. (2002). *Pathways of the Pulp* 8th ed. MO: USA.