

Case report of a combined prostatic and utricular cyst

Paddy Dewan¹, Padma Rao², John Lazarus³

¹Kind Cuts For Kids Organization, ²Royal Children's Hospital, Melbourne, and ³Urology Unit, Red Cross Children's Hospital, University of Cape Town

Abstract

A 16 year old previously well boy presented with voiding difficulty that progressed to intermittent retention over a two month period. A renal ultrasound showed a structure consistent with a utricular remnant behind the base of the bladder that endoscopically appeared to terminate in the posterior wall of the prostatic urethra as a cystic, enlarged verumontanum. Following an uneventful endoscopic fulguration of the anterior wall, the boy remained catheterized overnight. The following day the catheter was removed at the time of a radiologic study of the lower urinary tract, which showed a dilated posterior urethra, but no reflux into the tubular retro-vesical structure that was noted to have emptied on a post-operative ultrasound.

Keywords

Utricle; prostatic cyst; bladder outlet obstruction; retention.

Copyright © 2016 [pediatricurologycasereports.com](http://www.pediatricurologycasereports.com).

Corresponding Author: Dr. Paddy Dewan

PA Dewan, PO Box 152, Parkville 3052, Australia

Email: paddy@paddydewan.com

Accepted for publication: 25 October 2016

Introduction

Levin describes the normal prostatic utricle (Latin for “pouch of the prostate”) as, usually, a minute, blind ending pouch opening into the verumontanum, noting that it has a glandular grouping, lined with epithelial cells with differentiation similar to those lining the main prostatic ducts and

acini. It has no function and is the male homologue of the female uterus [1]. However, utricular remnants can be sizable, and are frequently associated with severe hypospadias [2,3].

There appears to be uncertainty as to whether there is any difference between utricular remnants and Müllerian duct anomalies in males, with many using the term interchangeably [2,4,5]. Some authors declare a distinct difference, suggesting that Müllerian duct cysts are round, do not

communicate with the prostatic urethra and are discovered later in adults with normal genitalia [6]. The lesions that are connected to the middle of the verumontanum via an orifice that leads to the posterior urethra are not cysts as they are often referred to, but are a diverticulum attached to the urethra. In the case presented by Nork et al. [7], the patient had a cystic structure that appeared endoscopically like a cystic verumontanum, rather than the frequently seen thin walled cystic structure that is within the lumen of the urethra rather than being a cystic deformity of the verumontanum [3]. McDermott [3], in a study of MRI images of urethral anomalies, described six types of prostatic cysts, none of which were of the type described by Nork et al. [8], which seemed, on the endoscopic appearances, to be identical to our patient. However, our patient appeared to have both the features of a Müllerian cyst, but with a tubular structure behind the bladder usually termed a utricular remnant, unlike Nork's patient that lacked the retrourethral extension. Tröbs also presented a similar patient as one of four with a urethral cyst and vesicoureteral reflex [9].

Case Report

A 16 year old boy presented with increasingly obstructive bladder outlet

symptoms over a two month period. He had no previous urological history and no indication of urine infection, and no hematuria.

A renal ultrasound showed a structure consistent with a utricular remnant behind the base of the bladder [Fig. 1A,B] that on endoscopy appeared to terminate in the posterior wall of the prostatic urethra; a lesion that looked like a cystic, enlarged verumontanum [Fig. 2A,B,C,D].

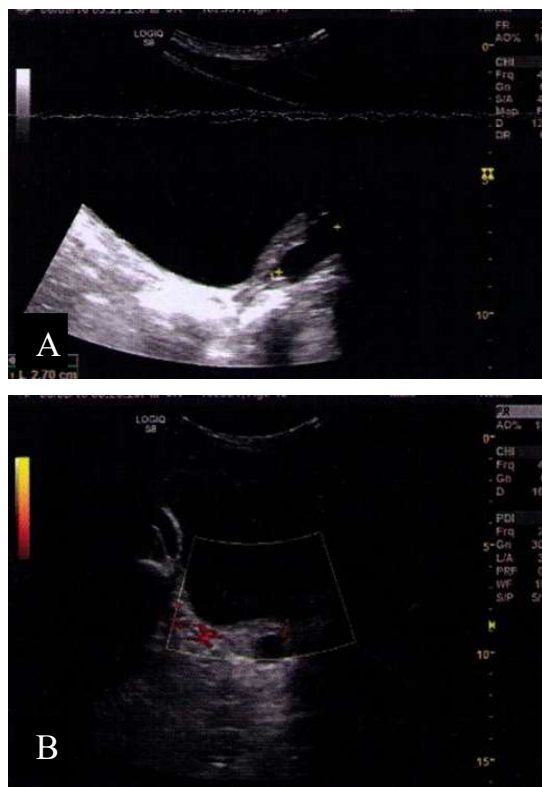


Fig. 1 (A, B). Longitudinal and transverse views of the posterior wall of the bladder before endoscopic incision of the prostatic cyst show a fluid filled structure arising from the posterior urethra.

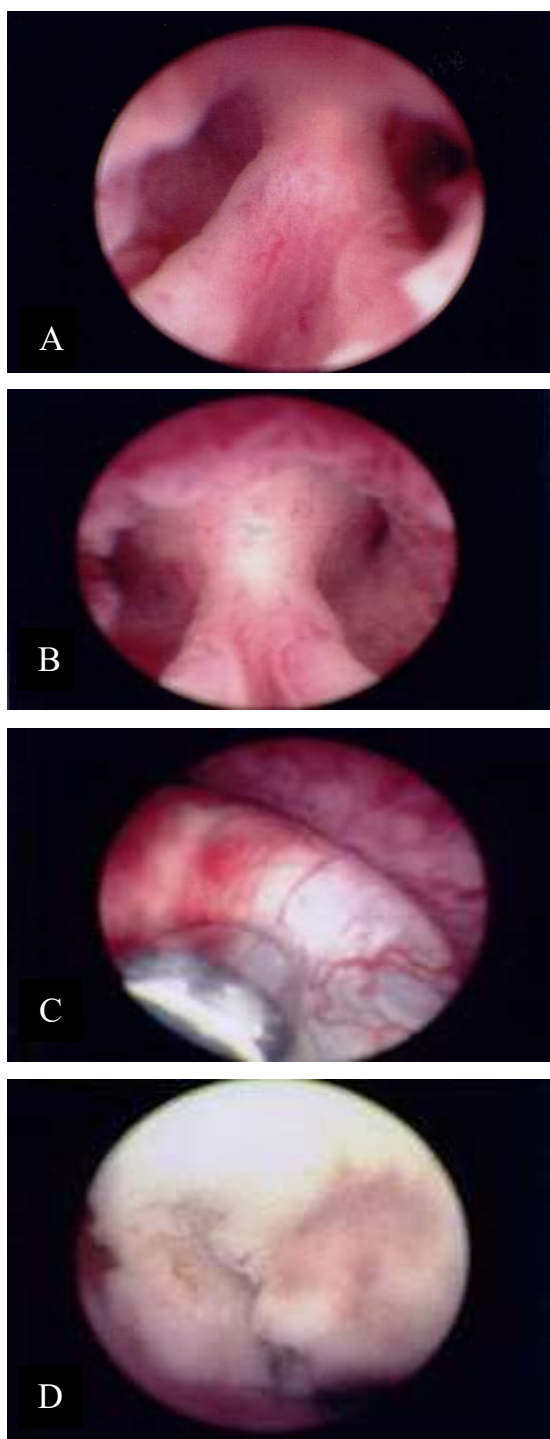


Fig. 2. The cristae are seen leading up to the cystic verumontanum (A) that is then seen in a closer view, just above the proximal end of the external sphincter. (B) The third image shows the bugbee electrode indenting the cyst (C) into

which a hole is created (D), large enough to admit the 11 FG cystoscope.

Following an uneventful endoscopic procedure the boy remained catheterized overnight; catheterization that was facilitated by endoscopic insertion of a guidewire and passage of the catheter over the guidewire [10]. The catheter was removed the following day at the time of a radiologic study of the lower urinary tract that showed a dilated posterior urethra, but no reflux into the tubular retro-vesical structure [Fig. 3] that was noted to have emptied on a post-operative ultrasound [Fig. 4 A,B].

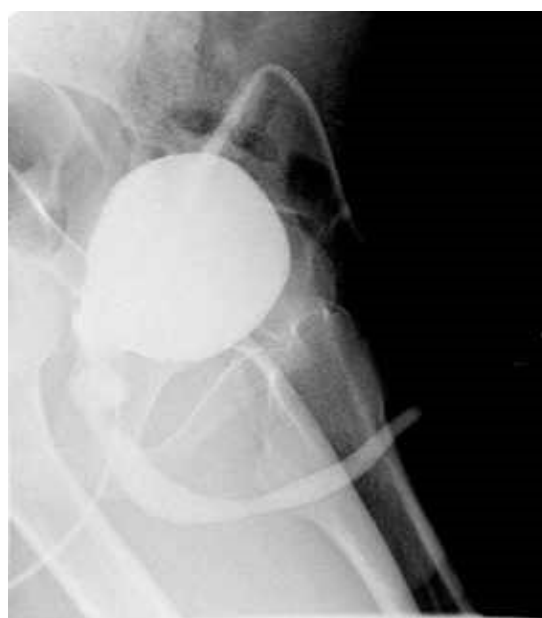

Fig. 3. A post-operative cystogram shows a dilated posterior urethra, but no reflux into the ultrasound and endoscopy identified cystic structure attached to the back of the posterior urethra.

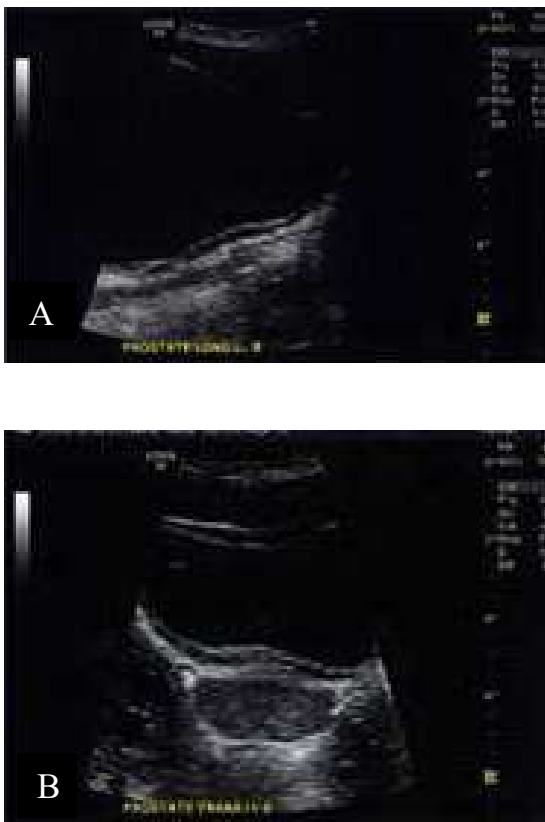

Fig. 4 (A, B). Longitudinal and transverse views of the posterior wall of the bladder after endoscopic incision of the prostatic cyst. The previously noted fluid collection has resolved.

Discussion

The most important aspect of the management of an individual rare case is that the patient has a good immediate and long-term outcome from the management, based on sound principles.

This was the case for the teenage boy we treated, who was managed by investigation with a cystoscopy after the ultrasound inference of a dilated utricular remnant. During the endoscopy, a cystic structure was

identified in the posterior urethra that appeared to be the cause of the obstructive symptoms, which were resolved with fulguration of part of the anterior wall.

Obviously, the embryology of the anomaly cannot be confirmed, but it is interesting to note the lack of clear definition of the difference between the pathology and the embryology of the lesions called Müllerian and utricular remnants, and it is interesting to contemplate the similarity in the endoscopy in severe hypospadias and masculinized congenital adrenal hyperplasia girls of the relationship to the verumontanum and the vagina, suggesting the utricular “cyst”, as it is misnamed, is from the Müllerian duct.

While cysts of the prostate are described [3], the only case similar to ours [8] was not associated with a tubular fluid filled structure behind the base of the bladder as we have seen. The utricular remnant component was not visible on the post-operative ultrasound, suggesting that the contents had been drained by opening of the cyst’s anterior wall. Subsequent reflux into the utricular component, we feel, was prevented, as supported by the post-operative cystogram, because of the residual flap valve arrangement created by the anterior wall of the cyst. This is similar to the way in which reflux into not an

ureterocele can be prevented by careful placement of the incision for the drainage of the cystic dilated the distal end of the ureter [11].

Conclusions

The embryology of the anomaly in this boy is uncertain, with the finding of both a tubular structure behind the base of the bladder and a cystic verumontanum not

having previously been reported, to our knowledge. However, resolution of the clinical problem of partial retention was easily achieved, as was normalization of the ultrasound.

Acknowledgements

The author(s) declare that they have no competing interests and financial support.

References

1. Levin TL, Han B, Little BP. Congenital anomalies of the male urethra. *Pediatr Radiol.* 2007; 37(9): 851–62.
2. Priyadarshi V, Singh JP, Mishra S, Vijay MK, Pal DK, Kundu AK. Prostatic utricle cyst: a clinical dilemma. *APSP J Case Rep.* 2013;4(2):16.
3. McDermott VG, Meakem TJ 3rd, Stolpen AH, Schnall MD. Prostatic and periprostatic cysts: findings on MR imaging. *AJR Am J Roentgenol.* 1995;164(1):123-7.
4. Nghiem HT, Kellman GM, Sandberg SA, Craig BM. Cystic lesions of the prostate. *Radiographics.* 1990;10(4):635-50.
5. Simpson WL Jr, Rausch DR. Imaging of male infertility: pictorial review. *AJRAm J Roentgenol.* 2009;192(6 Suppl):S98-107
6. Coppens L, Bonnet P, Andrienne R, de Leval J. Adult müllerian duct or utricle cyst: clinical significance and therapeutic management of 65 cases. *J Urol.* 2002;167(4):1740-4.
7. Sessions AE, Rabinowitz R, Hulbert WC, Goldstein MM, Mevorach RA. Testicular torsion: direction, degree, duration and disinformation. *J Urol.* 2003;169(2):663-5.
8. Nork JJ, Yap MK, Kaplan GW. Verumontanum Cyst Associated With Lower Urinary Tract Symptoms in an Adolescent. *Urology.* 2016;88:192-4.
9. Tröbs RB, Nounla J, Faber R, Schwarick J. Congenital urethral cysts in boys with vesicoureteric reflux. *Int Urol Nephrol.* 2003;35(1):41-5.
10. Dewan PA, Gotov E, Chiang D. Guide wire-assisted urethral dilatation for urethral strictures in pediatric urology. *J Pediatr Surg.* 2003;38(12):1790-2.

11. Ben Meir D, Silva CJ, Rao P, Chiang D, Dewan PA. Does the endoscopic technique of ureterocele incision matter? J Urol. 2004;172(2):684-6.

