

Renal abscess in a previously healthy 4-year-old girl: A case report

Secil Conkar, Ipek Kaplan Bulut, Sevgi Mir

Department of Pediatric Nephrology, Ege University Medical Faculty, Izmir, Turkey

Abstract

Renal abscess is uncommon in childhood. The common manifestations include fever, lumbar pain, abdominal pain and occasional flank mass. Renal ultrasonography enables us to achieve an early diagnosis, however; it may still be insufficient to distinguish it from pyelonephritis. Renal abscesses are usually associated with different predisposing conditions. In the present report, we aim to describe a case of a previously healthy child who developed a renal abscess.

Keywords

Renal abscess; antimicrobial therapy; children.

Copyright © 2016 pediatricurologycasereports.com.

Corresponding Author: Secil Conkar, M.D.

Department of Pediatric Nephrology,

Ege University Medical Faculty, Izmir, Turkey

E-mail: secilcankar@yahoo.com.tr

Accepted for publication: 25 Jun 2016

Introduction

Renal abscesses in previously healthy children have been reported in a few cases and diagnosis is difficult because in most of the patients, symptoms are nonspecific [1-4]. Etiologic reasons such as obstructive or infectious urinary tract diseases, diabetes mellitus, and intravenous use of illicit drugs, trauma, abdominal or urological surgery and

immune depression as in cancer or AIDS [3] are commonly reported in adults patients, while urological abnormalities and vesicoureteral reflux are more common in pediatric cases [5-7].

It has a diagnostic challenge due to diverse origins of infection and different pathogenetic mechanisms among patients, such as complicating UTI resulting from hematogenous spread, or staphylococcal carbuncle in rare cases of proximity to an infected area [8,9]. For the majority of children, the pathogenesis may be associated with ascending infection, as pre-existing

malformative uropathy, particularly vesicoureteral reflux (VUR), is common in pediatric patients.

The differential diagnosis includes emphysematous pyelonephritis, acute pyelonephritis complicated by papillary necrosis, acute lobar nephronia, malacoplakia, tuberculosis, renal cell carcinoma or Wilms' tumour [10-12]; therefore, a satisfactory diagnostic study is needed [12,13]. We describe the case of a previously healthy 4-year-old girl with a left renal abscess due to features in the diagnosis and treatment.

Case Reports

A previously healthy 4-year-old girl was admitted to the emergency department with history of episode of fever, vomiting and left flank pain. Her history was insignificant with no urinary tract infections, documented invasive bacterial infections, trauma of flank area or other serious diseases. On physical examination, severe pallor, pulse rate of 98/min, respiratory rate of 32/min and blood pressure of 90/60 mmHg. Findings on examination including her ears, nose, throat, heart and lungs were unremarkable. There was no lymphadenopathy found. Her abdomen was soft, with distinct tenderness on the right side just above the iliac spine. Initial laboratory investigations showed hemoglobin of 10,6 gm/dL; white cell count

of 14,200/mm³ (65% neutrophils, 32% lymphocyte), platelet count of 350,000/mm³ and an erythrocyte sedimentation rate of 92 mm/hour. The C-reactive protein level was 12 (0-0,5) mg/dL. Renal function test results were normal.

Urine osmolarity was 362 mOsm/L. Urinalysis demonstrated positive leucocyte esterase and nitrites, rare bacteria and 21-30 white blood and 4-8 red blood cells, with few urine epithelial cells. The urine cultures showed the growth of 1.000 colony-forming units/mL of ESBL-producing E coli.

An abdominal ultrasound displayed a single hypoechoic lesion in right kidney. Computerized tomography (CT) revealed right-sided renal abscess. CT scan showed the parenchyma of the right kidney was edematous and thick in appearance, and geographic dispersion, the capsule in the shape of the base of the triangle hipodens heterogeneous areas. The lower middle class and subcapsular loculated collections in the deepest place of 13 mm measured at the level of pol are available. This collection was compatible with subcapsular abscess formation fields [Fig. 1A,B].

CT confirmed the diagnosis to be a renal abscess. She was administered with Amikacin and Vancomycin for three weeks. Blood cultures were negative for bacteria. The tuberculin skin test was also negative.

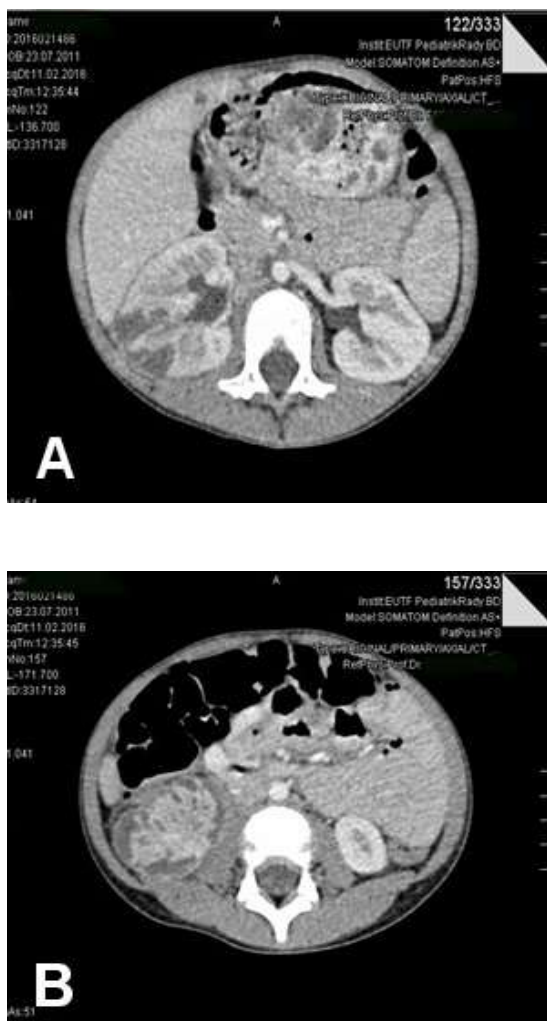


Fig. 1 (A, B). Computed tomography (CT) scan image of the right kidney showing abscess within the renal cortex measuring $3,5 \times 4,5 \times 4$ cm.

Since serum immunoglobulin levels were within normal range, immunodeficiency disorders including late-onset common variable immunodeficiency were unlikely. In addition, leucocyte differentiation and lymphocyte subsets were found normal. On follow-up, the patient was asymptomatic.

Voiding cystourethrography was normal. A technetium dimercaptosuccinic acid (DMSA) scan demonstrated focal area of decreased tracer uptake in the right kidney especially in the upper poles. Uroflowmetry did not show signs of impaired voiding or bladder dysfunction. We detected only large bladder volume with uroflowmetry. She responded positively to the therapy. The response to the treatment confirmed the diagnosis of renal abscess. After two months of follow-up, the patient showed weight gain and USG revealed complete resolution of the renal abscess.

Discussion

Renal and perirenal abscesses can complicate urological infection or occur secondary to hematogenous seeding [14]. Renal abscess is a walled-off cavity. The incidence in children is unknown. Renal abscesses are observed in all age groups and are three times more likely to occur in males than in females. Most abscesses are unilateral single lesions (77%) and occur in the right kidney (63%) [15]. Our patient was female and also had a renal abscess in the right kidney.

Renal abscesses are characterized by onset of fever, vague lumbo-abdominal pain, pallor, fatigue, sweats, and general signs and symptoms of deep-seated suppuration such

as weight loss. Common symptoms of urinary tract infection, such as dysuria and/or urinary frequency are not reported in most of the patients with renal abscesses [6,9]. In our study, we reported similar symptoms including fever, flank pain, and vomiting. Pain can be referred to the back. Our patient did not have lower urinary tract symptoms.

The clinical diagnosis of renal or perinephric abscess should be suspected in a patient presenting with consistent signs and symptoms, including prolonged fever and flank pain as well as laboratory evidence of chronic inflammation (eg, elevated ESR and CRP). Identification of a renal abscess on imaging (ideally computed tomography) confirms the diagnosis. Ultrasonography is the recommended imaging modality to establish the diagnosis and reveals a hypoechoic mass [5,7,16]. A renal abscess was suspected initially. Then hypoechoic lesion in the right kidney was detected by ultrasound. We confirmed the diagnosis with computed tomography. On CT, renal abscesses appear as intrarenal walled-off cavities. CT may also demonstrate thickening of Gerota's fascia, renal enlargement, parenchymatous inflammation, decreased renal attenuation, and lobar necrosis.

The approach to the management of renal

abscess includes antimicrobial therapy accompanied by percutaneous drainage (when justified). In general, large intrarenal abscesses require surgical drainage, particularly if the patient has persistent fever and absence of clinical improvement after one-week of appropriate antimicrobial therapy. In our case, the abscesses analyzed were not bigger than 5 cm and were treated with antibiotics, not with surgical drainage. In smaller abscesses (< 3 cm) antibiotics must be used alone. We realized that antibiotic treatment was fundamental for a rapid recovery. In our case, the renal abscess recovered completely following the antibiotic treatment without the need for any surgical intervention. The predominant causative agent of renal abscesses is *S. aureus*, mostly involved in hematogenous spread and *Escherichia coli*, which is associated with ascending urinary tract infections [17,18]. We detected that *Escherichia coli* was related to UTI.

The differential diagnosis of renal abscess includes acute focal bacterial nephritis, pyelonephritis, tuberculosis and malignancies, such as neuroblastoma and Wilms tumour [19]. Percutaneous aspiration is recommended in the case of a suspected tuberculosis or malignancy. In the present case, percutaneous aspiration helped to establish a correct diagnosis and to identify

the causative organism.

Renal abscesses are very rare amongst intraabdominal abscesses and the risk factors identified include presence of renal stone, structural abnormality of the urinary tract, and history of urologic surgery, trauma, and diabetes mellitus [18-20]. There were no such risk factors in our case.

Conclusion

This is one of the very few reported cases of a previously healthy child with renal abscess

who had no predisposing conditions. Renal abscesses should be included in the differential diagnosis of fever and abdominal pain in healthy children. Additionally, in this patients, renal ultrasonography and abdominal CT with contrast must be studied without delay.

Acknowledgements

The author(s) declare that they have no competing interests and financial support.

References

1. Piretti RV, Piretti-Vanmarcke R, Piretti A. Renal abscess in previously healthy girl. *Urology*. 2009;73(2): 297-8.
2. Laufer J, Grisaru-Soen G, Portnoy O, Mor Y. Bilateral renal abscesses in a healthy child. *Isr Med Assoc J*. 2002;4(12):1150-1
3. Rote AR, Bauer SB, Retik AB. Renal abscess in children. *J Urol*. 1978;119(2):254-8.
4. Barker AP, Ahmed S. Renal abscess in childhood. *Aust NZ J Surg*. 1991;61(3):217-21.
5. Wang YT, Lin KY, Chen MJ, Chiou YY. Renal abscess in children: a clinical retrospective study. *Acta Paediatr Taiwan*. 2003 Jul-Aug;44(4):197-201.
6. Cheng CH, Tsai MH, Su LH, et al. Renal abscess in children: a 10-year clinical and radiological experience in a tertiary medical center. *Pediatr Infect Dis J*. 2008;27(11):1025-7.
7. Shimizu M, Katayama K, Kato E, Miyayama S, Sugata T, Ohta K. Evolution of acute focal bacterial nephritis into a renal abscess. *Pediatr Nephrol*. 2005;20(1):93-5.
8. Angel C, Shu T, Green J, Orihuela E, Rodriguez G, Hendrick E. Renal and perirenal abscess in children: proposed physiopathologic mechanisms and treatment algorithm. *Pediatr Surg Int*. 2003;19(1):35-9.
9. Fernandes RC, Duarte PD. Perinephric and renal abscesses in children: a study of three cases. *Rev Inst Med Trop S Paulo*. 2002;44(6):341-4.

10. LópezAlcina E, ArlandisGuzmán S, MonserratMonfort JJ, FusterEscrivá A, Jiménez Cruz F. Renal and perirenal abscess. *Actas Urol Esp.* 1999;23(2):135-9.
11. Brandeis JM, Baskin LS, Kogan BA, Wara D, Dorenbaum A. Recurrent *Staphylococcus aureus* renal abscess in a child positive for the human immunodeficiency virus. *Urology.* 1995;46(2):246-8.
12. Chaudhry S, Bolt R. Bilateral renal abscess in a previously healthy 11-year-old girl. *Eur J Pediatr.* 2010;169(11):1423-5.
13. Comploj E, Cassar W, Farina A, Gasparella P, Trenti E, Palermo S, Dechet CB, Caione P, Pycha A. Conservative management of paediatric renal abscess. *J Pediatr Urol.* 2013;9(6 Pt B):1214-7.
14. Yen DH, Hu SC, Tsai J, et al. Renal abscess: early diagnosis and treatment. *Am J Emerg Med.* 1999; 17(2):192-7.
15. Dembry LM, Andriole VT. Renal and perirenal abscesses. *Infect Dis Clin North Am.* 1997;11(3):663–80.
16. Fiegler W. Ultrasound in acute renal inflammatory lesions. *Eur J Radiol.* 1983;3(4):354-7.
17. Lin HS, Ye JJ, Huang TY, Huang PY, Wu TS, Lee MH. Characteristics and factors influencing treatment outcome of renal and perinephric abscess--a 5-year experience at a tertiary teaching hospital in Taiwan. *J Microbiol Immunol Infect.* 2008;41(4):342-50.
18. Wippermann C, Schofer O, Beetz R, et al. Renal abscess in childhood: diagnostic and therapeutic progress. *Pediatr Infect Dis J.* 1991;10(6):446–50.
19. Mas Casullo VA, Bottone E, Herold BC. *Peptostreptococcus saccharolyticus* renal abscess: a rare cause of fever of unknown origin. *Pediatrics.* 2001;107(1):E11.
20. Patterson JE, Andriole VT. Renal and perirenal abscesses. *Infect Dis Clin North Am.* 1987;1(4):907-26.

Access this article online

<http://pediatricurologycasereports.com>

Quick Response Code

