

## Incidental diagnosis of renal tuberculosis in an adolescent submitted to videolaparoscopic nephrectomy

Letícia Alves Antunes<sup>1</sup>, Carolina Talini<sup>1</sup>, Bruna Cecília Neves de Carvalho<sup>1</sup>, Antonio Ernesto da Silveira<sup>1</sup>, Antonio Carlos Moreira Amarante<sup>1,2</sup>

<sup>1</sup>Department of Pediatric Surgery, Hospital Pequeno Príncipe, Curitiba/PR, Brasil

<sup>2</sup>Department of Pediatric Surgery, Universidade Federal do Paraná, Curitiba/PR, Brasil

### Abstract

Genitourinary tuberculosis is rare in children. The aim of this study is to describe an unusual case of renal tuberculosis in a 16 years old girl, diagnosed with Hinman Syndrome and chronic renal failure. During a hematuria investigation the cystourethrogram revealed grade V right vesicoureteral reflux and small bladder. Ultrasonography demonstrated various cysts in left kidney with irregular content, suggesting dysplastic multicystic kidney. Scintigraphy showed functional exclusion of the left kidney. Total laparoscopic nephrectomy was proposed. Gregoir right ureteral reimplantation and Mitrofanoff mechanism using the distal left ureter were also indicated. During surgery presence of multiple cysts in the left kidney with caseous aspect, left ureter obstruction with caseous content in the lumen and bladder mucosa with friable and thickened wall were found. Histopathological study revealed chronic necrotizing granulomatous inflammation. Mantoux tuberculin skin test was strongly reactive, and family history was positive for pulmonary tuberculosis 10 years earlier. This paper shows the importance of bringing extrapulmonary tuberculosis to the roll of differential diagnosis of hematuria. Early treatment is important to avoid disease progression with functional loss of the organs as happened in this case.

### Keywords

Genitourinary tuberculosis; renal tuberculosis; necrotizing granulomatous inflammation.

Copyright © 2016 [pediatricurologycasereports.com](http://www.pediatricurologycasereports.com).

**Corresponding Author:** Antonio Carlos Moreira Amarante. Pediatric Surgery, Hospital Pequeno Príncipe, Curitiba/PR, Brasil

E-mail: [antonio.amarante@gmail.com](mailto:antonio.amarante@gmail.com)

Accepted for publication: 08 May 2016

## Introduction

Genitourinary tuberculosis (TB) is very uncommon in children as the symptoms of renal tuberculosis do not appear for 5 to 10 years after primary pulmonary infection with *Mycobacterium tuberculosis* due to endogenous reactivation [1]. It is the most common extrathoracic form of TB and accounts for less than 3-4% of all pulmonary TB cases [2,3].

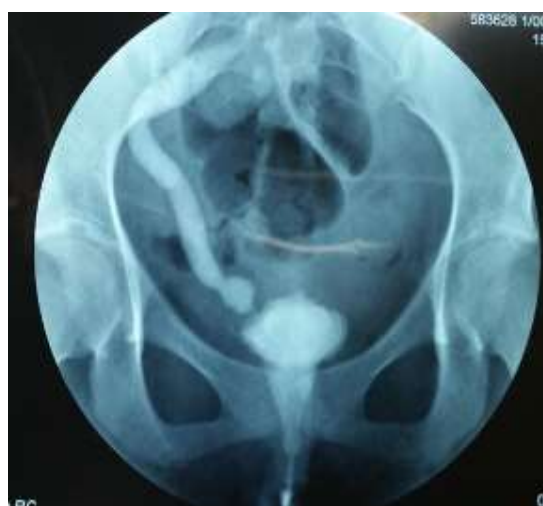Genitourinary TB usually presents with symptoms such as irritative voiding, hematuria and flank pain [4]. Additionally, presentation as a mass lesion is extremely rare [5-7].

If diagnosed early, nearly all children can be cured with medical treatment. However, diagnosis is often delayed and a number of children present with non-functioning kidneys, obstructed ureters, shrunken bladders and even chronic renal failure [1,8]. This report describes a 16 years old girl who presented with a Hinman Syndrome and chronic renal failure and was diagnosed with renal TB via a post-nephroureterectomy histopathological examination.

## Case Reports

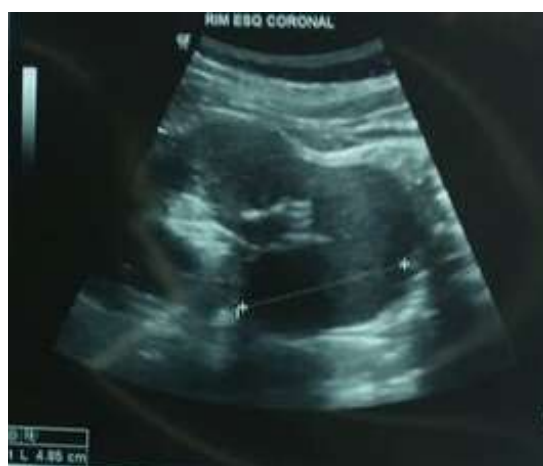A 16 years old girl, diagnosed as Hinman Syndrome and chronic renal failure three years before was been referred to the pediatric urology service. During a

hematuria investigation a cystourethrogram revealed grade V vesicoureteral reflux and reduced bladder capacity [Fig. 1].



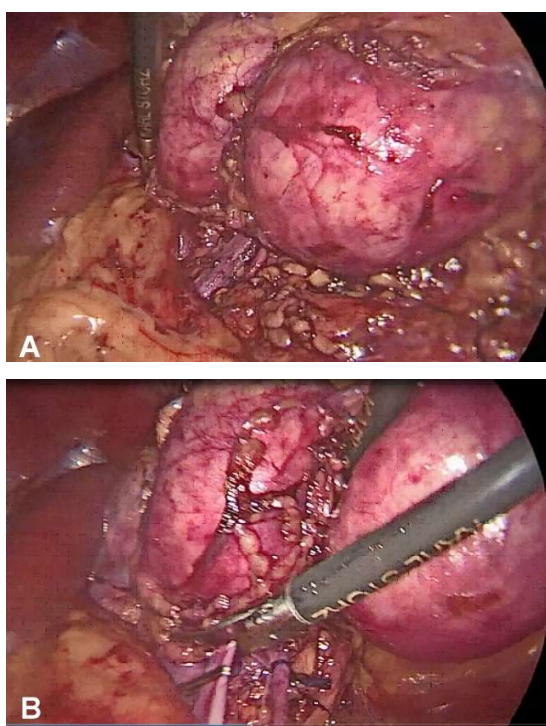
**Fig. 1.** Renal lump on left side.

Ultrasonography demonstrated various cysts in left kidney with irregular content, suggesting dysplastic multicystic kidney, the largest cyst was in the inferior pole with a diameter of 3,6cm [Fig 2].



**Fig. 2.** Ultrasound – multiple cysts suggesting dysplastic multicystic kidney.

Scintigraphy showed functional exclusion of the left kidney. Urodynamic study demonstrated low bladder capacity and compliance, presence of uninhibited contractions of the detrusor with micturitional urgency and perineal strengthening. Laparoscopic nephrectomy, laparoscopic Gregoir right ureteral reimplantation and Mitrofanoff using the distal left ureter were proposed. During surgery presence of multiple cysts in the left kidney with caseous aspect, left ureter obstruction with caseous content in its lumen and bladder mucosa with friable and thickened wall were found [Fig. 3A, B].



**Fig. 3.** (A, B) Transoperative – kidney macroscopic aspect.

### Discussion

Genitourinary TB is generally occurred between the second and fourth decade of life. Despite this form of TB represents less than 5% of extrapulmonary TB cases worldwide, renal tuberculosis is very rare in the pediatric age group [9,10]. Renal TB is usually a sequelae of pulmonary TB. The seeding to the kidneys is hematogenous. The bacilli usually are lodged in the cortico-medullary region and form cortical granulomas. These granulomas remain dormant for a long period of years and when the individual's immunity is weakened, there is a reactivation of these dormant bacilli resulting in spread into the medulla, causing papillitis. The disease results with extensive necrosis of the renal papillae and the formation of frank cavities abscess formation and total destruction of the renal parenchyma. After this stage, kidney with tuberculosis develop a non-functioning kidney with extensive calcification involving the entire kidney as a result of scarring in the renal cortex [11-13]. Further progression to caseation and breaching of the collecting parenchymal lead to dissemination of the bacilli throughout the urinary tract, and lesions may appear in the ureters, bladder and rarely in the urethra [14]. In the current case, Mantoux tuberculin skin test was strongly reactive. There was

also evidence of active TB among family members.

Usually the disease has a chronic or asymptomatic course. When symptomatic, patients with renal TB present with dysuria, hematuria, sterile pyuria, flank pain, recurrent urinary tract infections and constitutional symptoms [4,10]. Usually patients present pyuria with negative urine culture [15].

The radiographic appearance of the condition is variable and depends on the stage of the infection [16]. The radiological abnormalities include calcification, cortical scarring, caliceal cavitation and destruction, ureteral strictures or irregularity, small-capacity bladder and non-visualized kidney [1]. An enhancing renal mass is a rare presentation; in such cases, renal cell carcinomas, renal metastasis, lymphomas or abscesses are usually considered in the differential diagnosis [17]. Mantoux tuberculin skin test is usually positive [18].

There is an association between renal tuberculosis and bladder tuberculosis as the bacilli can migrate there. Cystoscopy is indicated in order to investigate the bladder [15]. The association of renal disorders with lower urinary tract alteration is strongly suggestive of the diagnosis [19].

Renal TB can be cured without surgical intervention; however, surgical management

is required in a minority of cases and may be either excisional or reconstructive and every effort must be made to preserve functioning renal tissue [1]. In cases where the lesion involves the renal parenchyma or where the kidney remains non-functioning despite adequate drainage for an obstructing lesion, nephrectomy ensures removal of the infective pathology and decreases chances of resurgence of the disease [20,21]. Additionally, Krishnamoorthy et al [13] suggested that the invasive or operative procedures for renal and ureteral TB can be categorized into the following groups: (1) drainage for hydronephrosis (ureteric stenting or percutaneous nephrostomy); (2) drainage of abscesses or localized collections; (3) definitive local treatment of the affected part of the kidney (cavernotomy/partial nephrectomy); (4) nephrectomy of the non-functioning tuberculous kidney (open/laparoscopic/retroperitoneoscopic techniques) and (5) reconstruction of the upper urinary tract (uretero-calycostomy, ureteric reimplantation, ileal ureteric replacement).

## Conclusion

This paper shows the importance of bringing extrapulmonary tuberculosis to the roll of differential diagnosis of hematuria. Early treatment is important to avoid disease

progression with functional loss of the organ as happened in this case. Hence, it is necessary to have a high index of suspicion.

## References

1. Nerli RB, Kamat GV, Alur SB, Koura A, Vikram P, Amarkhed SS. Genitourinary tuberculosis in pediatric urological practice. *J Pediatr Urol.* 2008;4(4):299-303.
2. Bansal P, Bansal N. The surgical management of urogenital tuberculosis our experience and long-term follow-up. *Urol Ann.* 2015; 7(1):45-52.
3. Hemal AK. Genitourinary tuberculosis. In: Sharma SK, Mohan A, editors. *Tuberculosis.* 1st ed. New Delhi, India: Jaypee Brothers Medical Publishers; 2001. pp. 325–37.
4. Singh JP, Priyadarshi V, Kundu AK, Vijay MK, Bera MK, Pal DK. Genitourinary tuberculosis revisited: 13 years' experience of a single centre. *Indian J Tuberc.* 2013;60(1):15–22.
5. Singh JP, Priyadarshi V, Kundu AK, Vijay MK, Bera MK, Pal DK. Genitourinary tuberculosis revisited--13 years' experience of a single centre. *Indian J Tuberc.* 2013;60(1):15-22.
6. Gupta H, Kone K, Pandey S, Dorairajan LN, Kumar S. Tubercular mas mimicking a tumour in a horseshoe kidney: A unique presentation. *Int Urol Nephrol.* 2004;36(3):323–4.
7. Dinolfo M. Renal tuberculosis presenting as renal mass. *Proc UCLA Healthcare.* 2013;17:1.
8. Kulchavenya E, Kholto bin D. Diseases masking and delaying the diagnosis of urogenital tuberculosis. *Ther Adv Urol.* 2015; 7(6):331-338.
9. Hatzenbuehler LA, Starke JR. Tuberculosis (Mycobacterium tuberculosis) In: Kliegman RM, Stanton BM, St Geme J, Schor NF, editors. *Nelson Textbook of Paediatrics.* 20th ed. Philadelphia, Pennsylvania, USA: Elsevier; 2015. pp. 1445–60.
10. Dhua AK, Borkar N, Ghosh V, Aggarwal SK. Renal tuberculosis in infancy. *J Indian Assoc Pediatr Surg.* 2011;16(2):69–71.
11. Daher Ede F, Silva Júnior GB, Damasceno RT, Santos GM, Corsino GA, Silva SL, *et al* . End-stage renal disease due to delayed diagnosis of renal tuberculosis: A fatal case report. *Braz J Infect Dis* 2007;11(19):169-71.

## Acknowledgements

The author(s) declare that they have no competing interests and financial support

12. Wise GJ, Marella VK. Genito urinary manifestations of tuberculosis. *Urol Clin N Am* 2003;30(1):111-21.
13. Krishnamoorthy S, Gopalakrishnan G. Surgical management of renal tuberculosis. *Indian J Urol.* 2008;24(3):369-75.
14. Chattopadhyay A, Bhatnagar V, Agarwala S, Mitra DK. Genitourinary tuberculosis in pediatric surgical practice. *J Ped Surg.* 1997; 32(9): 1283-6.
15. Lopes AJ, Capone D, Mogami R, Tessarollo, Cunha DL, Capone RB, et al. Tuberculose extrapulmonar: aspectos clínicos e de imagem. *Pulmão RJ.* 2006; 15(4):253-61.
16. Merchant S, Bharati A, Merchant N. Tuberculosis of the genitourinary system- Urinary tract tuberculosis: Renal tuberculosis-Part I. *Indian J Radiol Imaging.* 2013;23(1):46-63.
17. McDougal WS, Wein AJ, Kavoussi LR, Novick AC, Partin AW, Peters CA, et al. *Campbell-Walsh Urology.* 10th ed. Philadelphia, Pennsylvania, USA: Saunders; 2012. pp. 1417–18.
18. Santos BA, Moehlecke M, Amaral IP, Amaraal RH, Scatolin I, Ranieri T, et al. Tuberculose infantil: estudo retrospectivo. *Rev HCPA.* 2011; 31(3):296-302.
19. Bethlem EP. Manifestações clínicas da tuberculose pleural, ganglionar, genitourinária e do sistema nervoso central. *Pulmão RJ.* 2012; 21(1):19-22.
20. Santra A, Mandi F, Bandyopadhyay. Renal tuberculosis presenting as a mass lesion in a two-year-old girl – report of a rare case. *Sultan Qaboos Univ Med.* 2016; 16(10):105-8.
21. Tian X, Wang M, Niu Y, Zhang J, Song L, Xing N. Retroperitoneal laparoscopic nephroureterectomy for tuberculous nonfunctioning kidneys: a single-center experience. *Int Braz J Urol.* 2015; 41(2):296-303.

Access this article online

<http://pediatricurologycasereports.com>

Quick Response Code

