

Animal bite of genitalia in a child: A rare case of anterior urethral injury

Mohamad Sidani¹, Jason K. Au¹, Rodolfo A. Elizondo¹, Thomas G. Smith III²,
David R. Roth¹

¹Department of Pediatric Urology, Texas Children's Hospital/ Baylor College of Medicine, Houston TX

²Scott Department of Urology, Baylor College of Medicine

Abstract

Pediatric genital injuries are relatively uncommon. Urethral injuries occur in 3.4% of genitourinary injuries in children. The majority of urethral injuries in boys are to the anterior urethra. We review the diagnosis and management of anterior urethral injuries in the setting of a dog bite to the genitalia in child.

Keywords

Urinary trauma; dog bite; child; anterior urethral injury.

Copyright © 2016 [pediatricurologycasereports.com](http://www.pediatricurologycasereports.com).

Corresponding Author: Rodolfo A. Elizondo, MD
Baylor College of Medicine/Texas Children's
Hospital Clinical Care Center 6701 Fannin Street,
Suite 620 Houston, Texas, USA

E-mail: raelizon@texaschildrens.org

Accepted for publication: 9 June 2016

Introduction

Pediatric genital injuries are relatively uncommon. In 2013 the National Electronic Injury Surveillance System reported an incidence of 0.4-0.8% of all cases of childhood trauma [1]. However that study failed to include genital injuries unrelated to consumer products or sports, such as sex-

related injuries and animal bites of the genitalia. Bite wounds are involved in 1% of all emergency department visits in the United States and two-thirds of those visits were pediatric patients [2]. Dog bites are the most common bite wounds, with an incidence of 12.9 individuals per 10000 trauma cases. Children are 3.2 times more likely to suffer dog bites than adults are [3]. In the literature, there are 20 reported cases of genital dog bites in boys [3]. Not only are pediatric animal bite injuries to the genitalia rare, but they are even rarer when they occur with a concomitant urethral injury [4].

Urethral injuries occur in 3.4% of genitourinary injuries in children [5]. The majority of urethral injuries in boys are to the anterior urethra [6]. To date, only two other cases of urethral injuries in children resulting from animal bites of genitalia, have been reported in the literature [2]. We review the diagnosis and management of anterior urethral injuries in the setting of a dog bite to the genitalia in child.

Case Reports

A 5 year old boy, with a history of cerebral palsy and asthma, one week status post circumcision, presented to the Emergency Room (ER) with a penile laceration. The patient was sleeping when the family's two-month-old new puppy jumped into the child's crib, "ripped the diaper off" and bit his genitalia.

Seven hours had elapsed by the time the patient presented to ER. The parents noted that the child had not urinated since the incident. On physical examination, there was a large hematoma obscuring the penile wound, but it was apparent that the scrotum and testicles, were unaffected.

The patient was taken to the operating room for exploration, washout of the penile wound and possible urethroplasty. A 10 F Foley catheter was inserted, after which we could appreciate the magnitude of the urethral and

ventral shaft skin injury. The wound was copiously irrigated, gently debrided and all blood clots were removed. This revealed a 1cm full thickness defect of the proximal pendulous urethra and a laceration to the tunica albuginea of the right corporal body. [Fig. 1].

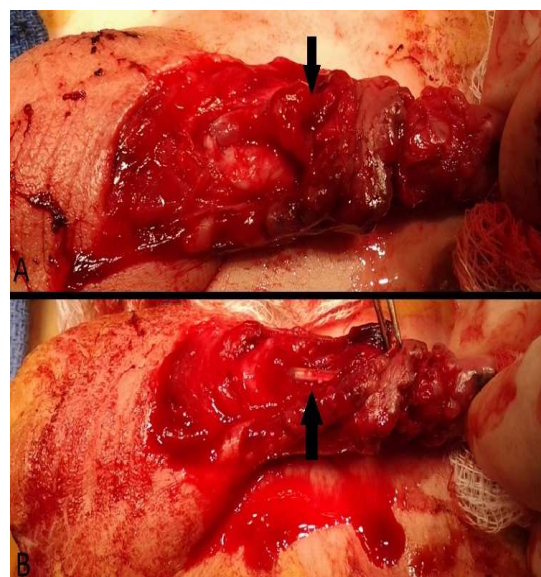


Fig. 1. (A) Pre-operative images showing injury of the proximal pendulous urethra (arrow), separation of the circumcision and absent skin over the distal shaft. (B) 10 F Foley catheter visible through the transected urethra.

The previous circumcision incision was completely dehisced and the skin overlying the distal shaft had completely sloughed off. The urethra was spatulated proximally and distally and primarily repaired in two layers with interrupted 5-0 PDS [Fig. 2]. Then the

tunica albuginea of the right corporal body was closed with three 4-0 poliglecaprone interrupted sutures.

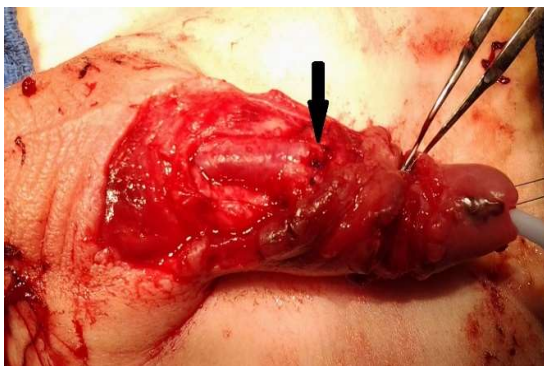


Fig. 2. Re-approximation of the urethral defect over the catheter with primary repair (arrow).

A Dartos flap was mobilized to cover the urethral repair. Finally, skin flaps were raised and the devitalized shaft skin was debrided. We left as much usable skin as possible for primary reapproximation of the wound edges. After the reapproximation of the ventral penile shaft skin was complete, the original circumcision was reapproximated [Fig. 3A, B]. No chordee was noted intraoperatively.

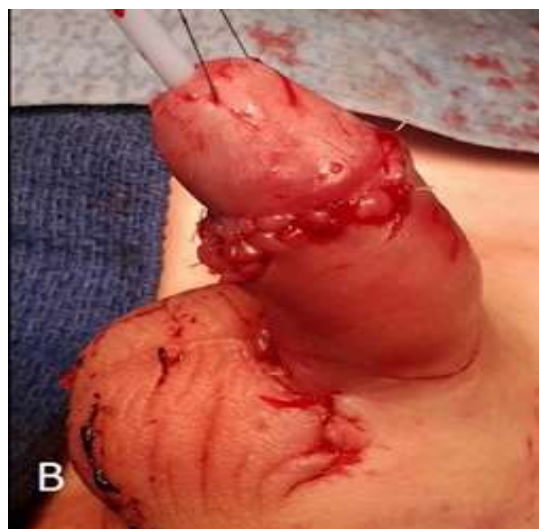
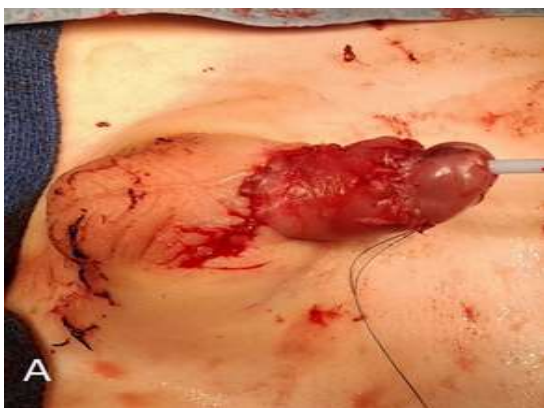
Fig. 3. (A) Skin flaps were used to close the superficial defect covering a raised Dartos flap overlying the repaired pendulous urethra. (B) Re-approximation of the skin at the level of the circumcision.

The patient had an uneventful hospital course, and was observed in the hospital overnight on Vancomycin and Piperacillin/Tazobactam. Rabies prophylaxis was not administered since it was a known newborn, house dog that was previously vaccinated and there were no concerns for Rabies infection. He was discharged home on Amoxicillin/Clavulanate. The Foley catheter and dressing were removed one week post-operatively. With the exception of minor sloughing at the ventral mid-shaft skin, the wound noted to be healing well. At the one month follow-up visit, the parents reported a good stream and no post-operative chordee and at seven-months, his

stream was still strong and no chordee was present. There was no evidence of hematuria, urinary tract infections or urethrocutaneous fistula.

Discussion

Urethral injuries in children are exceptionally rare [5]. They are more common in boys than in girls, since in females the urethra is shorter and is protected behind the pubic symphysis. In males, the urethra is divided into anterior and posterior portions, separated by the urogenital diaphragm. In our case, the patient presented with a penetrating wound, exposing a transected pendulous urethra.

In cases of blunt or penetrating urethral injury the extent of urethral damage guides the management decision. Generally, when a urethra is completely transected, surgical repair should be attempted immediately [7]. A urologist should keep in mind the principle of a hypospadias repair when performing the reconstructive surgery, including a widely spatulated and tension-free urethral anastomosis, non-overlapping suture lines, and coverage of the anastomosis with local tissue flaps, in an effort to avoid stricture formation or development of urethrocutaneous fistula [8]. When there is suspicion of transection of the urethra after trauma, a retrograde

urethrography is the gold standard for evaluating urethral injuries. A Foley catheter should be placed through the urethra over an endoscopically inserted guide wire if injury is present. An additional suprapubic tube (SPT) may be introduced to allow for diversion of urine and proper healing of the urethral disruption. A follow up voiding cystourethrogram (VCUG) should be performed at the 4 weeks mark to monitor the healing process. If the VCUG is normal, the SPT can be safely removed [7]. Since the patient was going to the operating room (OR) for wound exploration, we consider not to expose our patient to radiation since any type of imaging at this point would not add more information than what could be obtained in the OR.

Our patient had an obvious penetrating wound injury covered with blood, clots and circumcision dehiscence. Our first response was to take him to the OR for wound irrigation and exploration to determine the extent of the injury. After blood washout we saw a 1 cm defect of the anterior pendulous urethral. We were able to mobilize the urethra proximally and distally to achieve a tension free anastomosis. If this was not possible, we would have considered staging the surgery, leaving the child with a hypospadiac urethra and returning later for definitive repair.

One of the main concerns following a bite wound is the risk of infection. The majority of infections manifest within 48 hours following a bite. The risk is substantial, occurring in up to 30% in cases of uncomplicated general dog bites [9]. It is still debated whether prophylactic antibiotics should be given to all patients, even if the wound is thoroughly irrigated, cleaned and debrided. Irrigation will bring down the risk from nearly 60% to only 12% in cases of uncomplicated dog bites [10]. It is our feeling that antibiotics should be given in all cases of dog bite to the genitalia.

Genital injuries are more commonly encountered in adults than in children. Only two cases in the literature have described urethral injury as a result on an animal bite

References

1. Casey JT, Bjurlin MA, Cheng EY. Pediatric genital injury: an analysis of the National Electronic Injury Surveillance System. *Urology*. 2013;82(5):1125-30.
2. Gomes CM, Ribeiro-Filho L, Giron AM, Mitre AI, Figueira ER, Arap S. Genital trauma due to animal bites. *J Urol*. 2000;165(1):80-83.
3. Cummings JM, Boullier JA. Scrotal dog bites. *J Urol*. 2000;164(1):57-8.
4. Garrett RA. Pediatric urethral and perineal injuries. *Pediatr Clin North Am*. 1975;22(2):401-6.
5. Tarman GJ, Kaplan GW, Lerman SL, McAleer IM, Losasso BE. Lower genitourinary injury and pelvic fractures in pediatric patients. *Urology*. 2002; 59(1):123-6; discussion 126.
6. Holland AJ, Cohen RC, McKertich KM, Cass DT. Urethral trauma in children. *Pediatr Surg Int*. 2001;17(1):58-61.
7. Pichler R, Fritsch H, Skradski V, Horninger W, Schlenck B, Rehder P, Oswald J. Diagnosis and management of pediatric urethral injuries. *Urol Int*. 2012;89(2):136-42.

in a child. We presented the third case of such an injury, supporting the previous reports recommending a surgical approach for penetrating urethral injuries. We encourage strict adherence to the principles of hypospadias repair during the reconstruction of the urethral defect and also broad spectrum antibiotics to cover canine oral flora. A Foley catheter should stent the urethra for at least a week to facilitate healing and the patient should have close follow-up for at least six months postoperatively.

Acknowledgements

The author(s) declare that they have no competing interests and financial support.

8. Hadidi AT, Azmy AF: Hypospadias Surgery: An Illustrated Guide. Berlin Springer, 2003.
9. van der Horst C, Martinez Portillo FJ, Seif C, Groth W, Jünemann KP. Male genital injury: diagnostics and treatment. BJU Int. 2004;93(7):927-30.
10. Callaham ML. Treatment of common dog bites: Infection risk factors. JACEP 1978;7:83-7.
11. Hornor G. Ano-genital warts in children: Sexual abuse or not? J Pediatr Health Care. 2004;18(4):165-70.

Access this article online

<http://pediatricurologycasereports.com>

Quick Response Code

