

## Recurrent ischemic priapism: A rare adverse event after human chorionic gonadotropin treatment in a three years-old boy with cryptorchidism

Adem Emrah Coguplugil<sup>1</sup>, Ali Guragac<sup>2</sup>, Salih Hamcan<sup>3</sup>, Emin Aydur<sup>1</sup>

<sup>1</sup>Gülhane Military Medical Academy, Department of Urology, Ankara, Turkey

<sup>2</sup>Tatvan Military Hospital, Department of Urology, Bitlis, Turkey

<sup>3</sup>Gülhane Military Medical Academy, Department of Radiology, Ankara, Turkey

### Abstract

We present the first case of human chorionic gonadotropin (hCG) induced recurrent ischemic priapism in a 3 years-old boy in the English literature. The patient underwent second right orchidopexy and hCG treatment (1500 IU twice a week for three weeks) was initiated the day after the operation. Twenty-three days after the last injection, he presented to our clinic with the complaint of painless erections. After the diagnosis of ischemic priapism, conservative management and oral diazepam therapy was initiated and the result was successful. hCG therapy may rarely cause recurrent ischemic priapism in children.

### Keywords

Diazepam; human chorionic gonadotropin; ischemic priapism; testosterone.

Copyright © 2016 [pediatricurologycasereports.com](http://www.pediatricurologycasereports.com).

### Corresponding Author:

Adem Emrah Coguplugil, MD.

Gülhane Military Medical Academy,

Department of Urology, Ankara, Turkey

E-mail: [adememrah@gata.edu.tr](mailto:adememrah@gata.edu.tr)

Accepted for publication: 24 April 2016

### Introduction

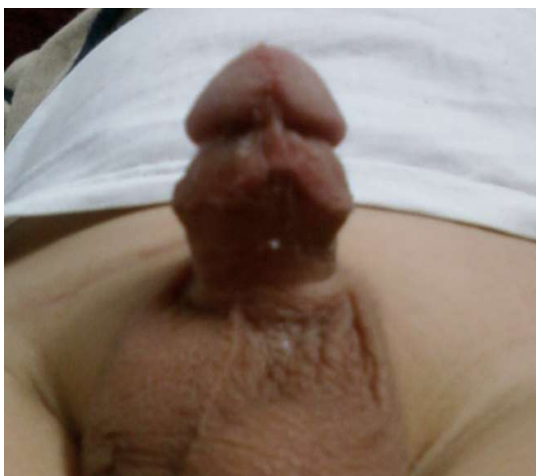
Priapism is described as prolonged full or partial penile erection lasting more than 4 hours unrelated to sexual stimulus [1]. It is a rare condition in children. Types of priapism are as follows: ischemic (low-flow or veno-

occlusive), stuttering (intermittent or recurrent ischemic), and non-ischemic (high-flow or arterial) [2]. Ischemic priapism is the most common type seen in children, mainly due to sickle-cell disease (SCD). On the other hand, androgen replacement therapy may cause ischemic and non-ischemic priapism. The exact mechanism of testosterone induced priapism is not clear. Mild increased frequency/duration of erections is a well-known side-effect of

testosterone [3]. Human chorionic gonadotropin (hCG) induce testicular descent by stimulating testosterone and/or dihydrotestosterone production and can be used in children with cryptorchidism [4]. To our knowledge, hCG induced recurrent ischemic priapism is not reported before in the English literature. Here we report a case of recurrent ischemic priapism in 3 years-old boy after hCG treatment for right cryptorchidism.

### Case Reports

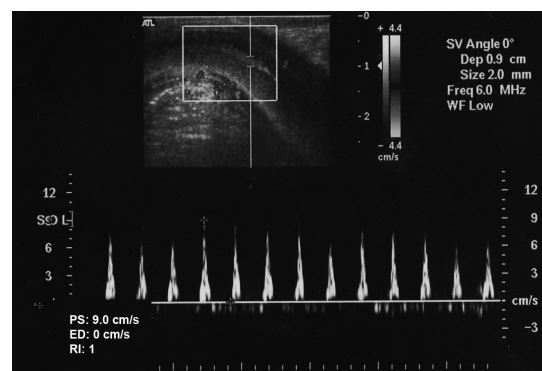
A 3 years-old boy with the complaint of semi-rigid, painless, and prolonged (>4 hours) erection was presented to our clinic [Fig. 1].



**Fig. 1.** Priapism episode at the presentation.

The patient was underwent second right orchiopexy 45 days ago and hCG treatment (Pregnyl®, 1500 IU twice a week for three weeks) was initiated the day after the

surgery. First priapism episode occurred 23 days after the last hCG injection and repeated one more time. There was no history of perineal trauma, malignancy, SCD or use of other medications. Right testis was palpated at the outer ring of the inguinal canal and relatively hypoplastic when compared to left testis. Left testis was normal. At the time of presentation hormone levels and complete blood count results were as follows; FSH: 0,948 mIU/mL (range: 0,2-3 mIU/mL), LH: 0,107 mIU/mL (range: 0,2-5 mIU/mL), total testosterone: 2,00 ng/dL (range: 0,1-0,2 ng/dL), free testosterone: 0,72 pg/mL (range: 0,15-0,6 pg/mL), prolactine: 9,63 ng/mL (range: 4,6-16,5 ng/mL), white blood cell: 11.6 (range: 4-11 K/uL), platelet count: 521 (range (150-420 K/uL). Abdominal ultrasonography was normal. Penile duplex ultrasonography (PDU) demonstrated decreased flow velocity and increased resistive index (RI) of the cavernosal artery [Fig. 2].



**Fig. 2.** Penile duplex ultrasonography examination during penile erection revealed

decreased flow velocity and increased resistive index (RI) values of the cavernous artery. Peak-systolic velocity (PS): 9cm/s, end-diastolic velocity (ED): 0 cm/s and RI=1. We used a high-end ultrasound machine (Logic 9, GE Healthcare, Milwaukee, WI, USA) with a multifrequency linear array transducer (5-13 MHz).

There was no arteriovenous fistula. These radiological findings suggested low flow (ischemic) priapism [5]. SCD and leukemia were excluded by normal hemoglobin electrophoresis and peripheral blood smear. We did not perform cavernosal blood aspiration. Diazepam therapy was initiated (0,8 mg/kg/day) and used for two weeks. Recurrent prolonged, painless nocturnal erections were occurred two times in consequent two nights after the initiation of diazepam therapy and then disappeared. No priapism episode occurred again. The patient was discharged to home after 2 weeks. Tertiary right orchidopexy was successfully performed 2 months after discharge.

### **Discussion**

Priapism is an emergency condition that requires immediate diagnosis and appropriate treatment to prevent the development of corporal fibrosis and future erectile dysfunction (ED). Ischemic priapism is a persistent, painful erection

marked by rigidity of the corpora cavernosa and by little or no cavernous arterial inflow, resulting in corporal hypoxia and tissue ischemia, hypercapnia, and acidosis. It accounts for more than 95% of all priapism episodes. The most common cause of ischemic priapism in children is SCD. Other common causes are leukemia, trauma, idiopathic, and pharmacologically induced [2]. Nonischemic priapism is much rarer than ischemic priapism, etiology is largely attributed to trauma, and intervention is not urgent and often unnecessary. Pain is never as severe as in an ischemic priapism; the erection is not as rigid, and pulsation may be visible in the penis [6].

The most common pharmaceutical agents causing priapism include intracavernous and oral treatments for ED, psychotropic drugs, arterial vasodilators, and hormones like testosterone. hCG induce testicular descent by increasing weight and vascularity of testis and also by stimulating testosterone and/or dihydrotestosterone production and can be used in children with cryptorchidism [4]. Acne, enlargement of penis and testes, growth of pubic hair, rapid increase in height, bloating, stomach and pelvic pain, decreased amount of urine are some of the side effects of hCG, which are associated with high testosterone levels. Although testosterone may cause ischemic and

nonischemic priapism, it is extremely rare despite the association between increased frequency and duration of erection and testosterone [2,7]. On the other hand, the mechanism of testosterone induced priapism is not clear. Intramuscular administration of testosterone leads to a supraphysiological increase in total serum testosterone, with peak levels being achieved within 48 hours and a return to baseline occurring at approximately 21 days. Therefore, there is a significant period during which high levels of circulating testosterone are present. It has been shown that supraphysiological levels of testosterone may predispose men to polycythemia and subsequent thrombosis as a result of stimulation of erythropoiesis. Also, an increase in local testosterone levels may result in an increased susceptibility to priapism [7]. On the other hand, androgens are key players in the physiology of nocturnal erections [3]. Men with low testosterone levels have lower nocturnal erection testosterone thresholds. In early puberty, gonadotropins are only released during rapid eye-movement sleep, which results in peak testosterone levels and nocturnal erections [8]. To our knowledge, hCG induced recurrent ischemic priapism in a healthy boy with cryptorchidism is not reported before in the English literature. There is only one article regarding hCG

induced priapism in German literature [9]. In our case, we thought that supraphysiological levels of testosterone (testosterone level was tenfold higher than normal level) related nocturnal erections triggered recurrent ischemic priapism. Also, SCD and other risk factors for priapism were excluded. Although the symptom of painless erection was suggesting non-ischemic priapism, radiological findings confirmed recurrent ischemic priapism.

Analgesics, physical exercise, urination, a cold bath, and fluids can be used as conservative management in priapism. Many drugs can be used in recurrent ischemic priapism in children (Pseudoephedrine, Terbutaline, Baclofen etc.) [2]. On the other hand, no treatment of choice has been established due to the limited data with regard to recurrent ischemic priapism [10]. Benzodiazepines such as diazepam also can be used in the conservative management of ischemic or recurrent priapism [10]. Diazepam may be used short-term as muscle relaxants reducing the tone of skeletal muscle. In our case, we did not perform invasive therapy to avoid corporal fibrosis. Diazepam therapy was initiated (0.8 mg/kg/day). After the initiation of diazepam therapy, recurrent priapism episodes disappeared in two days and never occurred again.

In conclusion, this is the first case of hCG induced recurrent ischemic priapism in a boy in the English literature. hCG treatment in boys may rarely cause recurrent ischemic priapism. Discontinuation of hCG and initiation of diazepam therapy may be adequate in hCG induced recurrent ischemic priapism in children.

### References

1. Broderick GA, Kadioglu A, Bivalacqua TJ, Ghanem H, Nehra A, Shamloul R. Priapism: pathogenesis, epidemiology, and management. *J Sex Med.* 2010; 7(1 Pt 2): 476-500.
2. Donaldson JF, Rees RW, Steinbrecher HA. Priapism in children: a comprehensive review and clinical guideline. *J Pediatr Urol.* 2014; 10(1):11-24.
3. Montorsi F, Oettel M. Testosterone and sleep-related erections: an overview. *J Sex Med.* 2005; 2(6):771-84.
4. Kucharski P, Niedzielski J. Neoadjuvant human Chorionic Gonadotropin (hCG) therapy may improve the position of undescended testis: a preliminary report. *Cent European J Urol.* 2013; 66(2):224-8.
5. Halls JE, Patel DV, Walkden M, Patel U. Priapism: pathophysiology and the role of the radiologist. *Br J Radiol.* 2012; (85):79-85.
6. Pryor J, Akkus E, Alter G, Jordan G, Leuret T, Levine L, et al. Priapism. *J Sex Med.* 2004; 1(1):116-20.
7. Shergill IS, Pranesh N, Hamid R, Arya M, Anjum I. Testosterone induced priapism in Kallmann's syndrome. *J Urol.* 2003; 169(3):1089.
8. Donaldson JF, Davis N, Davies JH, Rees RW, Steinbrecher HA. Priapism in teenage boys following depot testosterone. *J Pediatr Endocrinol Metab.* 2012; 25(11-12):1173-6.
9. Asbach HW, Kösters S, Thomas P, Mühlenberg R, Melekos M. Priapism in childhood (author's transl). *Monatsschr Kinderheilkd.* 1981; 129(10):585-8.
10. Molina ER, Rodriguez FE, Lledo GE, Tabares JJ, Husillos AA, Hernandez FC. Stuttering priapism: case report and

### Acknowledgements

The author(s) declare that they have no competing interests and financial support

bibliographic review. Arch Esp Urol.  
2010; 63(7):559-62.

Access this article online

<http://pediatricurologycasereports.com>

Quick Response Code

