

## Association of posterior urethral valve with congenital lobar emphysema: A case report

Clecio Piçarro, Thiago Luiz do Nascimento Lazaroni, Fabio Mendes Botelho Filho, Marcelo Eller Miranda, Atila Magalhães Victoria, Paulo Custódio Furtado Cruzeiro

*Department of Pediatric Surgery, Clinics Hospital of Faculty of Medicine, University Hospital Federal University of Minas Gerais Belo Horizonte, Brazil*

### Abstract

Posterior Urethral Valve (PUV) is the most common cause of bladder outlet obstruction in boys, with an incidence of 1 in 5,000 to 8,000 male births. Congenital lobar emphysema (CLE) is an uncommon cause of congenital pulmonary airway malformation, with an incidence 1 per 20,000 to 30,000 deliveries. These congenital malformations have never been described together before. A boy newborn with prenatal suspicion of PUV, confirmed in first days of live presented respiratory distress that lead CLE diagnosis. Our multidisciplinary team submitted him to a two-step surgery correction successfully.

### Keywords

Posterior urethral valve; congenital lobar emphysema; child.

*Copyright © 2016 pediatricurologycasereports.com..*

### Corresponding Author:

*Dr. Thiago Lazaroni*

*Hospital das Clínicas da UFMG - 6º Oeste -*

*Cirurgia Pediátrica Av. Alfredo Balena 110 – Santa*

*Efígenia Belo Horizonte, Brazil*

*E-mail: [lazaroni@ufmg.br](mailto:lazaroni@ufmg.br)*

*Accepted for publication: 01 March 2016*

### Introduction

Posterior Urethral Valve (PUV) is the most common cause of bladder outlet obstruction in boys, with an incidence of 1 in 5,000 to

8,000 male births [1]. Because of the severity of bilateral renal dysplasia in some cases, there is respiratory distress secondary to pulmonary hypoplasia and it may be the primary manifestation in newborn period. The association of PUV with other anomalies is uncommon, and the majority of them is located in urinary tract, and is consequence by the PUV itself, like vesicoureteral reflux [1].

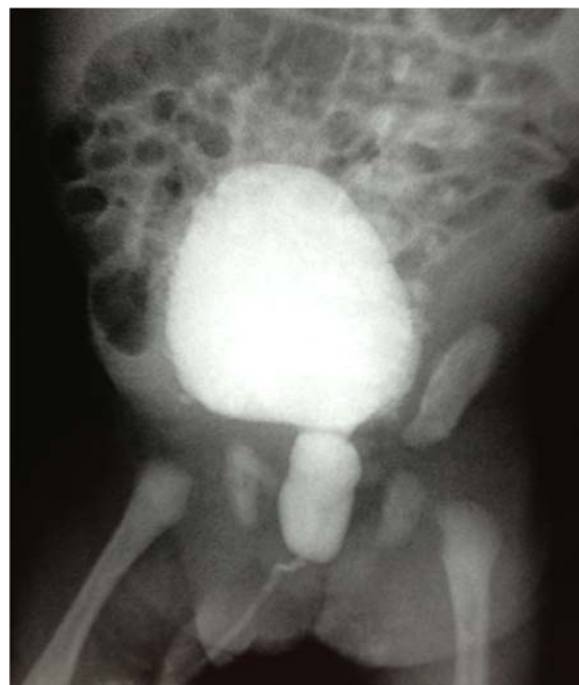Congenital lobar emphysema (CLE) is an uncommon cause of congenital pulmonary airway malformation, with an incidence of 1 per 20,000 to 30,000 deliveries. The main presentation is in the neonate or infancy with variable respiratory distress. Association of CLE and others anomalies is rare, if present, most often cardiac [2].

The objective of this manuscript is to present a case with the association between PUV and CLE, which was never previously described.

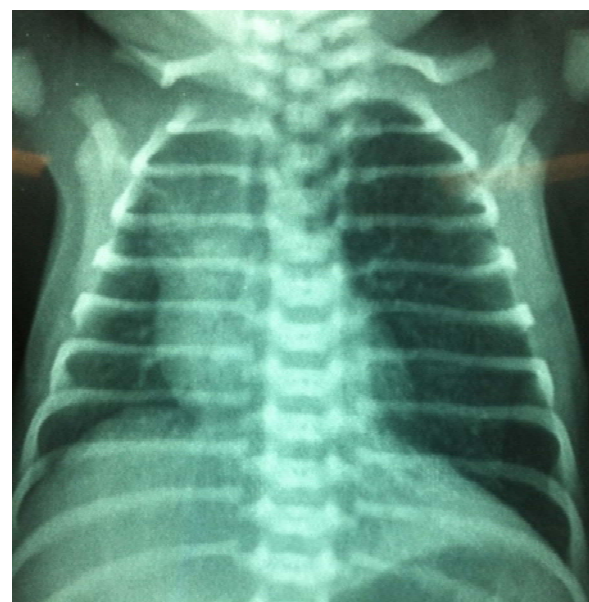
### Case report

A preterm 34-gestation week's male newborn weight 2,800 g and did well after delivery. The PUV suspicion was raised due an obstetric ultrasonography that showed oligohydramnios, megabladder and bilateral urethero-hydronephrosis. In the first days of life child underwent an ultrasonography and a voiding cystourethrography that confirmed the PUV [Fig.1]. In the first hours of life a bladder catheter was inserted softly. The creatinine levels were serially controlled for five days. No laboratory signals of renal impairment were found so then endoscopic treatment was programmed. But in the seventh day of life, the baby suddenly presented with tachypnea and hypoxemia. The thorax radiography showed over

distention of the left lung, which caused contra lateral mediastinal shift [Fig 2].

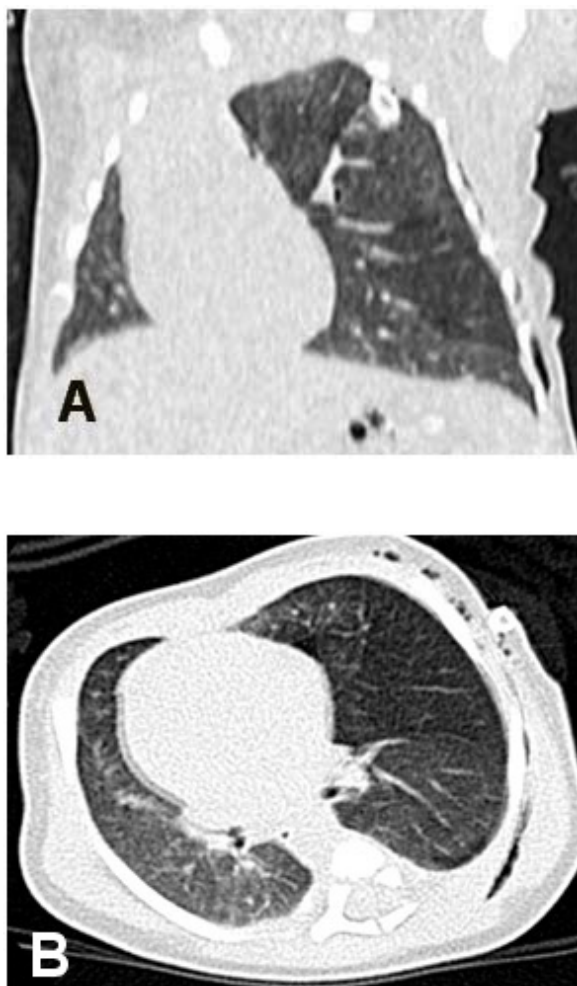


**Fig. 1.** Voiding cystourethrography confirming PUV.



**Fig. 2.** Thorax radiography showing overdistention of the left pulmonary parenchyma and contralateral mediastinal shift.

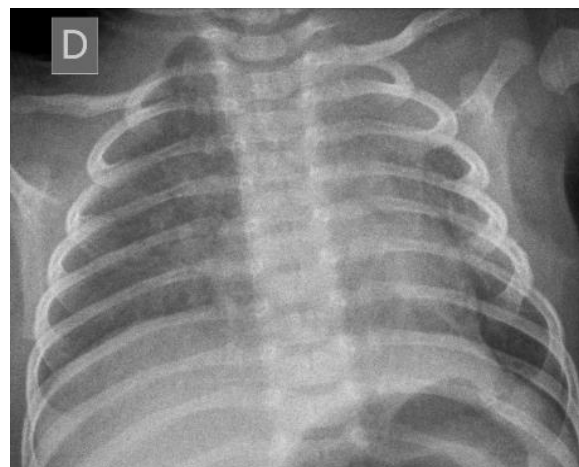
The hypothesis of CLE was confirmed by a computed tomography scan, which showed a hyperinflation of upper left lobe [Fig. 3A,B].



**Fig. 3.** CT scan confirming the diagnosis of CLE.

As the child kept the severe respiratory distress, all the efforts were to treat the CLE till he was clinically stable. So in the 9<sup>th</sup> day of life the child was submitted to a left thoracotomy that confirmed the emphysema in the upper lobe, and an upper lobectomy was successfully done. The child had no problems in the post-operative period. The

thorax radiography done after this operation showed the resolution of the mediastinal shift [Fig. 4].



**Fig. 4.** Thorax radiography after the left lobectomy, with resolution of the mediastinal shift.

As he did well in the first operation, the endoscopic treatment of the PUV was done six days later, also with no difficulties and with no problems in the postoperative period.

The child evolved with no respiratory problems and with a good urine flow. A new urinary ultrasonography showed moderate bilateral ureterohydronephrosis, and normal creatinine serum levels were found at blood samples. He was discharged four days later of the PUV endoscopic treatment.

### Discussion

Here we described for first time in literature the association of PUV and CLE, which are two uncommon congenital malformations.

In PUV the association of other anomalies could be related to the urinary tract, as result of the congenital obstructive uropathy, and is related also with inguinal hernia, cryptorchidism, anorectal anomalies, hemivertebrae, and spina bifida [3,4].

In CLE the main associate anomalies are cardiac, but there are some descriptions of association with broncogenic cyst, omphalocele, pectus excavatum, diaphragmatic hernia, hiatal hernia, chondroectodermal dysplasia and pyloric stenosis [5,6].

In this specific case, because the paucity of associate anomalies in the PUV, all the work up of the newborn was initially to confirm the prenatal suspicion of PUV, and to

observe the evaluation of the severity of the disease.

As both diagnosis were certain, the aim was initially to perform both surgeries in the same time. However, after multidisciplinary discussion the plan was changed and a sequential approach was performed, aim to solve first the respiratory threat, especially to a premature newborn.

So, the intention of this manuscript is to report, at first time in literature, this unusual association, and the importance to program properly the surgical strategy and the clinical support, with a multidisciplinary assistance.

#### Acknowledgements

The author(s) declare that they have no competing interests and financial support.

#### References

1. Malin G, Tonks AM, Morris RK, Gardosi J, Kilby MD. Congenital lower urinary tract obstruction: a population-based epidemiological study. *BJOG*. 2012;119(12):1455-64.
2. Correia-Pinto J, Gonzaga S, Huang Y, Rottier R. Congenital lung lesions--underlying molecular mechanisms. *Semin Pediatr Surg*. 2010;19(3):171-9.
3. Heikkilä J, Taskinen S, Toppari J, Rintala R. Posterior urethral valves are often associated with cryptorchidism and inguinal hernias. *J Urol*. 2008; 180(2):715-7.
4. Rajab A, Freeman NV, Patton M. The frequency of posterior urethral valves in Oman. *Br J Urol*. 1996; 77(6):900-4.
5. Karnak I, Senocak ME, Ciftci AO, Buyukpamukçu N. Congenital lobar emphysema: diagnostic and therapeutic considerations. *J Pediatr Surg*. 1999; 34(9):1347-51.
6. Khemiri M, Khaldi F, Ben Becher S, Chaouachi B, Houissa T, Barsaoui S.

Congenital lobar emphysema. Report of 17 cases. Tunis Med. 2008;86(4): 373-7.

Access this article online

<http://pediatricurologycasereports.com>

Quick Response Code

