

## Fibroepithelial polyp of vagina in a two-year-old girl and review of the literature

Alev Suzen<sup>1</sup>, Nazile Erturk<sup>1</sup>, Ozgur Ilhan Celik<sup>2</sup>

<sup>1</sup> Department of Pediatric Surgery, Faculty of Medicine, Mugla Sıtkı Kocman University, Mugla, Turkey

<sup>2</sup> Department of Pathology, Faculty of Medicine, Mugla Sıtkı Kocman University, Mugla, Turkey

### Abstract

Fibroepithelial polyp of vagina (FEPV) is a mucosal polypoid lesion with a fibro vascular stalk and oedematous or hypocellular stroma covered by squamous epithelial surface. FEPV is extremely rare before menarche and after menopause. This article describes a two year old girl with a vaginal polyp and the histological analysis of which revealed to be a FEPV. Surgical excision of the mass was performed, and in 1 year of follow-up no recurrence was detected. A review of the literature showed that there were four cases of FEPV in neonatal girls. While these reported cases were neonatal, our case is the first case of FEPV in a two year old girl.

### Keywords

Child; fibroepithelial polyp; vagina.

Copyright © 2016 [pediatricurologycasereports.com](http://www.pediatricurologycasereports.com).

**Corresponding Author:** Alev Suzen, M.D.,  
Department of Pediatric Surgery,  
Faculty of Medicine, Mugla Sıtkı Kocman University,  
Mugla, Turkey  
E-mail: [alevsuzen@hotmail.com](mailto:alevsuzen@hotmail.com)  
Accepted for publication: 25 January 2016

cyst, hydro (metro) colpos, botryoid sarcoma of the vagina and FEPV [2,3]. We have to distinguish the origin (genital or urological) of the interlabial masses with good clinical examinations [3].

### Introduction

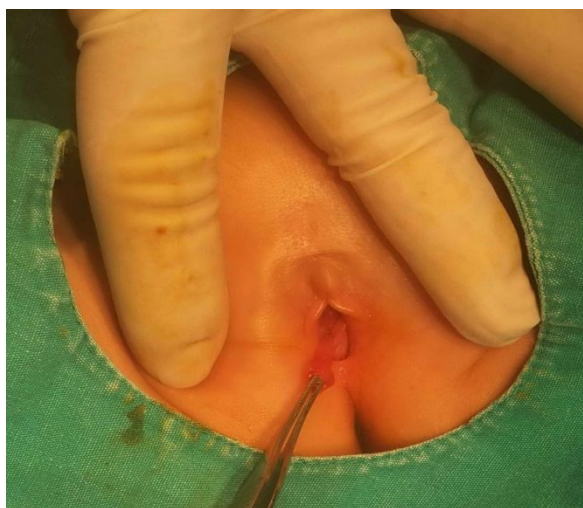
A fibroepithelial polyp of vagina (FEPV) in an infant girl is extremely rare [1]. Common interlabial masses in infants and little girls include prolapsed ectopic ureterocele, prolapsus of urethra, paraurethral Skene

### Case report

A two-year-old girl came to our hospital because of a vaginal polypoid mass which was discovered by her parents. She had no other systemic problems. The vaginal mass was discovered 6 months ago by her parents

and the parents said that vaginal mass was disappearing intermittently. On our first physical examination at the outpatient clinic, there was no vaginal mass as the vaginal mass entered inside the hymenal ring.

When the mass came out of the hymenal ring, physical examination revealed a 1.2x0.5 cm polypoid mass, with a tall neck, originating from superior vaginal wall [Fig. 1].

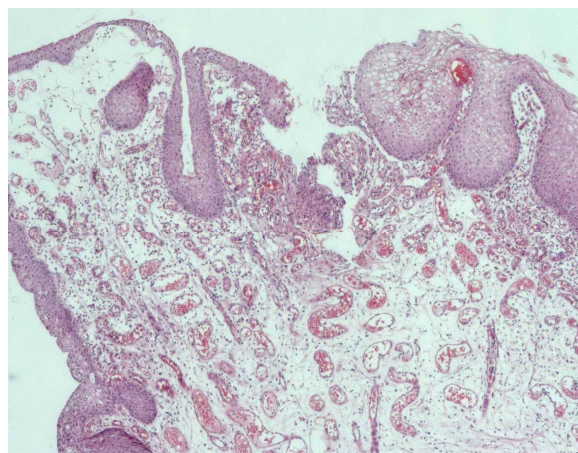


**Fig. 1.** A 1.2x0.5 cm polypoid mass, with a tall neck, originating from vaginal wall.

The other urogenital examination was normal. Palpation showed it was painless and there were no signs of bleeding and inflammation.

Surgical excision of the vaginal polyp was performed and great attention was paid to preservation of the hymenal ring. Histopathological findings showed a fibro epithelial polyp rich in vascular strictures

[Fig. 2]. After 1 year of follow-up, the patient has shown no recurrence.



**Fig. 2.** Fibroepithelial polyp of vagina with a fibrovascular stroma containing congestive vascular structures covered by benign epithelial surface, (H&Ex40).

### Discussion

A FEPV is a polypoid lesion with a central fibro vascular core covered by squamous epithelium. Stroma may be oedematous, hypo cellular, or mixoid [4, 5]. FEPV is rare and is mostly seen in adult women or neonates. It is suggested that FEPV occur due to hormonally induced hyperplasia of subepithelial connective tissue or end stage of granulation tissue as a result of local injury. It is a benign procedure. During pregnancy, these lesions may be enlarged [4, 5].

Hymenal polyps are seen in the neonatal period and early childhood. They are probably due to oestrogen stimulation in the fetal period. Most of them disappear

spontaneously within a few weeks. Hymenal polyps originate from vaginal hymenal ring [6]. As polypoid formation in our case originates from inside of the hymenal ring, we eliminated hymenal polyp.

Tubulo-squamous polyp of vagina has been described recently as a rare benign lesion. It is histologically characterized by both epithelial and mesenchymal component, embedded in a fibrous stroma [7]. It has not been detected in a child in the literature.

After reviewing the literature, we found four cases of a FEPV in neonates: In 1990, Pul et al [8], in 2008 Jallouli et al [9], in 2010 Calleja et al [3], in 2015 Abdulhakim et al [1]. Our case is the first case of FEPV in a two year old girl.

A FEVP should be considered in interlabial masses in prepubertal girls [8]. Therapy involves excision of the polyp [9]. As, the presentation of sarcoma and polyp could be similar, histological analysis is important

[3]. Although it is benign and rarely recurs, it must be eliminated from botryoid sarcoma by histopathological examination [1, 3].

### Conclusion

A FEPV is most seen in adult women. A few neonates were reported as a FEPV, but like in our case FEPV should be regarded in differential diagnosis of the interlabial masses at any age.

### Acknowledgements

The author(s) declare that they have no competing interests and financial support.

### References

1. Alotay AA, Sarhan O, Alghanbar M, Nakshabandi Z. Fibroepithelial vaginal polyp in a newborn. *Urology Ann.* 2015;7(2):277-78.
2. Nussbaum AR, Lebowitz RL. Interlabial masses in little girls: review and imaging recommendations. *AJR Am J Roentgenol.* 1983;141(1):65-71.
3. Calleja Aguayo E, Delgado Alvira R, Elias Pollina J, Romeo Ulecia M, Gonzalez Esqueda A, Esteban Ibarz JA. Differential diagnosis of the interlabial masses in girls under 5 years old. *Cir Pediatr.* 2010;23(1):28-31.
4. Mucitelli DR, Charles EZ, Kraus FT. Vulvovaginal polyps. *Histologic*

- appearance, ultrastructure, immunocytochemical characteristics, and clinicopathologic correlations. *Int J Gynecol Pathol.* 1990;9(1):20-40.
5. Halvorsen TB, Johannesen E. Fibroepithelial polyps of the vagina: are they old granulation tissue polyps? *J Clin Pathol* 1992;45(3):235-40.
  6. Borko E, Dosen M, Kavalar R, Pivec G, Zebeljan I. A large hymenal polyp in a 21-year-old virgin. *Acta Dermatovenerol Alp Pannonica Adriat.* 2009;18(4):173-75.
  7. Şahin S, Yılmaz I.B, Erdem Ö. A rare lesion of the vagina: tubulo-squamous polyp. *Gaziantep Med J.* 2014;20(4):332-34.
  8. Pul M, Yılmaz N, Gürses N, Ozoran Y. Vaginal polyp in a newborn-a case report and review of the literature. *Clin Pediatr (Phila).* 1990;29(6):346.
  9. Jallouli M, Trigui L, Gargouri A, Mhiri R. Vaginal polyp in a newborn. *Eur J Pediatr.* 2008;167(5):599-600.

**Access this article online**

<http://pediatricurologycasereports.com>

**Quick Response Code**

