

## Complete separation of the testis and epididymis in an undescended testis: A case report

Ryuta Watanabe, Takeshi Sugahara, Hitoshi Hamada

Department of Urology, Ehime Prefectural Imabari Hospital, Ehime, Japan

### Abstract

We report a case of the complete separation of the testis and epididymis in an undescended testis, which is a very rare phenomenon. It is a situation associated with an undescended testis and appears to be one of the cases of fusion abnormalities. In all reported cases, vas deferens and epididymis or the vas deferens alone were located more distally than the undescended testis. In our case, histological examination of the left vas-epididymis complex showed rete testis-like tubular tissue which has a risk for malignant transformation. Long-term observation is essential.

### Keywords

Complete separation; testis; epididymis; undescended testis.

Copyright © 2016 [pediatricurologycasereports.com](http://www.pediatricurologycasereports.com).

**Corresponding Author:** Ryuta Watanabe

Department of Urology, Ehime Prefectural Imabari Hospital, Ishiicho 4choume 5-5, Imabari City, Ehime 794-0006, Japan

E-mail: [ryuta\\_w\\_pooh@yahoo.co.jp](mailto:ryuta_w_pooh@yahoo.co.jp)

Accepted for publication: 11 December 2015

### Introduction

Complete separation of the epididymis from the testis is a very rare congenital anomaly, and it usually discovered during surgery for cryptorchidism [1,2]. Although this malformation has been reported sporadically, the incidence in patients with cryptorchidism may be higher [1]. Hence,

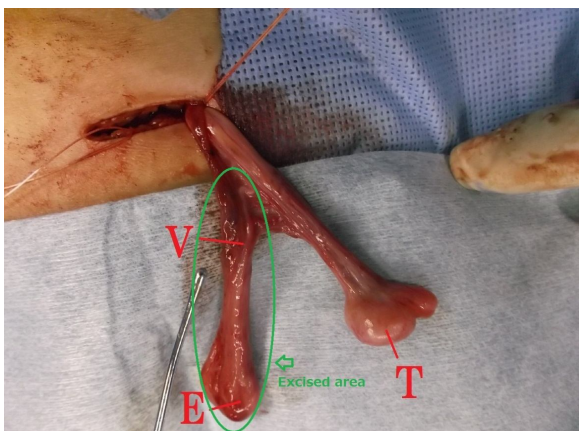
epididymal anomalies seem to play an important role in the emergence of fertility disorders in cases with congenital cryptorchidism [3]. We report a case of the complete separation of the testis and epididymis in an undescended testis, which is a very rare phenomenon.

### Case report

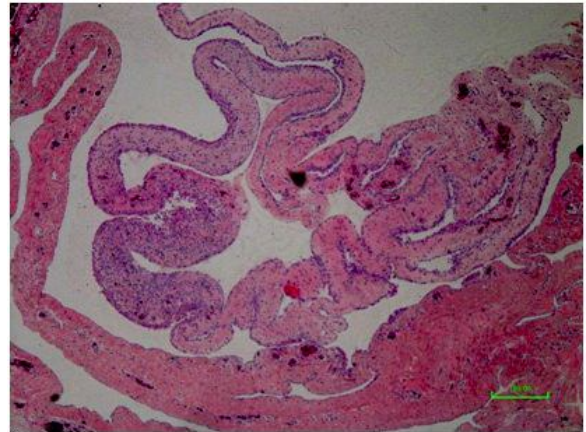
A healthy 22-month-old boy was referred with a nonpalpable left gonad and a right migratory testis. On the examination of the external genitalia, right testis was located normally at the bottom of the right

hemiscrotom, but left testis showed non-palpable testis with underdeveloped left hemiscrotum. Bilateral orchiopexy was performed through an inguinal incision. Within the left inguinal canal, the tissue that was initially suggestive of the vas deferens and an atrophied testis was identified, and there was no spermatic vessel and normal testis. In addition, an indirect inguinal hernia sac was identified. When the sac was opened, a normal-appearing abdominal testis was identified proximal to the internal ring. The testis appeared normal in size with spermatic vessels, however, it showed no vas deferens or epididymis [Fig. 1]. The right testis was absolutely normal.

The inferior tissue mass was excised, and its histological examination showed a normal epididymis and vas deferens, however a very small portion of the left vas-epididymis complex showed rete testis-like tubular tissue [Fig. 2]. The patient did well postoperatively for 5 months.



**Fig. 1.** Operative photograph demonstrates the left vas-epididymis complex and left testis. T: testis V: vas deferens E: epididymis. Arrow: Excised area.



**Fig. 2.** Microscopic image of the left vas-epididymis complex shows rete testis-like tissue in very small area of the section.

### Discussion

The first reported case of complete separation of the testis and epididymis was described by Lazarus and Marks in 1947 [4]. These investigators insisted that the complete failure of fusion of the testis and epididymis was probably the rarest anomaly shown by the testis. An abnormal epididymis or epididymal-testicular interaction may play a role in inhibiting the descent and final maturation of the gonad, as observed in our case. Dean et al [5] reported a 1.2% complete separation of the testis and the epididymis in a cohort of patients with an undescended testis, and insisted that fusion with the epididymis was essential for normal descent. In a study of epididymal and testicular anomalies and those associated with undescended testis, Mollaeian et al [6] reviewed 652 reports of surgical explorations for undescended testis in 558 children. In that cohort of patients,

fusion abnormalities of the testis and epididymis were noted in 235 (36%). These abnormalities included anomalies in ductal fusion and suspension. The complete separation of the testis and epididymis was found in 33 (5%) of the patients. To our knowledge, ours is the first case in which the histological examination of the excised specimen showed testicular tissue suspected of being malignant.

Embryogenesis of the male gonad, epididymis, and vas deferens is a complex sequence of events [7]. The testis develops from the medullary sex cords at the genital ridge. The epididymis and the vas deferens develop from the mesonephric ducts and the Wolffian ducts, respectively. This union is finally accomplished by the canalization of the mesonephric ducts and the rete testis. Failure of this cascade can lead to a continuum of fusion, suspension, and descent abnormalities ranging from simple segmental atresia of the vas deferens to the complete separation of the epididymis from the testis [8].

## References

1. Vázquez Medrano A, Fernández Fernández A, Gil Fabra J, et al. Complete separation between epididymis and testis associated with cryptorchism. Presentation of a case and review of the

When a vas-epididymis complex without an associated testis or spermatic vessels is identified, proximal exploration is warranted. If a proximal or intra-abdominal testis is located, orchidopexy is the standard of care to allow the monitoring of the testis. Whether the malignant change in the undescended testis is proportional to the degree of epididymal malformations, remains a topic for future studies [2]. And there is no case of the incidence of malignant transformation for a patient with rete testis-like tissue. However, when there is any evidence of testicular tissue in the excised specimen such as present case, close long-term follow-up for the generation of malignant tumors is necessary.

## Acknowledgements

We would like to thank the Ehime Urological Association for providing financial support.

There are no conflicts of interest.

literature. Arch Esp Urol. 1993;46(6):479-80.

2. Al-Arfaj AA, Al-Saflan AA. Complete separation of the testis and epididymis presenting as inguinal hernia. Saudi Med J. 2002;23(10): 1275-7.

3. Mohamed A Baky Fahmy. Rare Congenital Genitourinary Anomalies: An Illustrated Reference Guide. Springer-Verlag Berlin Heidelberg. 2015;pp.77.
4. Lazarus JA, Marks MS. Anomalies associated with undescended testis. Complete separation of a partly descended epididymis and vas deferens and an abdominal testis. J Urol. 1947;57(3): 567-74.
5. Dean AL, Major JW, Ottenheimer EJ. Failure of fusion of the testis and epididymis. J Urol. 1952;68(4):754-8.
6. Mollaeian M, Mehrabi V, Elahi B. Significance of epididymal and ductal anomalies associated with undescended testis: Study in 652 cases. Urology. 1994;43(6): 857-60.
7. Nowak K. Failure of fusion of epididymis and testicle with complete separation of the vas deferens. J Pediatr Surg. 1972;7(6):715-6.
8. Marshall FF, Shermeta DW. Epididymal abnormalities associated with undescended testis. J Urol. 1979;121(3): 341-3.

**Access this article online**

<http://pediatricurologycasereports.com>

**Quick Response Code**

