

A case of asymptomatic aortic aneurysm with saber sheath trachea, incidental findings

Babaji D Ghewade^{1,*}, Smaran Cladius², Swapnil Chaudhari³, Ulhas S Jadhav⁴

¹Professor, ^{2,3}Junior Resident, ⁴Associate Professor, Dept. of Respiratory Medicine, Datta Meghe Institute of Medical Sciences, Wardha, Maharashtra

***Corresponding Author:**

Email: bghewade@rediffmail.com

Abstract

Aortic dissection is a potentially fatal condition in which there is a tear in the wall of aorta. The “saber-sheath” trachea can be found in patients with chronic obstructive pulmonary diseases (COPD), but is rare in non COPD patients. Occurrence of these two conditions in a same patient is uncommon. Here we report a case of 75-year old male, known systemic hypertensive patient since 3 years, who came to Respiratory Medicine OPD for fitness for prostatectomy, found to have dissecting aortic aneurysm on CT angiogram with saber sheath trachea. Early diagnosis of this condition, followed by appropriate treatment avoided potential complications in the patient.

Keywords: Aortic Aneurysm, Saber sheath trachea, COPD, CT angiogram, Dissection.

Access this article online	
Website:	www.innovativepublication.com
DOI:	10.5958/2348-7682.2016.00017.8

Introduction

Thoracic Aortic Aneurysms (TAA) are associated with increased morbidity and mortality, especially when they lead to acute dissection (TAAD). They may be associated with bicuspid aortic valve, hypertension, Marfan syndrome (MFS) or Loeys-Dietz syndrome. Out of these, 20% of TAAD cases are found to have a genetic component leading to familial TAAD (FTAAD). Familial thoracic aortic aneurysms can be life-threatening as even much larger, advanced aneurysms may remain asymptomatic and so physicians should always be alert and keep high index of suspicion when rounded mediastinal lesions are found on chest radiographs. There should be screening of first degree relatives of patients with Familial Thoracic Aortic Aneurysm. Many such cases could be detected during routine screening or evaluation⁽¹⁻³⁾. The incidence is probably about 5-10 per 100,000 patient years. Prevalence may be at least 3-4 % of those >65 years, and is probably increasing.

The saber-sheath trachea is defined as narrowing of the intrathoracic trachea with internal coronal diameter two thirds or less than the sagittal diameter at the same level without any mediastinal pathology causing extrinsic compression⁽⁴⁾. Measurement of tracheal diameter should be taken 1 cm above the aortic arch. Ratio of the coronal and sagittal diameters is known as tracheal index. Tracheal index describes the degree of saber-sheath shape. On Computed tomography trachea

has a ring like ossification of cartilages⁽⁵⁾. It is a very uncommon that saber – sheath trachea occurs in a non COPD patient with aortic aneurysm.

Case History

A 75-year-old gentleman, a known systemic hypertensive since 3 years, on tab Amlodipine 5mg and tab Losartan 50mg OD, non-smoker and non-alcoholic came to Respiratory Medicine OPD for fitness for prostatectomy. He was complaining of breathlessness MMRC grade I since last 3 months. Other complaints were dribbling of urine, pain while micturition and increase frequency of micturition since last 2 months.

On examination, there was no clubbing, pallor, icterus, cyanosis, lymphadenopathy or pedal oedema. His pulse was 90/min, regular, normo-volumic and peripheral pulses were felt bilaterally and there was radio-radial delay. Respiratory rate was 22/min, blood pressure was 120/76 mmHg in right arm in supine position and oxygen saturation was 96% on room air.

Upper respiratory tract examination was normal except staining of teeth. In lower respiratory tract, trachea was central, normal vesicular breath sounds were heard over all lung areas. Heart sounds were normal and no murmurs were heard.

His lab investigations showed hemoglobin 12.1 gm%, WBC 6300/cmm and platelet counts were normal. Blood sugar, liver and kidney function tests were normal and ELISA test for HIV was nonreactive. Fasting lipid profile done was also normal.

Chest X Ray PA (Fig. 1) was suggestive of non-homogenous opacity arising from mediastinum (hilum) towards chest wall with size approx 6x6 cm s/o anterior mediastinal mass. There was mild left ventricular hypertrophy, normal left ventricular systolic function, grade I diastolic dysfunction, mild tricuspid regurgitation, aortic regurgitation 2+ and ejection

fraction of 68% on 2D echocardiography. CT AORTOGRAM (Fig. 2) done showed saccular aneurysm arising from arch of aorta distal to origin of the left subclavian artery, peripherally thrombosed, measuring 7.4 cm x 6.3 cm, enhancement of lumen on post contrast study measuring 5.3 cm x 3.8 cm and pulmonary arteries up to 4th order showing normal opacification with no filling defect/thrombi noted within it.

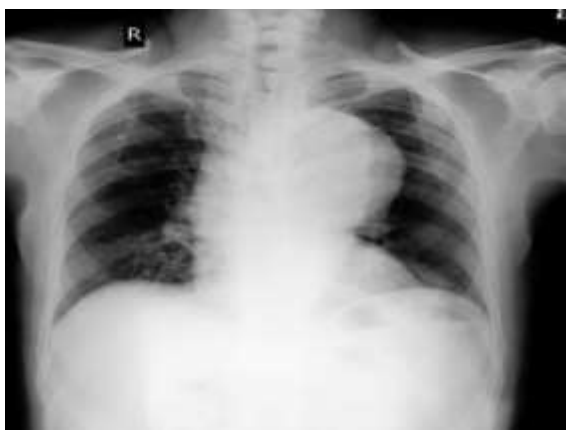

Fig. 1: X-Ray Chest PA view showing anterior mediastinal mass on left side

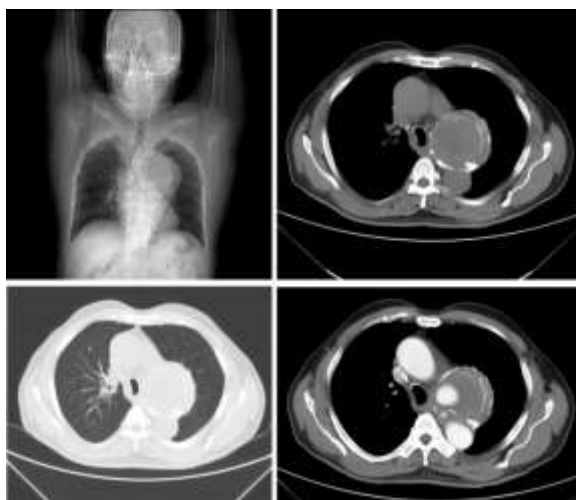


Fig. 2: CT- Aortogram showing dissecting aortic aneurysm with saber sheath trachea

Patient was referred to interventional radiology and endovascular stent grafting was done. CXR-PA after stent grafting is almost similar as compared to previous. Patient further underwent prostatectomy and is doing well.

Discussion

Majority of (75%) the thoracic aortic aneurysms are generally asymptomatic. Other symptoms may be chest pain, back pain, hoarseness, difficulty in swallowing and dyspnea depending upon the compression over adjacent structures⁽⁶⁻⁷⁾. In the present

case, patient was totally asymptomatic and came for fitness for prostatectomy. Early detection of aortic aneurysm or dissection is important or else it can lead to morbidity or mortality.

Atherosclerosis of aorta may be a risk factor for development of aortic aneurysms⁽⁸⁾. All layers of the aortic wall may be affected in the real aneurysms. Usually, pseudo aneurysms may occur as a postoperative complication or after trauma. In our case, there was a thoracic saccular aneurysm that involved all the layers of aorta. There were no symptoms suggestive of compression over adjacent structures and there was no significant past history that could have lead to aortic aneurysm.

It is yet not clear whether atherosclerosis leads to atherosclerotic aneurysms or vice versa. However, in our case we believe that the atherosclerosis was associated with the thoracic aortic aneurysm. Conditions like smoking, COPD, advanced age, pain and a diameter of more than 5 cm of the aorta increases the risk of aortic rupture⁽⁹⁾. In present case, despite of advanced age, hypertension and aortic diameter of 7.4 cm, patient didn't develop rupture of aneurysm and remained asymptomatic.

Till now it is not understood whether aneurysm should be treated first or the other pathology⁽¹⁰⁻¹¹⁾. Though most physicians think that symptomatic lesion should be treated on priority⁽¹²⁾. But if other symptoms are treated instead of aortic aneurysm, there remains the risk of rupture of aorta which could be fatal⁽¹³⁾. Some evidences suggest that elective Nephrectomy, Oophorectomy and Cholecystectomy can be performed simultaneously with Aortic aneurysm repair⁽¹⁴⁾. Recently, thoracic endovascular stent graft surgery under epidural anesthesia, is the preferred surgical modality for old TAA. It is associated with low morbidity, mortality and short duration of hospital stay⁽¹⁵⁻¹⁶⁾.

The normal shape of the trachea at various levels is variable. Gamsu and Webb studied different tracheal shapes with help of CT scans and documented that the most common shape was round or oval. Other abnormal shapes included horseshoe shape trachea with a flat posterior tracheal membrane, inverted pear and almost a square. "Saber-sheath" trachea is one of such abnormal deformities of trachea⁽¹⁷⁾.

In 1905 the pathologist Simmonds described a saber-sheath deformity in cadavers. He regarded it as a condition restricted to old men and called it Altersselscheidentrachea (saber-sheath-shaped trachea of old age). He did not recognize that the deformity was limited to the intrathoracic portion of the trachea. Although almost all of the patients in Simmonds's series had emphysema, he did not associate the deformity with obstructive airways disease⁽¹⁸⁾.

In the present case, saber-sheath trachea was an incidental finding on CT scan. By definition, abnormal tracheal shape should not be taken as saber-sheath

trachea when there is any external compression by mediastinal lesion. But in this case the trachea is convex at the level of the aortic aneurysm and the other side (right wall of trachea) is concave suggesting that there is no compression over trachea at the level of the aneurysm. Hence the abnormal tracheal shape with increased antero-posterior diameter can be considered as saber-sheath trachea.

Conclusion

Aortic aneurysm remains asymptomatic in most of the cases and is detected on evaluation of the individual for some other reasons. Saber-sheath trachea is the abnormal shape of the intrathoracic portion of trachea which correlates with hyperinflation of lungs. Nowadays, because of low morbidity, mortality and hospital stay, thoracic endovascular stent graft surgery, generally under epidural anesthesia, is the preferred surgical method in especially old TAA patients. Therefore, when rounded mediastinal shadows are found on chest radiographs, TAA should be kept in mind and attempts should be made to diagnose it early which will decrease mortality rates and will increase the quality of life for patients.

References

- Hiratzka LF, Bakris GL, Beckman JA, Bersin RM, Carr VF, Casey DE, et al. Guidelines for the diagnosis and management of patients with thoracic aortic disease: executive summary. *Circulation* 2010;121:266-369.
- Milewicz DM, Chen H, Park ES, Petty EM, Zaghi H, Shashidhar G, et al. Reduced penetrance and variable expressivity of familial thoracic aortic aneurysms/dissections. *Am J Cardiol.* 1998;82:474-9.
- Albomoz G, Coady MA, Roberts M, Davies RR, Tranquilli M, Rizzo JA, et al. Familial thoracic aortic aneurysms and dissections: incidence, modes of inheritance, and phenotypic patterns. *Ann Thorac Surg.* 2006;82:1400-5.
- Greene R, Lechner GL. Saber-sheath trachea: a clinical and functional study of marked coronal narrowing of the intrathoracic trachea. *Radiology.* 1975;115:265-268.
- Greene R. Saber-sheath trachea: relation to chronic obstructive pulmonary disease. *AJR Am J Roentgenol.* 1978;130:441-445.
- Joyce WJ, Fairbairn JF, Kincaid DW. Aneurysms of the thoracic aorta. A clinical study with special reference to prognosis. *Circulation* 1964;29:176-81.
- Tseng E. Thoracic Aortic Aneurysm Treatment and Management. *Medscape* Oct 2012. <http://emedicine.medscape.com/article/424904-treatment>.
- Isselbacher EM. Thoracic and abdominal aortic aneurysms. *Circulation* 2005;111:816-28.
- Hountis PG, Plestis KA. Strategies in the management of extensive descending and thoracoabdominal aortic aneurysms. *Hellenic J Cardiol* 2009;50:295-302.
- Findeis LK, Cody ME. Endovascular repair of thoracic aneurysms. *Semin Intervent Radiol* 2011;28:107-17.
- Abraha L, Romagnoli C, Montedori A; Thoracic stent graft versus surgery for thoracic aneurysm. *Cochrane Database Syst Rev* 2009 Jan 21;1:CD006796.
- Tilney HS, Trickett JP, Scott RA. Abdominal aortic aneurysm and gastrointestinal disease: should synchronous surgery be considered? *Ann R Coll Surg Engl* 2002;84(6):414-7.
- Swanson RJ, Littooy FN, Hunt TK, Stoney RJ. Laparotomy as a precipitating factor in the rupture of intraabdominal aneurysms. *Arch Surg* 1980;115:299-304.
- Rutherford RB. *Vascular Surgery*. Volume 2. 5th edition. Edited by: Cronenwett JL, Gloviczki P. Philadelphia-USA. W.B. Saunders Company;2000:1273.
- Bortone AS, De Cillis E, D'Agostino D. Endo vascular treatment of thoracic aortic disease: four years of experience. *Circulation* 2004;110:262-7.
- Stone DH, Brewster DC, Kwolek CJ. Stent-graft versus open-surgical repair of the thoracic aorta: mid-term results. *J Vase Surg* 2006;44:1188-97.
- Gamsu G, Webb WR. Computed tomography of trachea: normal Roentgenol. 1982;139:321-326.
- Simmonds M. Uber Altersbelscheidentrachea. *Virchows Arch (Pathol Anat)* 1905;179:15-28.