

A Rare Presentation of Recurrent and Profuse Postmenopausal Bleeding

Shubham Divya^{1*}, Kawthalkar Anjali²

¹Postgraduate student, ²Associate Professor, Dept. of Obstetrics and Gynecology, NKP Salve Institute of Medical Sciences & Research Centre, Digidoh Hills, Hingna Road, Nagpur-19.

***Corresponding Author**

E-mail: shubham.divya6@gmail.com

Abstract

The commonest cause of postmenopausal bleeding in India is carcinoma cervix. Other common causes are senile vaginitis, carcinoma endometrium, endometrial polyp and fibroid uterus. Sex-cord stromal tumours of the ovary are rarely responsible for postmenopausal bleeding but non-hormone producing ovarian tumour leading to profuse postmenopausal bleeding is very rare. Ovarian fibroma is uncommon. Here we present a case of 60-year-old woman who presented with profuse and recurrent episodes of postmenopausal bleeding with simple endometrial hyperplasia without atypia with ovarian fibroma (A misfit tumour).

Keywords: Misfit tumour, Ovarian fibroma, Postmenopausal bleeding.

Introduction

Ovarian sex-cord tumors are defined as tumors that arise from granulosa cells, theca cells, sertoli cells, leydig cells and fibroblasts of stromal origin⁽¹⁾. Ovarian fibroma is a solid tumour that belongs to sex-cord stromal tumors of the ovary and composed of variable amounts of collagen from entirely spindle, oval or round cells⁽²⁾. It is often difficult to diagnose preoperatively and usually misdiagnosed as uterine myoma, because of the solid nature of the mass on examination and the ultrasonographic similarities between the two⁽³⁾. Cases have been reported with evidence of hormonal activity when the histological pattern of the tumour bore no resemblance to any of those categories accepted as being composed of endocrine producing tissue. The present case is a case of 60-year-old woman presenting with recurrent profuse episodes of postmenopausal bleeding with a rare diagnosis of misfit tumour.

Case History

A 60-year-old P₂L₂ woman came with complaints of postmenopausal bleeding since 1 year. She had 2 episodes of profuse bleeding along with spotting on and off. Endometrial curettage (EC) was done 1 year back in which histopathology report showed proliferative endometrium. Menstrual and obstetric history was normal except that patient had one previous caesarean section. Patient was a known case of diabetes mellitus and hypertension. She was obese. Multiple lipomatosis were present all over the body. Blood pressure was 140/100 mm Hg. On abdominal examination, multiple lipomatosis were seen over abdomen. On per speculum examination, vagina was pink and rugosities were present. Cervix was healthy and Pap smear was suggestive of inflammatory smear. On per vaginal examination, uterus was bulky and exact size could not

be made out due to obesity and lipoma. Bilateral fornices were free and non-tender.

Ultrasonography report revealed uterine size of 7cm x 11cm x 5 cm, bulky, multiple heterogenous lesions seen within uterus, largest of size 4.3cm X 4.7 cm in posterior wall (s/o intramural fibroid), endometrial thickness – 1.8cm, thick, echogenic, displaced anteriorly. Bilateral adnexa clear. Both ovaries could not be visualized separately.

After preliminary investigations and adequate sugar control, repeat EC was done which showed simple endometrial hyperplasia without atypia on histopathology. By the time her hypertension and diabetes was controlled for major surgery, she was started on tablet Norethisterone 5mg TDS for control of profuse bleeding.

Total abdominal hysterectomy with bilateral salpingo-oophorectomy was done. On gross examination, uterus was enlarged up to 14 weeks with 2 large subserosal fibroids, each measuring 4cm x 5 cm. Right ovary and fallopian tube were normal. Left tube was normal. Left ovary was enlarged, 5cm x 4 cm, firm to hard in consistency (Fig. 1 and Fig. 2). Specimen was sent for histopathology. Her postoperative period was uneventful, suture removal was done on 8th day and she was discharged on 9th day.

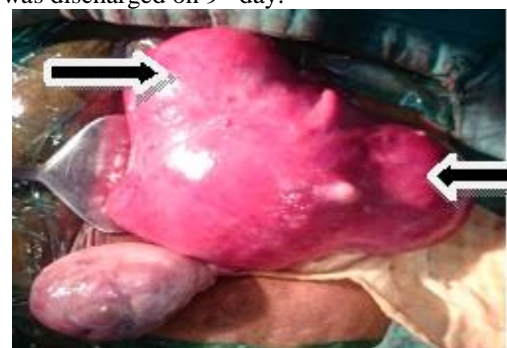

Fig. 1: Uterus with two subserosal fibroids

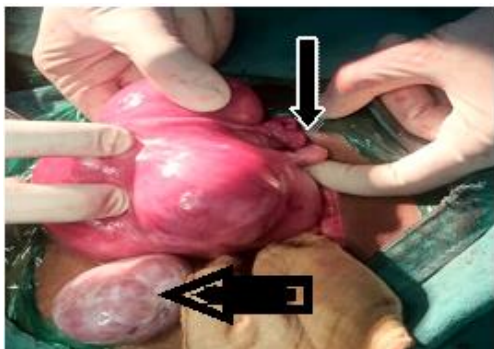


Fig. 2: Postmenopausal right ovary and enlarged Left ovary

Histopathology report: It showed secretory phase in endometrium, leiomyoma in myometrium, chronic cervicitis in cervix. Left ovary revealed corpus albicans and sheets of well differentiated fibroblast with very scanty fibrocollagenous intervening stroma suggestive of fibroma (Fig. 3)

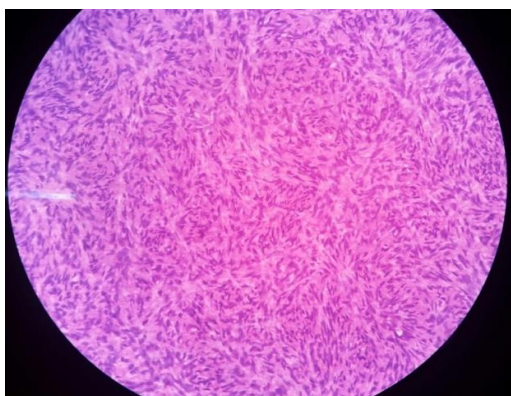

Figure 3: Histopathology of Left ovary suggestive of fibroma

Discussion

Ovarian fibroma is one of the rare solid benign tumors of the ovary. Several theories have been proposed suggesting the origin of ovarian fibroma. It probably arises from the smooth muscle cells in ovarian hilar blood vessels. Other possible origins include cells in ovarian ligament, smooth muscle cells or multipotential cells in ovarian stroma, undifferentiated germ cells, or cortical smooth muscle metaplasia. Uterine leiomyoma was suggested to be associated with ovarian leiomyoma as seen in the present case. The symptoms described in the literature are variable. They may present with abdominal pain, weight gain, vomiting or Meig's like syndrome. In Meig's syndrome, benign solid ovarian tumour is associated with ascitis and right-sided hydrothorax which resolves spontaneously after removal of the tumour. Some cases may present with hydronephrosis or acute abdominal pain mimicking appendicitis⁽⁴⁾. Presentation of ovarian fibroma as postmenopausal bleeding is very rare. In this

case, patient presented with recurrent episodes of postmenopausal bleeding which was profuse. In postmenopausal age group, endometrial thickness more than 5mm is considered abnormal. In the present case endometrium was thickened (1.8 cm) with increased echogenicity. Thickened endometrium and simple endometrial hyperplasia without atypia was evident of hyperestrogenic state.

Misfit tumors are the ovarian tumors where the tumour itself is not producing hormone, but there is stimulation of surrounding stromal cells that produce hormones. This interesting variation of non-hormone producing ovarian tumour is called as misfit tumour.

The differential diagnosis for ovarian fibroma includes thecoma, cellular fibroma and sclerosing stromal tumour. As all these tumors exhibit similar type of clinical picture, histopathological examination plays an important role in the diagnosis.

Conclusion

Every case of postmenopausal bleeding needs thorough evaluation, especially to rule out malignancies in elderly women. Ultrasonography can miss a small sized solid benign ovarian tumour in postmenopausal age group. Evidence of hyperestrogenism necessitates surgical intervention and total hysterectomy with bilateral salpingo-oophorectomy.

Conflict of Interest: None

Source of Support: Nil

References

1. Wilkinson N, Osborn S, Young RH. Sex cord stromal tumours of the ovary: A review highlighting recent advances. *Diagn Histopathol* 2008;14(8):388-400.
2. Danendran Krishnan, Komal Kumar, Anitha Ann Thomas. Unilateral ovarian fibrothecoma with menorrhagia. *Malaysian J Pathol* 2014;36(1):55-8.
3. Zahra Najmi, Abolfazl Mehdizadehkashi, Maryam Kadivar, Zeinab Tamannaie, Shahla Chaichian. Laparoscopic approach to a large ovarian fibroma: a case report. *J Reprod Infertil* 2014;15(1):57-60.
4. Sasikala R, Rupavani K, Rekha R., Erli Amel Ivan. Postmenopausal huge ovarian leiomyoma: A Rare Presentation. *Journal of Clinical and Diagnostic Research* 2014;8(11):OD03-OD04.