

Contents lists available at [ScienceDirect](http://www.sciencedirect.com)

Asian Pacific Journal of Tropical Medicine

journal homepage: www.elsevier.com/locate/apjtm

Document heading doi:

Trifocal distraction osteogenesis for reconstruction of skull defect

Ke Ke, Hai–Song Xu, Zhi–Hong Fan*

Department of Plastic Surgery, Renji Hospital, School of Medicine, Shanghai Jiaotong University, Shanghai 200127, China

ARTICLE INFO

Article history:

Received 10 March 2013

Received in revised form 15 April 2013

Accepted 15 May 2013

Available online 20 August 2013

Keywords:

Trifocal distraction osteogenesis

Skull segmental defects

Dog

ABSTRACT

Objective: To apply trifocal distraction osteogenesis in canine model of skull segmental defects and to provide reference for clinical treatment. **Methods:** Six labrador dogs were selected in this study and divided into observation group and control group randomly. Each group contained 3 dogs. Skull segmental defects models were established by surgery, and dogs in bservation group received trifocal distraction osteogenesis treatment. Bone density was observed and compared between two groups during treatment. **Results:** There were no significant difference in bone density between two groups on th 1st day ($P>0.05$). The bone density of observation group on the 30th day, and 60th day were higher than that of control group ($P<0.01$). **Conclusions:** Trifocal distraction osteogenesis has significant clinical effect, and it would be widely used in clinical treatment.

1. Introduction

Distraction osteogenesis is the technique for bone regeneration in the osteotomy gap by applying the traction device with slow stretch after the treatment of osteotomy to prolong the bone. This technology was invented by orthopedics professor Ilizarov of the former USSR. And it was originally developed for the lower extremities correction of unequal limb length, now it has been successfully used for craniofacial malformation correction.

Trifocal distraction osteogenesis usually carried out the osteotomy in the distal of medial segment and the closel of the distal fragment to form two transport distractions, and the trifocal distractor was then used for traction. The advantages are that can stimulate the body's own potential to generate new bone and repair bone defects faster. It can be operated without bone graft, thus the vessels,

nerves, muscles and soft tissue associated with the bone synchronous prolonged. That can reduce the risk of surgery and also improves the prognosis.

This experiment established a skull defect model of dog to explore the feasibility and methods of trifocal distraction osteogenesis for the reconstruction of skull defects, in order to provide a new idea for clinical treatment of skull defects in the future, especially for the treatment of pediatric skull defect.

2. Materials and methods

2.1. Experimental animals and distractor

Six labrador dog aged 6 to 7 months weighting 13–15 kg were selected and randomly divided into the experimental group and the control group, with 3 animals in each group. The distractor of this experiment was made of titanium alloy, mainly includes a guide, a drawbar, two piece of metal (a fixed block and an activity block), force rod and other parts. Two distractors were used simultaneously,

*Corresponding authors: Zhi–Hong Fan, M.D., Ph.D, Chief Physician, Professor, Doctorial Advisor, Renji Hospital, School of Medicine, Shanghai Jiaotong University, No 1630 Dongfang Road, Pudong, Shanghai 200127, China.

Tel: 020-50900000

E-mail: 1198709864@qq.com

Foundation project: This work was supported by Shanghai Municipal Science and Technology Commission, International Cooperation Projects (No. 10410702100).

pulling from opposite direction (Figure 1).




Figure 1. Titanium traction.

2.2. Anesthesia

After 12 h preoperative fasting, they underwent intravenous anesthesia by ketamine 100 mg, sodium pentobarbital 30 mg/kg intramuscularly half an hour before surgery, superaddition with additional amount equivalent to the 1/5–1/4 of the first dose during the operation, the dogs were fixed on the operating table with a simple head frame in the prone position during the surgery.

2.3. Skull defect preparation and distraction installation

Conventional skin preparation, after the sterilization and bespreading, the rectangle shaped incision was adopted to cut the skin, subcutaneous and muscle layer direct access to periosteum in one side of the calvariumuse. One side of the bone surface in the calvarium area was exposed after blunt separation of muscle from the periosteal stripping with the periosteum elevator. The skull blocks with an approximately 20 mm×20 mm size was cut off by grinding head and milling cutter, full-thickness skull defect model was prepared, and the deep surface of dural intraoperative were protected. After preparation of skull defect animal model in the control group, the sequentially suture can be performed with no significant bleeding (Figure 2a). In the experimental group, a completely bone flap with the size of 20 mm×10 mm of both ends of the skull lack of the sagittal direction was prepared. The bone flap included periosteum, internal and external cortical bone, cancellous bone, which formed the left and right bone transport distraction (Figure 2b, 2c). Two active blocks of the traction device were fixed with screws in bone transport distraction (Figure 2d), and two fixed blocks were fixed with screws in the skull outside the bone transport distraction (Figure 2e). The appropriate screw length should just penetrate the full thickness of the skull so that the underlying brain tissue wouldn't be injured. Sequentially suture was carried out after success trial traction and no obvious bleeding; the top of the reinforcing bar of the cardan

shaft in the distraction device was exposed of the skin for the application of force.




Figure 2. Skull defect preparation.

- a: The skull blocks with an approximately 20 mm×20 mm size was cut off in the parietal side of the control animals to establish full-thickness skull defect model;
- b: In the experimental group, a completely bone flap with the size of 20 mm×10 mm of both ends of the skull lack of the sagittal direction was prepared;
- c: The experimental group animals with the intermediate defect and both ends of the bone transport distraction osteotomy;
- d: The bone transport distraction were fixed by screw to two active blocks;
- e: The traction device was fixed to the skull.

2.4. Postoperative care

Semi-liquid diet or chopped green fodder was given after the animal was completely awake. Intramuscular penicillin 800 000 units from the day of surgery was given, twice a day for 5 consecutive days. The stiches were taken out 7 d after operation.

2.5. Traction of bone transport distraction

The operative day was day 0, the delayed phase was from the 1st day after the operation, and the duration was totally 5 days. Six day after operation, traction in opposite direction was carried out to the bilateral bone. The unilateral traction

rate was 1 mm/d in twice, each 0.5 mm, with 12 h–interval. Bilateral total traction rate was 2 mm/d. The traction period was 10 d. The traction period was 10 d. It was difficult for afterburn on the last day after the bone transport distraction was docking, but it still can move towards each other of about 0.2 mm–0.3 mm, which format the pressure fusion on the butt joint of the bone transport distraction. The total traction distance was 20 mm.

2.6. Index and methods for detection

Dog's health status, behavior and the changes of the local wound after operation were observed. The animals of the experimental group underwent quantitative CT scanning and three–dimensional reconstruction of skull on the first day, the 30th day and the 60th day in fixation period, to understand the healing situation of the bone fragments of the bone transport distraction and the bone traction area, to analyze and calculate the bone mineral density value (mg/mc^3) of the new bone formation at the edge of the skull defect. Animals were sacrificed on the 60th day of the fixed period, the tissue specimens of bone transport distraction, new bone of the traction area and the surrounding bone were obtained. The animals of the control group were sacrificed at the same period, the tissue specimens of the regenerating tissue of the bone defect area and the surrounding bone were obtained. Specimens were fixed in 4% volume fraction neutral formalin, underwent EDTA decalcified, then were dehydrated and embedded in paraffin. Five– μm sections were prepared for HE staining, and were observed under light microscope.

2.7. Statistical analysis

All data were analyzed by SPSS16.0 statistics software, and the expressed as mean \pm SD values. Comparison analysis was performed between the experimental group and the control group, $P < 0.05$ was regarded as statistical significance.

3. Results

3.1. General observation

All animals were survived, without neurological damage symptoms, behavioral changes, infection or dehiscid in local wound. The distraction was stable in traction phase without any loose. There were a small amount of irregular thin new bone formed along the edge of the bone defect area of the animals in the control group, most area of the central defect part were covered by the fibrous connective tissue

(Figure 3a). The animal skull specimens of the experimental group showed that the defect area has been repaired by fragments of bone transport distraction, no bone fragments absorption. The traction area was filled and restored with new bone tissue, without obvious connection gap with the surrounding bone tissue. The inner face of the distraction osteogenesis zone was closely attached by dural tissues. The dura was complete, without abnormal brain tissue change in the distraction area(Figure 3b, 3c, 3d).

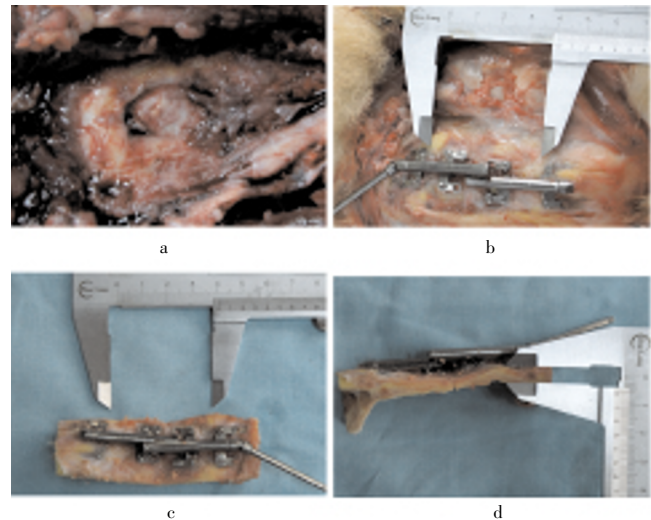


Figure 3. General observation.

- a: There were a small amount of irregular thin new bone formed along the edge of the bone defect area of the animals in the control group, most areas of the central defect part were covered by the fibrous connective tissue;
- b: The animal skull specimens of the experimental group showed that the defect area has been repaired by fragments of bone transport distraction, no bone fragments absorption. The traction area was filled and restored with new bone tissue, no obvious connection gap with the surrounding bone tissue;
- c: Front view of the specimen;
- d: lateral view of the specimen lateral view.

3.2. CT scanning and three–dimensional reconstruction of the skull

On the 60th day of the fixed period, animals of the control group only showed a very thin layer of annular new bone at the edge of the bone defect area, which was unrepaired (Figure 4a, 4b). On the 60th day of the fixed period, animals in the experimental group showed the full–thickness skull defects were completely repaired and smooth, without significant bone junction gap (Figure 4c, 4d). There was no significant difference of the bone mineral density (BMD) between the experimental group and the control group (66.5 ± 9.3 vs. 65.7 ± 8.6) ($t=0.465$, $P > 0.05$) on the 1st day; While on the 30th day and the 60th day of the fixed period, the BMD of the experimental group was significantly higher than the

control group (359.6 ± 42.8 vs. 169.6 ± 23.8 on the 30th day, 675.9 ± 49.6 vs. 416.7 ± 44.3 on the 60th day) ($t=4.038, 5.967$, respectively, both $P < 0.01$).

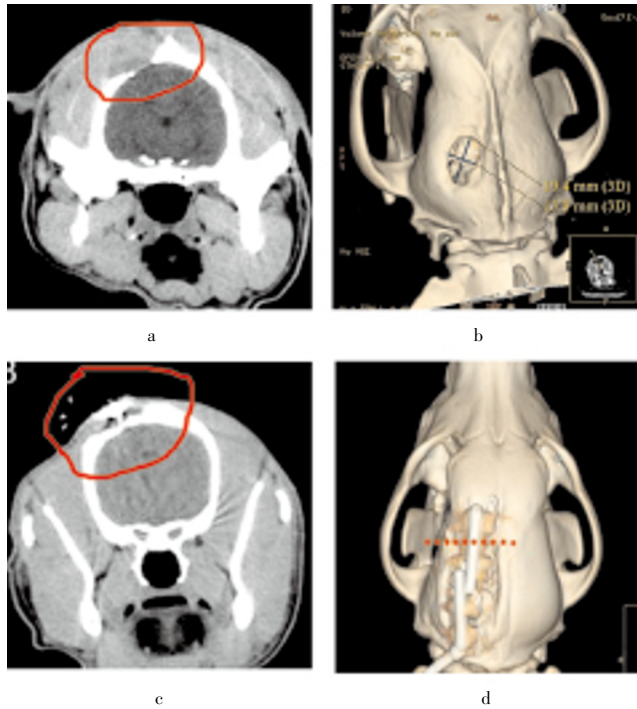


Figure 4. CT scanning.

- a: CT scan image of the animals in control group;
 b: CT reconstruction image of the animals in control group;
 c: CT scan image of animals in the experimental group;
 d: CT reconstruction image of animals in the experimental group.

3.3. Histological observation

Tissue samples of the bone defect area of the animals in the control group showed that they were composed by connective tissue with arrangement disorder (Figure 5a). Samples of the distraction osteogenesis zone of the animals in the experimental group showed significantly more active new bone and more mature bone structure (Figure 5b).

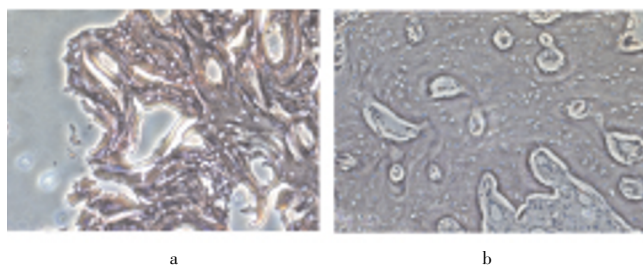


Figure 5. Histological observation.

- a: HE ($\times 40$) of the animals in the control group showed connective tissue with arrangement disorder;
 b: HE ($\times 40$) of the animals in the experimental group showed significantly more active new bone and more mature bone structure.

4. Discussion

Skull defect is a common clinical problem in neurosurgery and craniofacial surgery, which is still a huge challenge for the craniofacial surgeon in pediatric craniofacial surgery. Because there are unfavorable factors such as limited donor site, wound air dressing and infection, so the clinical requirement makes people want to find new methods which are more effective and safe to repair skull defects. Distraction osteogenesis is a technique with the application of specific mechanism which gradual pulling away from breaking the bone segment^[1], and produce a continued and slowly force–tension between the bone segments, thus can stimulate generation of a large number of callus, so as to promote new bone formation and fracture healing^[2]. This technology was firstly introduced and used for the treatment of limb fractures by Italian scholars Codivilla^[3]. After World War II, on the basis of animal experiments and clinical applications, Ilizarov^[4–6] summarized the basic and application principles of distraction osteogenesis, this technology has been developing rapidly in orthopedic surgery. This technology has been widely used in oral craniofacial surgery, especially in dysostosis of the midface and defect deformity research of maxillary and mandibular. It has been carried out very often, and has achieved satisfactory results. Distraction osteogenesis for skull defects are in the animal experimental stage^[7,8]. A number of studies have shown distraction osteogenesis by distraction of ortho full–thickness skull flap and regeneration of the tissue to repair the defect, thus avoid lots of disadvantages for the old repair method which including trauma in the donor site, bone graft absorption, infection, soft tissue atrophy and complication. It is more effective and shortcut with high quality osteogenesis, the effect is significantly better than the traditional method which simply fills with restorative materials^[9]. But it has unfavorable factors such infection and the relatively long time of distraction period and fixation period, its clinical application is still has relative limitations. In this study, we established dog skull defect model, and successfully verified the feasibility of distraction osteogenesis for the repairment of skull defects. Meanwhile, in order to shortening the traction period, we tried trifocal distraction osteogenesis.

Trifocal distraction osteogenesis is usually treated by osteotomy in the distal of medial segment and the closel of the distal fragment to form two bone with appropriate size as transport distraction. Then the trifocal traction is installed, the two transport distraction are relatively pulled until they bondwith each other. Tension bone regeneration zone is formed between the two bone transport distraction and two bone ends during the pulling process, and a pressure

binding zone was formed between 2 transport distraction. Trifocal distraction osteogenesis use two bone transport distraction, the new bone formation is 1 time faster than traditional monofocal and bifocal distraction osteogenesis, which can repair the defect faster. Compared with the conventional bifocal distraction, the traction period in our experiments decrease a half, there are no systemic symptoms and local infection of the experimental animals in traction process.

The trifocal distraction we used in this experiment are built-in type, only the top of the reinforcing bar was exposed of the scalp so as to operate more easily, and effectively reduce the chances of infection and scar formation. When the fixed period ended, the traction device was taken by the operation and the wound was completely closed. For children in the growth and development stages, this method can avoid many problems of the traditional filled with titanium mesh repair method. These problems may include separation of the titanium plate and titanium nail, intracranial displacement of the small titanium plate and the limitations for the bone growth. This method provides new ideas for future clinical treatment of skull defects of children.

Appropriate traction rate and frequency is a key to success distraction osteogenesis. Too small traction rate (less than 0.5 mm/d) can't stimulate new bone formation, too large traction rate (greater than 1.5 mm/d) may lead to the formation of fibrous tissue but no new bone, and even cause nonunion^[10–13]. Most scholars believe that the appropriate rate of craniofacial bone traction is 1.0 mm/d in twice. In this study, the traction rate was 1 mm/d (unilateral) in twice, 12 h apart, and with satisfactory distraction osteogenesis results. Whether the faster traction rate or a combination of growth factor can still have the satisfied osteogenic effect will be further researched in our follow-up experiments.

In this experiment, the Labrador retriever was used as the research object to establish full-thickness skull defect model. Because the structure of its skull is closer to human, and it also have good tolerance to surgery and relatively mild temperament, and the traction of bone transport can be implemented by two or three people.

Conflict of interest statement

We declare that we have no conflict of interest.

References

- [1] Zhou N, Mai HM, Liang FX. The observation of histological change in mandibular distraction osteogenesis and acute lengthening. *J Oral Sci Res* 2004; **20**(2): 116–118.
- [2] Yu HB, Shen GF. Review of the application of platelet-rich plasma in distraction osteogenesis. *J Oral Maxillofacial Surg* 2008; **18**(1): 61–64.
- [3] Codivilla A. On the means of lengthening, in the lower limbs the muscles and tissues, which are shortened through deformith. *Am J Orthop Surg* 1905; **2**: 235.
- [4] Ilizarov GA. The tension–stress effect on the genesis and growth of tissue: part 1. The influence of stability of fixation and soft tissue preservation. *Clin Orthop* 1989; **238**: 249–281.
- [5] Ilizarov GA. The tension–stress effect on the genesis and growth of tissue: part 2. The influence of the rate and frequency of distraction. *Clin Orthop* 1989; **239**: 263–285.
- [6] Ilizarov GA. Clinical application of the tension–stress effects for limb lengthening. *Clin Orthop* 1990; **250**: 8–26.
- [7] Kramer FJ, Mueller M, Rahmstorf M, Swennen GR, Dempf R, Schierle H. Ortho–and heterotopic bone grafts in bifocal transport osteogenesis for craniofacial reconstruction—an experimental study in sheep. *Int J Oral Maxillofac Surg* 2004; **33**(6): 575–583.
- [8] Kramer FJ, Sinikovic B, Mueller M, Rahmstorf M, Schierle H. Experimental application of a biomaterial in bifocal transport osteogenesis for craniofacial reconstruction. *J Craniomaxillofac Surg* 2008; **36**(4): 218–226.
- [9] Song XC, Zhou N. Current status of transport distraction osteogenesis for the reconstruction of craniomaxillofacial skeletal defects. *Intl J Stomatol* 2011; **38**(1): 102–105.
- [10] Cho BC, Hwang SK, Uhm KI. Distraction osteogenesis of the cranial vault for the treatment of craniofacial synostosis. *J Craniofac Surg* 2004; **15**: 135–144.
- [11] Cheung LK, Zhang Q, Zhang ZG, Rahmstorf M, Schierle H. Reconstruction of maxillectomy defect by transport distraction osteogenesis. *Int J Oral Maxillofac Surg* 2003; **32**: 515–522.
- [12] Bouletreau PJ, Warren SM, Paccione MF, Spector JA, McCarthy JG, Longaker MT. Transport distraction osteogenesis: a new method to heal adult calvarial defects. *Plast Reconstr Surg* 2002; **109**: 1074–1084.
- [13] Farhadieh RD, Gianoutsos MP, Dickinson R, Walsh WR. Effect of distraction rate on biomechanical, mineralization, and histologic properties of an ovine mandible model. *Plast Reconstr Surg* 2000; **105**: 889–895.