

Contents lists available at [ScienceDirect](#)

Asian Pacific Journal of Tropical Medicine

journal homepage: www.elsevier.com/locate/apjtm

Document heading doi:

Femoral compressive neuropathy from iliopsoas haematoma complicating dengue hemorrhagic fever

Sneha Ganu*, Yesha Mehta

Department of Physiotherapy, MGM Hospital & College of Physiotherapy, Navi Mumbai, India

ARTICLE INFO

Article history:

Received 10 October 2012

Received in revised form 15 November 2012

Accepted February 2013

Available online 20 April 2013

Keywords:

Dengue

Dengue hemorrhagic fever

Femoral neuropathy

Iliopsoas hematoma

ABSTRACT

Dengue fever is a debilitating mosquito-borne disease caused by dengue virus. We reported a case of femoral compression neuropathy due to iliopsoas hematoma complicating dengue hemorrhagic fever. Iliopsoas muscle hematoma can cause femoral neuropathy with resultant pain and paralysis. Such manifestations are not well documented in the literature. The pathogenesis of hematoma and compressive neuropathy with its appropriate management is discussed.

1. Introduction

Dengue fever is a debilitating mosquito-borne disease caused by dengue virus. Epidemic dengue fever (DF) and dengue hemorrhagic fever (DHF) have emerged as a global public health problem in recent decades. Over 40% of the world's population is now at risk from dengue according to World Health Organization (WHO). WHO currently estimates there may be 50–100 million dengue infections worldwide every year. Because of its serious emerging health threats, it has aroused considerable medical and public health concerns. We report a case of femoral compression neuropathy due to iliopsoas hematoma complicating DHF. Such manifestations are not well documented in the literature. However, it is important to be aware of such complications of the disease, because meticulous monitoring and appropriate treatment at the correct time can reduce patient morbidity.

2. Case report

A 55 year-old, healthy, active male presented with pain and swelling in the left groin with limitation of movement at left hip joint since two weeks following dengue fever. The pain was experienced in the left anterior groin region

which subsequently subsided to be replaced by progressive numbness & weakness in the femoral nerve distribution. The patient was admitted for a period of 10 days for dengue fever with thrombocytopenia (Hb: 10 g/dL, WBC: 7×10^4 /mL, platelets: $3400/\text{cm}^3$). Examination revealed spontaneous flexion of the right hip, with tenderness elicited by stretching of the psoas muscle by extension of the hip–psoas sign. The neurological examination revealed slight weakness of hip flexors (grade 4/5 on MRC), with flicker of contraction in quadriceps (grade 1/5). There was profoundly decreased sensation in the femoral & lateral femoral cutaneous nerve distribution. USG abdomen revealed expanded psoas muscle with hypoechoic fluid collection. MRI of lumbosacral spine with screening of pelvis with both hips revealed moderate sized (73 mm × 64 mm in maximum transverse dimensions) hyperintense lesion in the left iliacus muscle in the left iliac fossa extending up to iliopsoas insertion in the lesser trochanter. No obvious altered signal was seen in the underlying bone. NCV revealed severe degeneration of left femoral & lateral cutaneous nerve of thigh. Surface EMG indicated denervation of quadriceps femoris. Exploration of left iliac region with extraction of hematoma was done. Physiotherapy was started in the form of muscle retraining which included electrical muscle stimulation to the quadriceps, quadriceps setting and strengthening exercises. Patient demonstrated recovery of his femoral nerve function, with an improvement of the quadriceps strength to Grade 4/5 and full functional recovery at 6–months follow-up.

*Corresponding author: Sneha Ganu, MGM College of Physiotherapy, Sector 18, NH4 Highway, Kamothe, Navi Mumbai–410209, India.

Tel: 9820790250/ 9967342628

E-mail: ganusneha@gmail.com; pandya.yesha@gmail.com

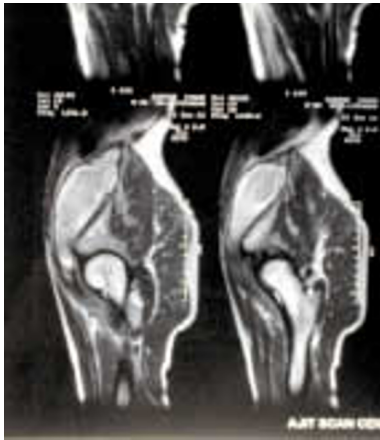

Figure 1. MRI of Hip Joint showing presence of haematoma in the left iliac fossa extending up to iliopsoas insertion in the lesser trochanter.

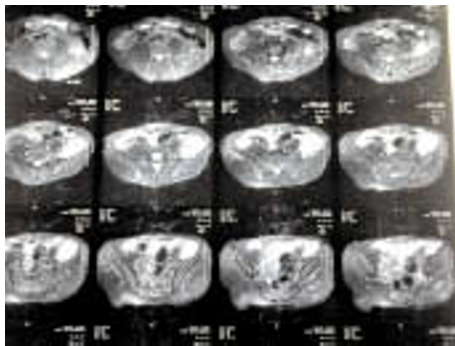


Figure 2. MRI of lumbosacral spine with screening of pelvis with both hips showing moderate sized hyperintense lesion in the left iliac muscle.

4. Discussion

The clinical manifestations of dengue infection range from asymptomatic infection to undifferentiated fever, DF and DHF. During recovery some patients develop hemorrhagic manifestation that may be mild petechial hemorrhage, bleeding at the nose, gastrointestinal tract or gums which may be severe. In our case the site of bleeding was the iliopsoas muscle which is very unusual. In our knowledge, there is only one case reported of iliopsoas haematoma complicating DHF^[1]. The pathogenesis of bleeding is poorly understood but it is suggested that the enhanced immune response of the host to a secondary dengue virus infection causing vasculopathy, thrombopathy and disseminated intravascular coagulation. Vasculopathy include endothelial dysfunction and increased vascular permeability. Thrombopathy consists of thrombocytopenia and platelet dysfunction^[2,3].

With hemorrhage within the iliacus muscle or subfascial region, the patient initially develops a severe pain in the groin and inguinal region with associated tender globular swelling in the iliac fossa. Hematoma might extend into the psoas fascia inferiorly and cause additional fusiform swelling of the psoas compartment, with a palpable groove between these two muscles. The swelling can also extend into the groin as in the present case. The MRI revealed moderate sized hyperintense lesion in the left iliac muscle in the left iliac fossa extending up to iliopsoas insertion in the lesser trochanter. Our patient complained of progressive numbness & weakness in the femoral nerve distribution. Electrodiagnostic investigation with electromyography and

nerve conduction studies confirmed the femoral compression neuropathy and excluded other neural involvement. Femoral compression neuropathy is a well-recognized entity associated with hemophilia^[4], anticoagulation therapy^[5], cardiac catheterization^[6] and major abdomino-pelvic operations^[7] or traumatic but not known with DHF. Anatomic studies have revealed that the fascia overlying the iliacus muscle and the femoral nerve is strong and not easily stretched in the presence of underlying hematoma for matation^[8]. As a result, femoral nerve compression occurs along the iliopsoas gutter, where it is also at the most risk for ischemia due to the poor vascular supply to this region of the nerve. In addition, the hematoma may track down the iliacus muscle into the femoral canal and compress the femoral nerve against the rigid inguinal ligament, resulting in further ischemia and resultant neuropathy. Goodfellow *et al* demonstrated that a hematoma that is responsible for femoral nerve palsy is necessarily situated in the iliacus muscle and not in the psoas muscle^[4]. High pressure in the iliacus muscle or fascial sheath produces and compresses the femoral nerve against the psoas muscle tendon and induces an ischemic femoral neuropathy. Treatment of femoral neuropathy with iliopsoas hematoma is controversial. An iliacus muscle hematoma never drains spontaneously. It induces chronic compression on the femoral nerve. Thus surgical intervention in the form of evacuation becomes mandatory for the nerve recovery. Less invasive percutaneous drainage of the iliopsoas hematoma can effectively provide decompression of the femoral nerve and allow functional recovery. As the patient presented two weeks after the onset of symptoms, the organized hematoma made percutaneous aspiration impossible, thus open surgical evacuation was performed. The postoperative course was uneventful and the patient demonstrated recovery of femoral nerve functions, with an improvement of the quadriceps strength to grade 4/5 at the 6-months follow-up.

Intramuscular hematoma should be considered as a complication of DHF. Although there is no clear consensus for the treatment of femoral neuropathy associated with iliopsoas muscle hematoma, the development of associated femoral neuropathy mandates early surgical evacuation for good recovery.

Conflict of interest statement

We declare that we have no conflict of interest.

References

- [1] Ameer AM, Arachchi WK, Jayasingha PA. Psoas haematoma complicating dengue haemorrhagic fever: a case report. *Galle Med J* 2009; **14**(1): 83–84.
- [2] Mathew A, Rothman AL. Understanding the contribution of cellular immunity to dengue disease pathogenesis. *Immunol Rev* 2008; **225**: 300–313.
- [3] Suwanbamrung C. Children's basic knowledge and activities for dengue problem solution: an islamic religious school, Southern Thailand. *Asian Pac J Trop Dis* 2012; **2**(6): 456–464.
- [4] Goodfellow J. Iliacus haematoma—a common complication of haemophilia. *J Bone Joint Surg Br* 1967; **49**: 748–756.
- [5] Kong WK, Cho KT. Femoral neuropathy due to iliacus muscle haematoma in a patient on warfarin therapy. *J Korean Neurosurgery Soc* 2012; **51**(1): 51–53.
- [6] Kent KC, Moscucci M. Neuropathy after cardiac catheterization: incidence, clinical patterns, and long-term outcome. *J Vasc Surg*. 1994; **19**: 1008–1013.
- [7] Keuo LJ, Penn IW. Femoral neuropathy after pelvic surgery. *J Chi Med Assoc* 2004; **67**: 644–646.
- [8] Parmer SS, Carpenter JP, Fairman RM, Velazquez OC, Mitchell ME. Femoral neuropathy following retroperitoneal hemorrhage: case series and review of the literature. *Ann Vasc Surg* 2006; **20**: 536–540.