



Contents lists available at [ScienceDirect](http://www.sciencedirect.com)

Asian Pacific Journal of Tropical Medicine

journal homepage: www.elsevier.com/locate/apjtm



Document heading doi:

Multiple splenic infarcts in acute *Plasmodium vivax* malaria: A rare case report

Hari Krishan Aggarwal¹, Deepak Jain^{1*}, Vipin Kaverappa¹, Promil Jain², Ashwani Kumar¹, Sachin Yadav¹

¹Department of Medicine, Pt. B.D. Sharma University of Health Sciences, Rohtak–124001, Haryana, India

²Department of Pathology, Pt. B.D. Sharma University of Health Sciences, Rohtak–124001, Haryana, India

ARTICLE INFO

Article history:

Received 10 October 2012

Received in revised form 15 November 2012

Accepted 15 December 2012

Available online 20 April 2013

Keywords:

Malaria

Splenic infarcts

Plasmodium vivax

ABSTRACT

In tropical countries like India, malaria has been one of the most common parasitic illnesses leading to frequent hospitalization and causing major economic burden among the masses. Although *Plasmodium vivax* infection is considered to be benign, in contrast to *Plasmodium falciparum* infection which is notorious for its severe splenic complications can occur frequently. Splenomegaly tends not to receive special attention, as it is not usually accompanied by any symptoms and can be gradually resolved via standard antimalarial therapy. Splenic infarction, although rarely attributable to malaria in an endemic region with high parasitemia, can be a rare presentation of this disease entity.

1. Introduction

Malaria, a disease of antiquity, has proved to be a formidable deterrent to the cultural and socioeconomic progress of man in the tropical, sub-tropical and monsoon prone zones of the world. History is replete with instances of devastation caused by this disease. Hence, clinicians should be aware of the clinical presentations and its common and rarer complications. The spectrum of structural changes of the spleen during malaria infection vary from asymptomatic enlargement to severe complications, such as splenic infarct, rupture, hemoperitoneum, ectopic spleen, hypersplenism, torsion, and cyst or abscess formation^[1]. These may lead to serious conditions which can be life-threatening. Here, we report the case of a young female presenting with splenic infarction in acute malaria.

2. Case report

A 16 year old female student presented to medicine outpatient department with history of intermittent high grade fever for 10 d. Each paroxysm was associated with rigor and chills and was relieved with profuse sweating. She also complained of dull aching pain in left upper quadrant of abdomen for 5 d which was non-radiating accompanied by nausea and decreased appetite. She denied history of cough, burning micturition and diarrhoea. The patient had no remarkable family history.

On examination, she was hemodynamically stable (Pulse was 104 beats/min regular good volume, and blood pressure was 124/82 mm Hg (1 mm Hg=0.133 kPa). Pallor was present but there was no evidence of icterus, clubbing, lymphadenopathy, or pedal edema. Abdomen examination revealed a tender palpable spleen, 4 cm below left costal margin, with smooth surface and firm in consistency, with no splenic rub. Liver was palpable 3 cm below right costal margin with smooth surface and well defined margins. There was no evidence of ascites and bowel sounds were

*Corresponding author: Dr. Deepak Jain, Department of Medicine, Pt. B.D. Sharma University of Health Sciences, Rohtak–124001, Haryana, India.

Tel: +91-9416147887

E-mail: jaindeepakdr@gmail.com

normal. Examination of cardiovascular system, central nervous system and respiratory system were unremarkable.

On investigation, her haemoglobin level was 7.1 gm/dL with a total leucocyte count of 1.15×10^{10} (82% polymorphs, 15% lymphocytes, 3% monocyte and 1% eosinophils). Platelet count was normal. Card test for malaria antigen was positive for *Plasmodium vivax* (*P. vivax*). Peripheral blood showed trophozoites of *P. vivax* and there were no sickle cells. Card test and peripheral blood examination were negative for *Plasmodium falciparum* (*P. falciparum*). Kidney function tests, lipid profile and liver function tests were well within normal limits. Erythrocyte sedimentation rate was 40 mm and Widal test was negative. Blood culture was sterile on two separate occasions. Urine examination and stool examination were essentially normal with no leucocyte or pus cells. Tests for underlying coagulation disorders like protein C and protein S deficiency, Leiden mutation, and antithrombin III deficiency were negative. Antiphospholipid antibody levels, serum homocystiene levels and haemoglobin electrophoresis were normal.

Ultrasonographic evaluation of the abdomen revealed multiple wedge-shaped hypo-echoic areas in the spleen, suggestive of infarction. Liver was enlarged and measured 17 cm with normal echotexture. Gall bladder, pancreas and bilateral kidneys were normal and there was no evidence of free fluid. Contrast enhanced computed tomography of abdomen was planned which revealed multiple wedge-shaped hypodense non-enhancing lesions consistent with splenic infarction (Figure 1). Chest X ray revealed no abnormality. Electrocardiogram showed sinus tachycardia and echocardiography was normal.

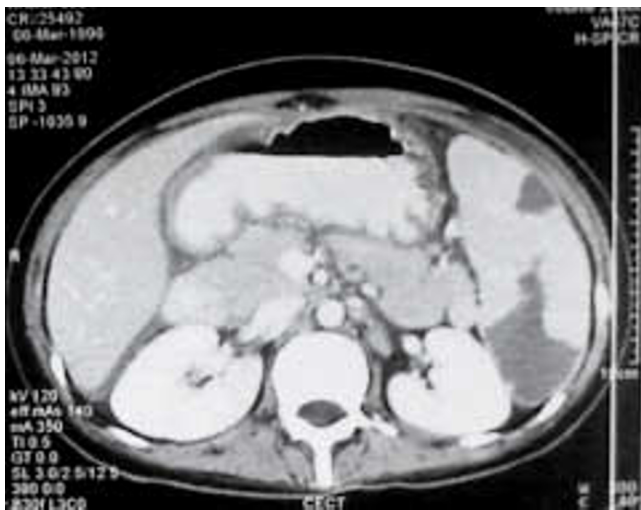


Figure 1. CT image showing wedge-shaped splenic infarct.

The patient was treated with antimalarial (artesunate), hydrated adequately with intravenous fluids along with routine supportive therapy. Analgesics were administered for next 10 d with steadily decreasing dose to relieve

her abdominal pain. A total of 400 mL blood was also transfused. She remained afebrile and recovered completely. She was discharged under stable condition and is on regular follow up.

3. Discussion

Malaria has been amongst the most common parasitic infection in India. The causative microorganism belongs to the Plasmodium family. The four common species that are encountered are *P. falciparum*, *P. vivax*, *Plasmodium malariae* and *Plasmodium ovale*. In India, approximately 55% of the cases are caused by *P. vivax*. In 40%–42% of the cases, the culprit is *P. falciparum*, which is notorious for giving rise to complications such as cerebral malaria, acute renal failure, liver damage, and hemodynamic collapse[2]. Infections by malaria parasites induce a dramatic, albeit variable splenic response mostly characterized by moderate to massive splenomegaly. In fact, spleen size has been used as a tool to determine the intensity of malaria transmission in endemic regions[3]. *P. vivax*, although considered to be benign, can manifest with splenic complications, but splenic infarcts are rare[4,5].

Spleen is the second most common organ, next to kidney in which embolism and infarction occur. Embolism and infarction occur as a result of arterial or venous compromise and infective endocarditis is the commonest cause. Multifactorial factors involved in the aetiology includes myelofibrosis, haematological malignancy, thromboembolic disease due to atrial fibrillation, rheumatologic disorders, adult respiratory distress syndrome, rupture of splenic artery aneurysm, septic emboli in infective endocarditis, sickle cell disease and Wegener granulomatosis[6]. Embolism and infarction also occur as a rare presentation of malaria[7].

Although splenomegaly is frequently observed in malaria cases, it tends not to receive special attention, as it is not usually accompanied by any symptoms and can be gradually resolved via standard antimalarial therapy. Pathology of the malarial spleen reveals a variety of characteristic features, including thrombi in the arterioles, veins, and sinusoids, which are frequently associated with haemorrhage, necrosis, and infarction. Cases of splenic infarction attendant to malaria have been reported principally in cases of falciparum malaria, in which high levels of parasitemia and microvascular sequestration of parasitized red blood cells can constitute predisposing factors. Although these predisposing factors are absent in cases of vivax malaria, the pathology of spleen observed in vivax malaria patients indicates that splenic infarction occurs frequently in such cases probably secondary to ischemia induced by

hyperplasia of reticuloendothelial system^[8–10]. Thus, the possibility remains high that clinically overt splenic infarction may occur in cases of vivax malaria.

Spleen is supplied by splenic artery and short gastric artery. Within spleen, arterial supply is segmental and occlusion of secondary branches results in a wedge-shaped infarct. The wedge-shaped infarct has its apex towards the hilum and its base beneath the capsule. It is either segmental or global. The clinical presentation of infarction varies considerably. One third cases are asymptomatic, discovered incidentally on radiological or post-mortem studies, or haemorrhagic shock as a result of splenic rupture. The most common symptom is left upper quadrant abdominal pain along with nausea, vomiting pleuritic chest pain and left shoulder pain. Septic thromboemboli may result in splenic abscesses, which present with sepsis and left upper abdominal pain. Laboratory tests are not diagnostic for splenic infarction except mild leucocytosis, thrombocytosis and anaemia^[11].

The radiographic characteristics of splenic infarction with either ultrasonography or computed tomography are well defined, though computed tomography has emerged as the preferred imaging modality for making the diagnosis^[12]. Magnetic resonance imaging, preferably performed with intravenous gadolinium contrast, is another useful modality that clearly identifies infarcted splenic parenchyma. The prognosis is usually favourable when the infarcts are small.

The treatment of splenic infarct does not involve active intervention but meticulous observation to look for its complication and supportive treatment. Because of the (albeit small) risk of fatal, overwhelming post-splenectomy sepsis, splenic preservation is preferable whenever possible. The mainstay of medical therapy of splenic infarct is analgesia with either narcotics or non-steroidal anti-inflammatory agents, and prevention of secondary infection. Complications include splenic abscess, haemorrhage, sub-phrenic abscess, pancreatic fistula, and gastric fistula. Splenic abscess results from septic emboli or super-infection of a prior infarct^[13]. The above complications warrant surgical intervention. Some authors advocate splenectomy in all cases of splenic infarct and abscess, questioning the utility of preserving the residual, partially functioning spleen. This may be accomplished using traditional open techniques or with laparoscopic techniques.

Splenic infarct is a known but a rare complication of acute malaria. Although splenic infarct is associated with *P. falciparum*, to the best of our knowledge, only three documented cases of splenic infarction associated with *P. vivax* malaria have been reported. Hence, in the malaria

endemic areas like India, it should be considered in the differential diagnosis of the patients presenting with upper abdominal pain and fever.

Conflict of interest statement

We declare that we have no conflict of interest.

References

- [1] Contini S, Lewis HR. Splenic abscess as malarial complication. *Emerg Infect Dis* 2006; **12**(3): 529–530.
- [2] Dash AP, Valecha N, Anvikar AR, Kumar A. Malaria in India: Challenges and opportunities. *J Biosci* 2008; **33**(4): 583–592.
- [3] Neva FA, Sheagren JN, Shulman NR, Canfield CJ. Malaria: Host-defense mechanisms and complications. *Ann Intern Med* 1970; **73**(2): 295–306.
- [4] Ozsoy MF, Oncul O, Pekkaflali Z, Pahsa A, Yenen OS. Splenic complications in malaria: report of two cases from Turkey. *J Med Microbiol* 2004; **53**(Pt12): 1255–1258.
- [5] Reza YM, Taghi RM. Prevalence of malaria infection in Sarbaz, Sistan and Bluchistan province. *Asian Pac J Trop Biomed* 2011; **1**(6): 491–492.
- [6] Agarwal VK, Agarwal S, Pathak T. Splenic infarct in falciparum malaria. *Indian Pediatr* 1997; **34**(11): 1050–1051.
- [7] Hovette P, Lecoules S, Boete F, Imbert P, Touze JE, Laroche R. Splenic infarction during *P. falciparum* and *P. vivax* malaria. *Presse Med* 1994; **23**(26): 1226.
- [8] Bonnard P, Guiard-Schmid JB, Develoux M, Rozenbaum W, Pialoux G. Splenic infarction during acute malaria. *Trans R Soc Trop Med Hyg* 2005; **99**(1): 82–86.
- [9] Osonuga OA, Osonuga A, Osonuga AA, Osonuga IO. Resolution pattern of jaundice among children presenting with severe malaria in rural South-West Nigeria. *Asian Pac J Trop Biomed* 2012; **2**(7): 551–553.
- [10] Jombo GTA, Araoye MA, Damen JG. Malaria self medications and choices of drugs for its treatment among residents of a malaria endemic community in West Africa. *Asian Pac J Trop Dis* 2011; **1**(1): 10–16.
- [11] Hershey FB, Lubitz JM. Spontaneous rupture of the malarial spleen. *Ann Surg* 1948; **127**(1): 40–57.
- [12] Goerg C, Schwerk WB. Splenic infarction: Sonographic patterns, diagnosis, follow-up and complications. *Radiology* 1990; **174**(3 Pt 1): 803–807.
- [13] Gupta S, Kakar A. Splenic infarct of unusual aetiology. *J IACM* 2004; **5**(4): 310–314.