



Contents lists available at ScienceDirect

Asian Pacific Journal of Tropical Medicine

journal homepage: www.elsevier.com/locate/apjtm



Document heading doi:

Nephroprotective activity of *Solanum xanthocarpum* fruit extract against gentamicin–induced nephrotoxicity and renal dysfunction in experimental rodents

Talib Hussain^{1,2}, Ramesh K Gupta¹, K Sweety¹, Bavani Eswaran¹, M Vijayakumar¹, Chandana Venkateswara Rao^{1*}

¹Pharmacognosy and Ethnopharmacology Division, National Botanical Research Institute, Lucknow, Uttar Pradesh, 226001, India

²Department of Pharmacology and Toxicology, Faculty of Pharmacy, Integral University, Lucknow, Uttar Pradesh, 226001, India

ARTICLE INFO

Article history:

Received 10 March 2012

Received in revised form 15 May 2012

Accepted 15 July 2012

Available online 20 September 2012

Keywords:

Solanum xanthocarpum

Gentamicin

Antioxidants

Nephrotoxicity

Renal dysfunction

ABSTRACT

Objective: To evaluate nephroprotective potential of *Solanum xanthocarpum* (*S. xanthocarpum*) fruit extract (SXE) against gentamicin (GM) induced nephrotoxicity and renal dysfunction. **Methods:** Twenty-four Wistar rats were divided into four groups ($n=6$). Control rats that received normal saline (*i.p.*) and 0.5% carboxymethyl cellulose (*p.o.*) per day for 8 d. Nephrotoxicity was induced in rats by intraperitoneal administration of GM (100 mg/kg/d for 8 d) and were treated with SXE (200 and 400 mg/kg/d (*p.o.*) for 8 d). Plasma and urine urea and creatinine, kidney weight, urine output, blood urea nitrogen, renal enzymatic and non-enzymatic antioxidants and lipid peroxidation was evaluated along with histopathological investigation in various experimental groups of rats. **Results:** It was observed that the GM treatment induced significant elevation ($P<0.001$) in plasma and urine urea, creatinine, kidney weight, blood urea nitrogen, renal lipid peroxidation along with significant decrement ($P<0.001$) in urine output, renal enzymatic and non-enzymatic antioxidants. SXE 200 and 400 mg/kg treatment to GM treated rats recorded significant decrement (up to $P<0.001$) in plasma and urine urea and creatinine, renal lipid peroxidation along with significant increment (up to $P<0.001$) in renal enzymatic and non-enzymatic antioxidants. Histological observations of kidney tissues too correlated with the biochemical observations. **Conclusions:** These findings powerfully support that *S. xanthocarpum* fruit extract acts in the kidney as a potent scavenger of free radicals to prevent the toxic effects of GM both in the biochemical and histopathological parameters and thus validates its ethnomedicinal use.

1. Introduction

A number of environmental contaminants, chemicals and drugs including antibiotics dramatically alter the structure and function of various tissues and produce multiple adverse effects in the liver, kidney, heart and intestine[1]. Aminoglycoside antibiotics are frequently used

in the treatment of severe infections of the abdomen and urinary tract[2]. Gentamicin (GM) is still considered to be an important aminoglycoside antibiotic against life threatening bacterial infections. However, nephrotoxicity and ototoxicity remain major problems for its effective long term clinical use[3]. GM is known to cause a number of morphologic, metabolic and functional alterations in the kidney and the specificity of GM nephrotoxicity is apparently related to its accumulation in the renal proximal convoluted tubules leading to tubular necrosis[4].

Solanum xanthocarpum (*S. xanthocarpum*) Schrad. & Wendl. (family: Solanaceae) commonly known as Yellow Berried Nightshade (syn: Kantakari), is a prickly diffuse bright green perennial herb, woody at the base, 2–3 m

*Corresponding author: Chandana V. Rao, Pharmacognosy and Ethnopharmacology Division, National Botanical Research Institute (CSIR), Rana Pratap Marg, Lucknow, India.

Tel: +91 522 2297976

Fax: +91 522 2205836

E-mail: mdth_ah@yahoo.com

height found throughout India, mostly in dry places as a weed on road sides and waste lands. The fruits are of 1.3 cm diameter berry, yellow or white with green veins, surrounded by enlarged calyx[5]. The fruits are known for several traditional medicine uses like anthelmintic, antipyretic, laxative, anti-inflammatory, urinary bladder, antiasthmatic, aphrodisiac activities and enlargement of the liver[6]. The stem, flowers and fruits are prescribed for relief in burning sensation in the feet accompanied by vesicular eruptions[7].

The fruits are reported to contain several steroidal alkaloids like solanacarpine, solanacarpidine, solancarpine, solasonine, solamargine and other constituents like caffeic acid, coumarins like aesculetin and aesculin, steroids carpesterol, diosgenin, campesterol, daucosterol and triterpenes like cycloartanol and cycloartenol were reported from the fruits[8]. The antispasmodic, cardiotoxic, hypotensive, antianaphylactic, arbuda tumour[9], Anti-urolithiatic and natriuretic activities were also reported[10]. Solasodine is present in a number of *Solanum* species (Solanaceae) such as *Solanum khasianum*, *Solanum xanthocarpum*, *Solanum nigrum*, *Solanum gracile*, *Solanum laciniatum* etc[11]. Lupeol, apigenin and solamergine exhibited Solasodine anticancer property[12], anti-nociceptive[13], antioxidant activities of the chloroform extract[14] and hypoglycaemic[15].

The flavanoids quercitrin and apigenin glycosides are the major chemical constituents which are present in the fruits of *S. xanthocarpum*[16]. To the best of our knowledge there were no any scientific reports available in support of its traditional claim of nephroprotective potential. Therefore, present study was designed to demonstrate the effect of *S. xanthocarpum* fruit extract (SXE) against gentamicin induced renal damage in experimental animals.

2. Materials and methods

2.1. Chemicals

Gentamicin (Nicholas, Mumbai, India) from the source indicated in parentheses. All the chemicals used were of analytical grade and procured from Sigma chemicals Co., USA and Qualigens fine chemicals, Mumbai, India.

2.2. Preparation of plant extract

Fresh and matured fruits were collected from campus garden of National Botanical Research Institute, Lucknow, India in November 2010. The plant material was identified and authenticated and the voucher specimen number NAB-79023 was deposited in the institutional herbarium. The freshly collected fruits (2 kg) of *S. xanthocarpum* were dried and powdered. The powdered plant material (900 g) was macerated with petroleum ether, the marc was exhaustively extracted with of 50% ethanol for three days. The extract

was separated by filtration and concentrated on rotavapour (Buchi, USA) and then dried in lyophilizer (Labconco, USA) under reduced pressure. The yield obtained was 198.40 g of solid residue (yield 22.04% w/w). The extract obtained was further subjected to pharmacological investigation.

2.3. Animals

Wistar rats weighing (150–170 g) and swiss albino mice (25–30 g) of either sex were procured from CDRI, Lucknow. They were kept in departmental animal house in well cross ventilated room at (22±1)°C with light and dark cycles of 12 h for 1 week before and during the experiments. Animals were provided with standard rodent pellet diet (Amrut, India) and the food was withdrawn 18–24 h before the experiment though water was given *ad libitum*. All studies were performed in accordance with the guide for the care and use of laboratory animals, as adopted and promulgated by the Institutional Animal Care Committee, CPCSEA, India (Reg. No. 222/2000/CPCSEA).

2.4. Acute oral toxicity studies

Acute toxicity study was performed according to OECD guidelines No. 423[17]. Swiss albino mice of either sex were divided into six groups with six animals each. SXE was administered orally as a single dose to mice at different dose levels of 250, 500, 1 000, 1 500 and 2 000 mg/kg b.w. Animals were observed periodically for the symptoms of toxicity and death within 24 h and then daily for 14 d.

2.5. Gentamicin induced nephrotoxicity in rats

Twenty-four Wistar rats (150–170 g) were divided into 4 groups of 6 animals each. Group A: control rats (CON) that received normal saline (*i.p.*) and 0.5% carboxymethyl cellulose (CMC) (*p.o.*) for 8 days. Group B: gentamicin-treated rats (GM) that received 100 mg/kg GM (*i.p.*) and 0.5% CMC (*p.o.*) for 8 d[18]. Group C: (GM+SXE 200) treated rats that received 100 mg/kg GM (*i.p.*) and 200 mg/kg SXE (*p.o.*) for 8 d. Group D: (GM+SXE 400) treated rats that received 100 mg/kg GM (*i.p.*) and 400 mg/kg SXE (*p.o.*) for 8 d. After collection of blood and urine animals were sacrificed by cervical dislocation under mild ether anaesthesia and kidneys were harvested, rinsed in saline and stored at –80°C till further biochemical analysis.

2.6. Plasma and urine markers of renal damage

Rats of each group were individually housed in metabolic cages for 24 h and urine was collected on the 8th day of the treatment. Blood samples were collected from these overnight fasted animals through retro-orbital plexus puncture in ethylene diamine tetra acetic acid coated vials and plasma was separated by cold centrifugation of vial at

3 000 rpm for 10 min. Urea and creatinine were assayed in plasma and urine using commercially available kits (Reckon Diagnostics Ltd., Mumbai, India) as per instruction of the manufacturer and blood urea nitrogen (BUN) concentration was also measured as an indicator of renal function[19].

2.7. Preparation of homogenate of renal tissue

After the completion of the experiment, the kidneys were excised, weighed and homogenized in chilled Tris buffer (10 mM, pH 7.4) at a concentration of 10% (w/v) (Potter–Elvehjem glass homogenizer). Homogenates were then centrifuged at 12 000 rpm for 20 min (4 °C) in a high speed and supernatant and sediment were used for further biochemical estimations.

2.8. Measurement of renal lipid peroxidation

Measurement of malonaldehyde as an index for lipid peroxidation (LPO) was done using thiobarbituric acid assay as per Buege and Austl[20].

2.9. Measurement of renal antioxidants

Superoxide dismutase (SOD) was assayed in tissue supernatant by the method of Kakkar *et al*[21] based on the inhibition of the formation of nicotinamide adenine dinucleotide–phenazine methosulfate–nitro blue tetrazolium formazan. Catalase (CAT) activity in tissue supernatant was measured spectrophotometrically at 240 nm by calculating the rate of degradation of hydrogen peroxide, the substrate of the enzyme[22]. Reduced glutathione (GSH) content in tissue supernatant was measured spectrophotometrically by using Ellman's reagent (Dinitrothiobenzoic acid) as a colouring reagent, following the method described by Beutler *et al*[23]. Whereas, ascorbic acid (AA) content was assayed in tissue sediment by the method of Roe and Kuether[24] using 2–4 dinitro phenyl hydrazine.

2.10. Histopathological examination

Pieces of kidney from each group were fixed immediately in 10% neutral formalin for a period of at least 24 h, dehydrated in graded (50%–100%) alcohol and embedded in paraffin, cut into 4–5 μ m thick sections and stained with hematoxylin–eosin. The sections were evaluated for the pathological symptoms of nephrotoxicity.

2.11. Statistical analysis

The values were represented as mean \pm SEM. for six rats. Analysis of variance (ANOVA) test was followed by individual comparison by Newman–Keuls test using Prism Pad software (version 3.0) for the determination of level of significance. The values of $P < 0.05$ was considered statistically significant.

3. Results

3.1. Acute toxicity studies

SXE produces no mortality at 2 000 mg/kg. Therefore, one-tenth of the maximum no mortality dose of extract were selected as therapeutic lowest dose (200 mg/kg) and just double of it as highest dose (400 mg/kg) respectively, in this study.

3.2. Effect of SXE on kidney weight

The effect various doses of SXE were studied on kidney wt. in GM intoxicated animals. Renal injury induced by GM caused significant increases the kidney wt. by 81.13% compared to control group. The percentage protection in kidney wt. of treated groups at 200 mg/kg as 15.62 ($P < 0.05$) when compared to toxic group while maximum percentage protection in kidney wt. at the dose of 400 mg/kg *i.e.* 36.45 ($P < 0.001$). Table 1 shows that, GM treated rats' registered significant ($P < 0.001$) increment in kidney weight.

3.3. Effect of SXE on urine output

The effect various doses of SXE were studied on urine outflow (Table 1) in GM intoxicated animals. GM caused significant decreases the urine outflow by 39.74% compared to control group. The percentage augmentation in urine outflow of treated groups at 200 mg/kg as 34.04 ($P < 0.05$) when compared to toxic group while maximum percentage augmentation in urine outflow at the dose of 400 mg/kg *i.e.* 57.44 ($P < 0.001$).

3.4. Effect of SXE on urea and creatinine in plasma and urine

The effect various doses of SXE were studied on urea and creatinine in GM intoxicated animals. Renal injury induced by GM caused significant changed in renal marker in plasma as urea by 178.54%, Creatinine by 170.78% but in case of urea and creatinine in urine 93.2% and 195.82% respectively compared to control group. The percentage protection in renal marker in plasma of treated groups at 200 mg/kg as urea 18.81 ($P < 0.01$), creatinine 16.59 ($P < 0.05$), while these markers in urine 12.83 ($P < 0.01$) and 15.4 ($P < 0.05$) respectively when compared to toxic group while maximum percentage protection in renal markers in plasma at the dose of 400 mg/kg as urea by 50.52% ($P < 0.001$), Creatinine by 45.22% ($P < 0.001$) but in case of urea and Creatinine in urine 41.57% ($P < 0.001$) and 43.59% ($P < 0.001$) respectively (Table 1).

3.5. Estimation of renal lipid peroxidation

The results in Table 2 showed clear significant percentage

change in the levels of LPO in GM intoxicated rats as 169.71 ($P<0.001$) compared to control group. Treatment with SXE at the doses of 200 and 400 mg/kg significantly prevented this heave in levels and the percentage protection in LPO were 16.97 ($P<0.01$) and 42.07 ($P<0.001$) respectively.

3.6. Estimation of renal antioxidants

The percentage changed of SOD, CAT, GSH and ascorbic acid (Table 2) in GM intoxicated group were as 55.65 ($P<0.001$), 60.36 ($P<0.001$), 51.84 ($P<0.001$) and 31.28 ($P<0.001$) respectively. The percentage protection in SOD as 41.01 ($P<0.01$), 88.63 ($P<0.001$), CAT 32.58 ($P<0.05$), 98.72 ($P<0.001$) and GSH 37.51 ($P<0.05$), 81.12 ($P<0.001$) while in ascorbic acid 12.19 ($P<0.05$), 29.29 ($P<0.001$) at the doses levels 200 and 400 mg/kg, respectively. In different doses level of SXE, 400 mg/kg has shown maximum protection which was almost comparable to those of the normal control.

3.7. Effect of SXE on serum blood urea nitrogen

The effect various doses of SXE were studied on serum blood urea nitrogen in GM intoxicated animals. Renal injury induced by GM caused significant changed BUN in plasma by 53.94% compared to control group. The percentage protection in blood urea nitrogen of treated groups at 200 mg/kg as 12.31 ($P<0.05$) when compared to toxic group while maximum percentage protection in blood urea nitrogen at the dose of 400 mg/kg as by 24.13 ($P<0.001$) respectively.

3.8. Histopathological observations

The histological changes in kidneys and pathological

manifestations are presented in Figure 1. The nephrotoxicity were confirmed by evaluating the pathological symptoms such degeneration, desquamation, necrosis in tubules, intertubular haemorrhage; hyaline casts in tubules, congestion and swelling in glomerulus. Treatment with the SXE extract 200 and 400 mg/kg body weight ameliorated the toxic manifestations in the kidney. The histopathological observations supported this conclusion.

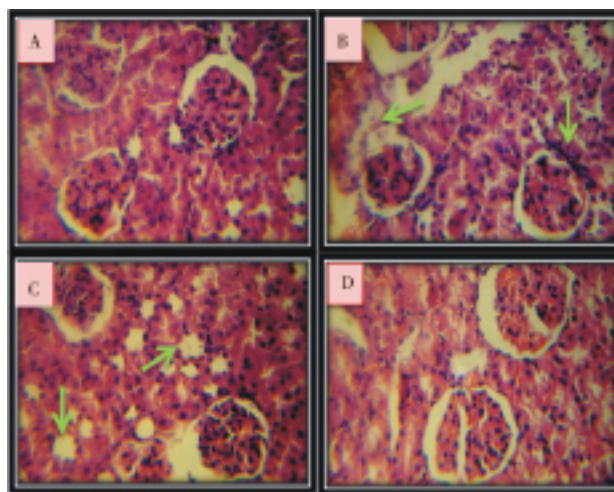


Figure 1. Histological study of kidney tissue in control and experimental groups of rats.

(A) Normal morphological view of renal sections in control group. (B) Histopathological view of renal sections in GM treated group showed the degeneration, desquamation, necrosis in tubules, and swelling in glomerulus (indicated by arrows) as compared to control group. (C) Animal treated with SXE 200 mg/kg karyopycnosis (indicated by arrow) and slight tubular degenerative and necrotic changes (D) Animal treated with SXE 400 mg/kg showed regeneration in tubular epithelial cells.

Table 1

Effect of SXE on kidney weight, urine output, plasma urea, plasma creatinine, urine urea and urine creatinine level against GM induced nephropathy in rats ($n=6$).

Groups	Kidney weight (mg/100 body weight)	Urine output (mL/h)	Plasma		Urine	
			Urea (mg/dL)	Creatinine (mg/dL)	Urea (mg/dL)	Creatinine (mg/dL)
CON	0.53 ± 0.04	0.78 ± 0.07	23.49 ± 1.20	0.89 ± 0.14	61.23 ± 2.01	11.26 ± 1.20
GM	0.96 ± 0.06*	0.47 ± 0.02*	65.43 ± 3.00*	2.41 ± 0.11*	118.31 ± 4.30*	33.31 ± 1.60*
GM + SXE 200	0.81 ± 0.05 [#]	0.63 ± 0.03 [#]	53.12 ± 2.80 ^{##}	2.01 ± 0.15 [#]	103.12 ± 4.10 ^{##}	28.18 ± 1.50 [#]
GM + SXE 400	0.61 ± 0.05 ^{###}	0.74 ± 0.04 ^{###}	32.37 ± 2.20 ^{###}	1.32 ± 0.12 ^{###}	69.12 ± 2.90 ^{###}	18.79 ± 1.30 ^{###}

Values are mean ± S.E.M. * $P<0.001$ when compared with respective control group CON. [#] $P<0.05$, ^{##} $P<0.01$, ^{###} $P<0.001$ when compared with group (GM).

Table 2

Effect of SXE on SOD (Units/mg protein), CAT (μ mol of H_2O_2 consumed/mg protein), GSH (μ g/mg protein), LPO (nmol of malonaldehyde formed/mg protein), AA (mg/g of tissue) and BUN (mg/dl)]level against GM induced nephropathy in rats ($n=6$).

Groups	SOD	CAT	GSH	LPO	AA	BUN
CON	14.68 ± 0.90	41.66 ± 2.90	102.2 ± 6.20	13.87 ± 0.80	1.79 ± 0.05	15.72 ± 0.60
GM	6.51 ± 0.30*	16.51 ± 1.60*	49.21 ± 4.30*	37.41 ± 1.30*	1.23 ± 0.03*	24.21 ± 0.90*
GM + SXE 200	9.18 ± 0.40 ^{##}	21.89 ± 1.90 [#]	67.67 ± 4.00 [#]	31.06 ± 1.40 ^{##}	1.38 ± 0.04 [#]	21.22 ± 0.80 [#]
GM + SXE 400	12.28 ± 0.70 ^{###}	32.81 ± 2.10 ^{###}	89.13 ± 5.10 ^{###}	21.67 ± 1.20 ^{###}	1.59 ± 0.06 ^{###}	18.36 ± 0.70 ^{###}

Values are mean ± SEM. * $P<0.001$ when compared with respective control group CON. [#] $P<0.05$, ^{##} $P<0.01$, ^{###} $P<0.001$ when compared with group (GM).

4. Discussion

Nephrotoxicity is an undesired side effect of chemotherapy in general. Most chemotherapy drugs targets pathways that are essential to dividing cells[25]. Several studies have now documented the importance of reactive oxygen metabolites in gentamicin induced renal damage[26]. Nephrotoxicity of the drugs is usually associated with their accumulation in renal cortex, dependent upon their affinity to kidneys and on kinetics of drug trapping process[27]. The nephrotoxicity of aminoglycoside antibiotics, and specially that of the most commonly used compound, gentamicin, is well documented[28,29]. Several studies have reported that oxygen-free radicals are considered to be important mediators of GM-induced acute renal failure.

GM induced nephrotoxicity is characterized by elevated levels of urea and creatinine in plasma as well as urine, severe proximal tubular necrosis, renal failure[30] and weight of kidney were found to be significantly increased in rats treated with only GM[31]. Similar pattern of changes were also observed in our study following GM treatment. SXE supplementation to GM treated rats recorded decrement in levels of urea and creatinine in plasma as well as urine. These observations indicate at an improved renal function in form of effective clearance of urea and creatinine. GM-treated rats showed that there was a significant decrease in urine volume as compared to control. But after the treatment with SXE the urine volume was significantly increase as compared to GM group. In fact, 400 mg/kg SXE increased the urine volume to the level of the control. Decrement in activity levels of renal SOD, CAT and GSH following GM treatment are in accordance with previous report on GM induced suppression of endogenous enzymatic antioxidant machinery[32]. SXE treatment efficiently prevented GM induced decrease in activity levels of SOD, CAT and GSH. A relationship between nephrotoxicity and oxidative stress has been confirmed in many experimental models[33–35].

The elevated level of MDA, a marker of lipid peroxidation, indicates increased free-radical generation in the GM-induced nephrotoxicity[36]. GM-induced increment in MDA content of plasma was significantly prevented by SXE treatment in the present study. GM-induced increment in MDA content of plasma was significantly prevented by SXE treatment in the present study. Therefore, the significantly lower levels of MDA in the tissues of treated groups as compared with the GM group indicate attenuation of lipid peroxidation. This was probably due to less damage by oxygen-free radicals with SXE. The involvement of oxygen-free radicals in tissue injuries is well established[37]. Also, GM+SXE (200 and 400) groups recorded significantly higher levels of AA as compared to GM group, thus indicating that SXE treatment prevents GM induced depletion in levels of renal non-enzymatic antioxidants. GM administration to control rats produced a typical pattern of nephrotoxicity which was manifested by marked increase in serum BUN[38].

SXE supplementation to GM treated rats recorded decrement in levels of blood urea nitrogen in plasma.

Histopathological results demonstrating structural changes in renal tissue of aminoglycoside antibiotics such as GM were reported by some researchers[39,40]. Histopathological view of renal sections in GM treated group showed the degeneration, desquamation and necrosis in tubules and swelling in glomerulus, as compared to control group. Glomerular and tubular epithelial changes were considerably mild in the groups treated with GM+SXE-200 and GM+SXE 400 *i.e.* animal treated with SXE 200 mg/kg showed karyopiconosis and mild tubular epithelial changes while in case of animal treated with SXE 400 mg/kg showed regeneration in tubular epithelial cells. We think that, morphological changes in kidneys were because of GM injection, but these changes tended to be considerably mild in GM plus SXE treatment. In summary, our data indicate that GM-induced nephrotoxicity might be related to oxidative damage. Co-administration of SXE lessened the negative effects of GM-induced nephrotoxicity possibly by inhibiting free radical mediated process. Further investigation of these promising protective effects of SXE against GM-induced renal injury may have a considerable impact on developing clinically feasible strategies to treat patients with renal failure.

Conflict of interest statement

We declare that we have no conflict of interest.

Acknowledgements

The author(s) would like to acknowledge gratefully the efficient help extended by the Director of CSIR-National Botanical Research Institute for providing necessary facilities for this research work.

References

- [1] Kohn S, Fradis M, Robinson E, Iancu TC. Hepatotoxicity of combined treatment with cisplatin and gentamicin in the guinea pig. *Ultrastruct Pathol* 2005; **29**: 129–137.
- [2] Nagai J, Takano M. Molecular aspects of renal handling of aminoglycosides and strategies for preventing the nephrotoxicity. *Drug Metab Pharmacokin* 2004; **19**: 159–170.
- [3] Khan SA, Priyamvada S, Farooq N, Khan S, Wasim KM, Yusufi ANK. Protective effect of green tea extract on gentamicin-induced nephrotoxicity and oxidative damage in rat kidney. *Pharmacol Res* 2009; **59**: 254–262.
- [4] Pedraza-Chaverri J, Maldonado PD, Medina-Campos ON, Olivares-Corichi IM, Grandos-Silvestre M, Hernandez-Pando R, et al. Garlic ameliorates gentamicin nephrotoxicity: relation to antioxidants. *Free Radic Biol Med* 2000; **29**: 602–611.

- [5] Singh OM, Singh TP. Phytochemistry of *Solanum xanthocarpum*: an amazing traditional healer. *J Sci Ind Res* 2010; **69**: 732–734.
- [6] Kiritkar KR, Basu BD. *Indian Medicinal Plants*. 2nd ed. Bishen Singh Mahendra Pal Singh: Dehradun; 2005, p. 1759–1762.
- [7] Kar DM, Maharana L, Pattnaik S, Dash GK. Studies on hypoglycaemic activity of *Solanum xanthocarpum* Schrad. & Wendl. fruit extract in rats. *J Ethnopharmacol* 2006; **108**: 251–256.
- [8] Paul AT, Vir S, Bhutani KK. Liquid chromatography–mass spectrometry–based quantification of steroidal glycoalkaloids from *Solanum xanthocarpum* and effect of different extraction methods on their content. *J Chromatogr A* 2008; **1208**: 141–146.
- [9] Balachandran P, Govindaraja R. Cancer an ayurvedic perspective. *Pharmacol Res* 2005; **51**: 19–30.
- [10] Patel VB, Rathod IS, Patel JM, Brahmbhatt MR. Anti–uro lithiatic and natriuretic activity of steroidal constituents of *Solanum xanthocarpum*. *Der Pharma Chemica* 2010; **2**: 173–176.
- [11] Thongchai W, Liawruangrath B, Liawruangrath S. Sequential injection analysis with lab–at–valve (SI–LAV) for the determination of solasodine in *Solanum* species. *Talanta* 2010; **81**: 565–571.
- [12] Singh OM, Singh TP. Phytochemistry of *Solanum xanthocarpum* an amazing traditional healer. *J Sci Ind Res* 2010; **69**: 732–740.
- [13] Bhutani KK, Paul AT, Fayad W, Linde S. Apoptosis inducing activity of steroidal constituents from *Solanum xanthocarpum* and *Asparagus racemosus*. *Phytomedicine* 2010; **17**: 789–793.
- [14] Shahjahan M, Vani G, Shyamaladev CS. Effect of *Solanum trilobatum* on the antioxidant status during diethyl nitrosamine induced and phenobarbital promoted hepatocarcinogenesis in rat. *Chem Biol Interact* 2005; **156**: 113–123.
- [15] Kar DM, Maharana L, Pattnaik S, Dash GK. Studies on hypoglycaemic activity of *Solanum xanthocarpum* Schrad and Wendl fruit extract in rats. *J Ethnopharmacol* 2006; **108**: 251–256.
- [16] Gunaselvi G, Kulasekaren V, Gopal V. Anthelmintic activity of the extracts of *Solanum xanthocarpum* schrad and wendl fruits (solanaceae). *Int J Pharm Tech Res* 2010; **2**: 1772–1774.
- [17] OECD. *Guidelines for the testing of chemicals revised draft guideline 423: acute oral toxicity*. France: OECD; 2000.
- [18] Yaman I, Balıkcı E. Protective effects of *Nigella sativa* against gentamicin induced nephrotoxicity in rats. *Exp Toxicol Pathol* 2010; **62**: 183–190.
- [19] Szász G, Börner U, Busch EW, Bablok W. Enzymatic assay of creatinine in serum: comparison with Jaffé methods (author's transl). *J Clin Chem Clin Biochem* 1979; **17**: 683–687.
- [20] Buege JA, Aust SD. Microsomal lipid peroxidation. *Methods Enzymol* 1978; **52**: 302–310.
- [21] Kakkar P, Das B, Viswanathan PN. A modified spectrophotometric assay of SOD. *Indian J Biochem Biophys* 1984; **21**: 130–132.
- [22] Sinha KA. Colorimetric assay of catalase. *Anal Biochem* 1972; **47**: 389–394.
- [23] Beutler E, Duron O, Kelly BM. Improved method for the determination of blood glutathione. *J Lab Clin Med* 1963; **61**: 882–888.
- [24] Roe JH, Küether CA. The determination of ascorbic acid in whole blood and urine through 2–4 dinitrophenyl hydrazine derivative of dehydro ascorbic acid. *J Biol Chem* 1943; **147**: 399–407.
- [25] Hanigan MH, Devarajan P. Cisplatin induced nephrotoxicity: molecular mechanisms. *Cancer Ther* 2003; **1**: 47–61.
- [26] Ueda N, Kaushal GP, Shah SV. Apoptotic mechanisms in acute renal failure. *Am J Med Technol* 2000; **108**: 403–415.
- [27] Karahan I, Atessahin A, Yilmaz S, Ceribasi AO, Sakin F. Protective effect of lycopene on gentamicin–induced oxidative stress and nephrotoxicity in rats. *Toxicology* 2005; **215**: 198–204.
- [28] Cuzzocrea S, Mazzon E, Dugo L, Serraino I, Di PR, Britti D. A role for superoxide in gentamicin–mediated nephropathy in rats. *Eur J Pharmacol* 2002; **450**: 67–76.
- [29] Al MA, Mostafa AM, Al AC, Al–SO. Protective effects of oral Arabic gum administration on gentamicin nephrotoxicity in rats. *Pharmacol Res* 2002; **46**: 445–451.
- [30] Erdem A, Gundogan NU, Usubutun A, Kilinc K, Erdem SR, Kara A, et al. The protective effect of taurine against gentamicin–induced acute tubular necrosis in rats. *Nephrol Dial Transplant* 2009; **15**: 1175–1182.
- [31] Gaurav VH, Chandragauda RP, Mahesh RP. Protective effect of *Kalanchoe pinnata* pers. (Crassulaceae) on gentamicin induced nephrotoxicity in rats. *Indian J Pharmacol* 2007; **39**: 201–205.
- [32] Thounaojam MC, Jadeja RN, Devkar RV, Ramachandran AV. *Sida rhomboidea*. Roxb leaf extract ameliorates gentamicin induced nephrotoxicity and renal dysfunction in rats. *J Ethnopharmacol* 2010; **132**: 365–367.
- [33] Devipriya S, Shyamaladev CS. Protective effect of quercetin in cisplatin induced cell injury in the rat kidney. *Indian J Pharmacol* 1999; **31**: 422–426.
- [34] Arunkumar PA, Viswanatha GL, Radheshyam N, Mukund H, Belliyappa MS. Science behind cisplatin–induced nephrotoxicity in humans: A clinical study. *Asian Pac J Trop Biomed* 2011; **2**(8): 640–644.
- [35] Neeraj KG, Sharad M, Tejram S, Abhinav M, Suresh PV, Rajeev KT. Evaluation of anti–apoptotic activity of different dietary antioxidants in renal cell carcinoma against hydrogen peroxide. *Asian Pac J Trop Biomed* 2011; **2**(8): 57–63.
- [36] Kuhad A, Turkey N, Pilkhwal S, Chopra K. Effect of *Spirulina*, a blue green algae, on gentamicin–induced oxidative stress and renal dysfunction in rats. *Fundam Clin Pharmacol* 2006; **20**: 121–128.
- [37] Fox RB. Prevention of granulocyte–mediated oxidant lung injury in rats by a hydroxyl radical scavenger di– methyl thiourea. *J Clin Invest* 1984; **74**: 1456–1460.
- [38] Banday AA, Farooq N, Priyamvada S, Yusufi ANK, Khan F. Time dependent effects of gentamicin on the enzymes of carbohydrate metabolism, brush border membrane and oxidative stress in rat kidney tissues. *Life Sci* 2008; **82**: 450–459.
- [39] Polat A, Parlakpinar H, Tasdemir S, Colak C, Vardi N, Ucar M, et al. Protective role of aminoguanidine on gentamicin–induced acute renal failure in rats. *Acta Histochem* 2006; **108**: 365–371.
- [40] Sayed–Ahmed MM, Nagi N. Thymoquinone supplementation prevents the development of gentamicin–induced acute renal toxicity in rats. *Clin Exp Pharmacol Physiol* 2007; **34**: 399–405.