



Contents lists available at ScienceDirect

Asian Pacific Journal of Tropical Medicine

journal homepage: www.elsevier.com/locate/apjtm



Document heading doi:

# Evaluation of chemopreventive effect of *Fumaria indica* against *N*-nitrosodiethylamine and CCl<sub>4</sub>-induced hepatocellular carcinoma in Wistar rats

Talib Hussain<sup>1,2</sup>, Hefazat H Siddiqui<sup>1</sup>, Sheeba Fareed<sup>1</sup>, M Vijayakumar<sup>2</sup>, Chandana V Rao<sup>2\*</sup>

<sup>1</sup>Department of Pharmacology and Toxicology, Faculty of Pharmacy, Integral University, kursi road, Lucknow-226026, Uttar Pradesh, India

<sup>2</sup>Pharmacognosy and Ethnopharmacology Division, National Botanical Research Institute (CSIR), Rana Pratap Marg, P. B. No. 436, Lucknow 226 001, Uttar Pradesh, India

## ARTICLE INFO

### Article history:

Received 10 January 2012

Received in revised form 15 March 2012

Accepted 15 May 2012

Available online 20 August 2012

### Keywords:

*Fumaria indica*

Hepatocellular carcinoma

*N*-nitrosodiethylamine

Alkaline phosphatase

 $\alpha$ -feto protein

## ABSTRACT

**Objective:** To investigation the chemopreventive potential of *Fumaria indica* (*F. indica*) extract (FIE) on *N*-nitrosodiethylamine and CCl<sub>4</sub>-induced hepatocarcinogenesis in Wistar rats. **Methods:** The experimental animals were divided into six groups ( $n=6$ ). Hepatocellular carcinoma was induced by single intraperitoneal injection of *N*-nitrosodiethylamine (NDEA) in normal saline at a dose of 200 mg/kg body weight followed by weekly subcutaneous injections of the carcinogen, 200 and 400 mg/kg of FIE were administered orally once a day throughout the study. At the end of 20 weeks, the body weight, liver weight and relative liver weight were measured. The percentage of nodule incidence and liver cancer markers such as aspartate transaminase (AST), alanine transaminase (ALT), alkaline phosphatase (ALP),  $\gamma$ -glutamyl transferase ( $\gamma$ -GT), total bilirubin level (TBL),  $\alpha$ -feto protein (AFP) and carcinoembryonic antigen were estimated along with histopathological investigation in experimental groups of rats. **Results:** Obtained results demonstrated that the cotreatment with FIE significantly prevented the decrease of the body weight and also increased in relative liver weight caused by NDEA. The treatment with FIE significantly reduced the nodule incidence and nodule multiplicity in the rats after NDEA administration. The levels of liver cancer markers such as AST, ALT, ALP,  $\gamma$ -glutamyl transferase, TBL, AFP and carcinoembryonic antigen were substantially increased by NDEA treatment. However, FIE treatment significantly reduced the liver injury and restored the entire liver cancer markers. Histological observations of liver tissues too correlated with the biochemical observations. **Conclusions:** These finding powerfully supports that *F. indica* exert chemopreventive effect by suppressing the tumor burden and restoring the activities of hepatic cancer marker enzymes on NDEA and CCl<sub>4</sub>-induced hepatocarcinogenesis in Wistar rats.

## 1. Introduction

Hepatocellular carcinoma (HCC) or liver cancer is the sixth most common cancer and the third leading cause of cancer mortality in the world[1]. The burden of cancer is increasing in economically developing countries as a result of population aging and growth as well as, increasingly, an

adoption of cancer-associated lifestyle choices including smoking, physical inactivity, and “westernized” diets. Liver cancer in men/women is the fifth/seventh most frequently diagnosed cancer worldwide but the second/sixth most frequent cause of cancer death. An estimated 748 300 new liver cancer cases and 695 900 cancer deaths occurred worldwide in 2008[2]. Hepatitis viral infection, food additives, alcohol, fungal toxins (aflatoxins), toxic industrial chemicals, air and water pollutants are the major risk factors of liver cancer[3]. Human liver is the major site in the body that metabolizes ingested material. It has pore to carcinogenic insult. Moreover, due to the high tolerance of liver, HCC is seldom detected at the early

\*Corresponding author: Chandana V Rao, Pharmacognosy and Ethnopharmacology Division, National Botanical Research Institute (CSIR), Rana Pratap Marg, Lucknow, India.

Tel: +91 522 2297976

Fax: +91 522 2205836

E-mail: mdth\_ah@yahoo.com

stage and once detected treatment faces a poor prognosis in most cases[4]. *N*-nitrosodiethylamine (NDEA) is a potent hepatocarcinogenic nitrosamine present in tobacco smoke, water, cheddar cheese, cured and fried meals, occupational settings, cosmetics, agricultural chemicals and pharmaceutical agents[5].

NDEA is widely accepted for induction of preneoplastic lesions and hepatic tumors in rats and it is initiated by perturbations of nuclear enzymes involved in DNA repair or replication[6]. Investigations have provided evidence that NDEA causes a wide range of tumors in all animal species and such compounds are hazardous to human health[7]. NDEA-induced lesions as well as tumors in rodents show marked biochemical, histological and molecular similarity to the progression of HCC in humans[8]. Many pharmaceutical agents have been discovered by screening natural products from plants, animals, marine organisms and microorganisms. Vincristine, vinblastine, irinotecan, etoposide and paclitaxel are examples of plant-derived compounds that are being employed in cancer treatment as well as several chemicals are also known to possess chemopreventive properties against a broad spectrum of cancer[9]. Recently, identification of bioactive ingredients from medicinal plants to inhibit tumorigenesis in a variety of animal models of carcinogenesis, involving organ sites, such as the skin, lungs, oral cavity, esophagus, stomach, liver, pancreas, small intestine, colon, and prostate is gaining considerable attention[10]. Moreover, in recent years, naturally occurring plant products have getting increased attention for the intervention of malignant invasive progression in the late stage of neoplastic diseases[11].

*Fumaria indica* (*F. indica*) pugseley (Syn: *Fumaria parviflora*, Fumariaceae) is a small, scandent, branched annual herb growing wild in plains and lower hills. It has long been used as a household remedy and forms a constituent of many common Ayurvedic, Unani medicinal preparations and polyherbal liver formulation. The plant considered to be diuretic, diaphoretic, anthelmintic, laxative and used to purify blood and in obstruction of liver[12]. Pharmacological studies show that *F. indica* is a smooth muscles relaxant and possess antipyretic[13], analgesic, anti-inflammatory[14], antidiarrhoeal[15], and hepatoprotective properties[16–19]. Phytochemical investigation revealed the presence of alkaloids viz. protopine[20], parfumine, fumariline, fumaranine, fumaritine, cryptopine, paprafumicin, paprarine, papraline, reddeanine[21], narlumicine, fumarophycine, steroids viz.  $\beta$ -sitosterol, stigmasterol, campesterol, organic acid viz. caffeic acid and fumaric acid[22]. Traditionally and scientifically proved reports suggested that *F. indica* is a successful and safe hepatoprotective agent and acts in a manner similar to that of silymarin and it is a more effective inducer of Phase II enzymes indicating its anticarcinogenic properties. Therefore, present study was designed to evaluate the chemopreventive potential of *F. indica* extract (FIE) against experimentally induced hepatocarcinogenesis in rats by assessing nodule incidence and tumor marker enzymes.

## 2. Materials and methods

### 2.1. Chemicals and their sources

All the chemicals used were of analytical grade and procured from Sigma chemicals Co., USA and Qualigens fine chemicals, Mumbai, India.

### 2.2. Plant extraction and standardization

The fresh plant of *F. indica* was collected in the botanical garden of National Botanical Research Institute, India in January 2010. The plant material was identified and authenticated and the voucher specimen number (NAB 180023) was deposited in the departmental herbarium. The air dried powdered material (1000 g) was extracted with petroleum ether thrice to remove fatty material and further marc was exhaustively extracted thrice with 50% aqueous ethanol by cold percolation method at room temperature. The extract was separated by filtration, concentrated at  $(40\pm 1)^\circ\text{C}$  on rotavapour (Buchi, USA) to yield 9.85% (w/w) of FIE. Preliminary qualitative phytochemical screening of FIE has given the positive testes for alkaloids, glycosides, flavonoids, tannins, saponins, steroids and triterpenoids.

### 2.3. Animals

Wistar albino rats (150–170 g) and Swiss albino mice (25–30 g) were procured from the National Laboratory Animal Centre, Central Drug Research Institute, Lucknow, India. The animals were housed separately in polypropylene cage at temperature of  $(22\pm 2)^\circ\text{C}$  and 50%–60% relative humidity, with a 12 h light/dark cycle respectively, for one week before and during the experiment. Animals were allowed to access standard rodent pellet diet (Dayal animal feed, India) and drinking water. Food was withdrawn 18–24 h before the experiment though water was allowed *ad libitum* and allocated to different experimental groups. All studies were performed according to the guidelines for the care and use of laboratory animals, as adopted and promulgated by the Institutional Animal Care Committee, CPCSEA, India (Reg. No. 1213/ac/2008/CPCSEA/IU).

### 2.4. Toxicity studies

Acute toxicity study was performed for FIE according to the OECD guideline for acute toxic classic method[23]. Three female albino mice were used for each step in this study. The animals were kept fasting for overnight only on water, after which the extracts were administered orally at the single dose of 300 mg/kg and closely observed for the initial 4 h after the administrations, and then once daily for 14 d. If mortality occurred in two out of three animals, then this dose was assigned as toxic dose. If the mortality occurred in one animal, then this same dose was repeated to confirm the toxic dose. If mortality did not occur, the procedure was repeated for further higher dose, i.e., 2000 mg/kg. One-tenth and one-fifth of the maximum tolerated dose of the extract tested for acute toxicity were selected for evaluation

of chemopreventive effect of FIE, *i.e.*, 200 and 400 mg/kg.

### 2.5. Experimental design and induction of HCC

The experimental animals were divided into six groups, each group comprising of six animals ( $n=6$ ) for a study period of 20 weeks. Group I served as normal control and treated with 0.9% normal saline throughout the study. HCC was induced in groups II, III, IV and V with single intraperitoneal injection of NDEA in normal saline at a dose of 200 mg/kg body weight followed by weekly subcutaneous injections of  $\text{CCl}_4$  (3 mL/kg/week) for 6 weeks, as the promoter of carcinogenic effect<sup>[24]</sup>. After administration of NDEA, test groups III and IV were administered orally 200 and 400 mg/kg FIE, respectively, in the form of aqueous suspension daily once a day throughout the study. Group V received silymarin, the known hepatoprotective and anti-hepatocellular carcinoma compound at a dose of 200 mg/kg<sup>[4,7]</sup>. The dose of FIE (400 mg/kg alone) was administered orally to rats of group VI. The experiment was terminated at the end of 20 weeks of experimental period, the body weight of each rat was taken before sacrifice. The overnight fasted animals were anaesthetized and sacrificed 48 h after the last dose of the drug. Blood was collected by retro-orbital plexus followed by heart puncture and allowed to clot before centrifugation at 2 500 *g* for 15 min at 4 °C to separate serum. The liver tissue was washed twice with ice cold saline, blotted, dried, observed for the presence of nodules and then weighed. The relative liver weight was calculated as the percentage ratio of liver weight to the body weight. A small portion of the tissue was fixed in formalin for histological examination.

### 2.6. Assessment of liver injury markers and liver tumor markers

The activities of biochemical parameters like aspartate transaminase (AST) and alanine transaminase (ALT) were estimated by the method of Reitman and Frankel<sup>[25]</sup> while alkaline phosphatase (ALP) and  $\gamma$ -glutamyl transferase ( $\gamma$ -GT) were estimated by methods of King<sup>[26]</sup> and Szasz's<sup>[27]</sup>, respectively. Total bilirubin level (TBL) was determined by modified dimethyl sulfoxide (DMSO) method<sup>[28]</sup> on the basis of sulfanilic acid reaction with sodium nitrite to produce deoxidized sulfanilic acid. Quantitative estimation of tumor markers-  $\alpha$ -feto protein (AFP) and carcinoembryonic

antigen (CEA) was based on solid phase enzyme linked immunosorbent assay using the UBI MAGIWELL (USA) enzyme immunoassay kit<sup>[29–30]</sup>.

### 2.7. Histopathological assessment

For histologic studies, the liver sections were made immediately from the liver of different groups of rats, fixed in 10% formalin, dehydrated in gradual ethanol (50%–100%), cleared in xylene, and embedded in paraffin wax. Sections were cut at 4  $\mu$  m thick (Automatic tissue processor, Lipshaw) in a rotary microtone and the pathological changes were observed microscopically after staining with hematoxylin and eosin (H&E).

### 2.8. Statistical analysis

The data were represented as mean  $\pm$  SEM. for six rats. Analysis of variance (ANOVA) test was followed by individual comparison by Newman-Keuls test using Prism Pad software (Version 3.0) for the determination of level of significance. The value of  $P < 0.05$  was considered statistically significant.

## 3. Results

### 3.1. Effect of FIE on body weight, liver weight and relative liver weight

Table 1 shows the body weight (initial and final) and liver weights of control and experimental groups of animals. The final body weight of normal group I rats showed (243.0 $\pm$ 7.4) g which was significantly decreased to ( $P < 0.001$ ) (172.0 $\pm$ 8.6) g comparatively in group II rats following NDEA treatment. In FIE-treated group III (200 mg/kg) and IV (400 mg/kg) rats, the final body weights became significantly increased ( $P < 0.01$ ) (212.0 $\pm$ 9.8) and ( $P < 0.001$ ) (238.0 $\pm$ 9.5) g when compared to the NDEA group II, respectively. Moreover, NDEA treatment significantly increased the relative liver weight to ( $P < 0.001$ ) (5.71 $\pm$ 0.52)/100 g body weight when compared to the control [group I, (2.93  $\pm$  0.38)/100 g body weight]. However, administration of 200 and 400 mg/kg FIE significantly reduced ( $P < 0.01$  and  $P < 0.001$ ) the relative liver weight to (3.78  $\pm$  0.47) and (3.15  $\pm$  0.43)/100 g body weight, respectively, compared to (5.71  $\pm$  0.52)/100 g in NDEA treatment. FIE

**Table 1**

Effect of FIE on body weight, liver weight and relative liver weight of control and NDEA induced HCC in rats.

| Groups | Treatment                                     | Initial body weight (g) | Final body weight (g) | Liver weight (g)   | Relative liver wt. (liver weight/100 g b.w.) |
|--------|---|-------------------------|-----------------------|--------------------|--|
| I      | Control                                       | 157.0 $\pm$ 6.3         | 243.0 $\pm$ 7.4       | 7.13 $\pm$ 0.41    | 2.93 $\pm$ 0.08                              |
| II     | NDEA (200 mg/kg) + $\text{CCl}_4$ (3 mL/kg)   | 159.0 $\pm$ 5.8         | 172.0 $\pm$ 8.6**     | 9.82 $\pm$ 0.53*   | 5.71 $\pm$ 0.52**                            |
| III    | FIE (200 mg/kg) + NDEA + $\text{CCl}_4$       | 154.0 $\pm$ 5.1         | 212.0 $\pm$ 9.8###    | 8.03 $\pm$ 0.67#   | 3.78 $\pm$ 0.47###                           |
| IV     | FIE (400 mg/kg) + NDEA + $\text{CCl}_4$       | 160.0 $\pm$ 4.7         | 238.0 $\pm$ 9.5###    | 7.51 $\pm$ 0.43### | 3.15 $\pm$ 0.43###                           |
| V      | Silymarin (200 mg/kg) + NDEA + $\text{CCl}_4$ | 155.0 $\pm$ 7.9         | 240.0 $\pm$ 7.2###    | 7.37 $\pm$ 0.38### | 3.07 $\pm$ 0.35###                           |
| VI     | FIE alone (400 mg/kg)                         | 154.0 $\pm$ 4.2         | 241.0 $\pm$ 8.4       | 6.95 $\pm$ 0.35    | 2.88 $\pm$ 0.31                              |

Values are expressed as mean  $\pm$  SEM of 6 rats in each group. \* $P < 0.01$ , \*\* $P < 0.001$  compared with respective control group I. # $P < 0.05$ , ### $P < 0.01$  and #### $P < 0.001$  compared with group II (NDEA +  $\text{CCl}_4$ ).

treated group IV activity was less to standard silymarin-treated group V rats at the concentration used. The animals treated with FIE alone (400 mg/kg) showed no significant change in the body weight and relative liver weight when compared to control group I.

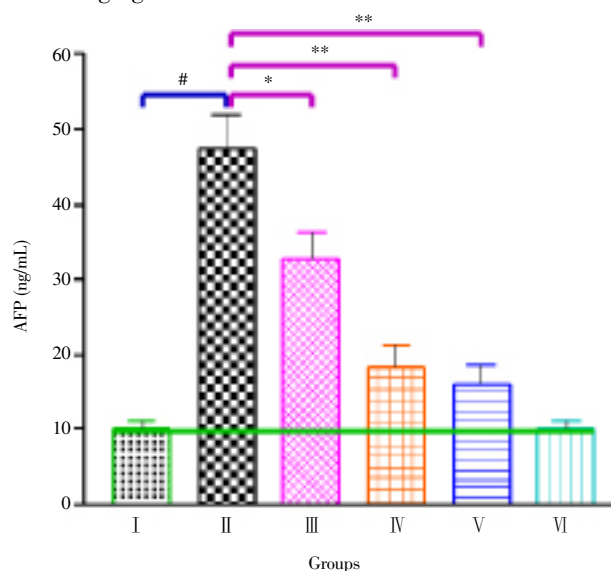
### 3.2. Effect of FIE on the development of liver nodules

Table 2 shows the total number of nodules, nodule incidence and average no of nodules per nodule bearing liver in the normal and experimental groups of animals. When rats were treated with NDEA (group II), 100% developed nodules in the liver were observed, whereas administration of FIE 200 mg/kg (group III) and 400 mg/kg (group IV) showed marked decrease in the number and multiplicity of the nodules as compared to group II rats. The incidence of nodule growth was reduced to 66.67% in group III and 33.33% in group IV, respectively. The nodule incidence of FIE treated group IV was less to standard silymarin treated group V rats. The occurrence of hepatic nodules was not observed in the normal group I and FIE alone treated group VI animals.

### 3.3. Effect of FIE on liver injury and cancer markers

The effect of FIE on liver injury is shown in Table 3, NDEA-treated group II rats showed increased serum AST [ $353.12 \pm 20.23$  U/L,  $P < 0.001$ ], ALT [ $203.57 \pm 16.68$  U/L,  $P < 0.001$ ], ALP [ $142.65 \pm 10.12$  U/L,  $P < 0.001$ ],  $\gamma$  GT [ $133.42 \pm 14.43$  U/L,  $P < 0.001$ ] and TBL [ $2.14 \pm 0.23$  mg/dL,  $P < 0.001$ ] compared to control group I rats [ $92.13 \pm 11.06$  U/L,  $(38.81 \pm 5.11)$  U/L,  $(57.14 \pm 5.77)$  U/L,  $(29.56 \pm 4.37)$  U/L and  $(0.73 \pm 0.09)$  mg/dL], respectively. In contrast, the FIE-cotreated groups III and IV rats at 200 and 400 mg/kg significantly decreased AST [ $247.63 \pm 16.47$ ] and  $(129.18 \pm$

$12.67)$  U/L,  $P < 0.001$ ], ALT [ $(133.41 \pm 12.22)$  and  $(68.81 \pm 8.91)$  U/L,  $P < 0.001$ ], ALP [ $(111.56 \pm 8.17)$  and  $(84.76 \pm 8.63)$  U/L,  $P < 0.01$  and  $P < 0.001$ ],  $\gamma$  GT [ $(92.13 \pm 9.82)$  and  $(49.48 \pm 5.13)$  U/L,  $P < 0.01$  and  $P < 0.001$ ] and TBL [ $(1.48 \pm 0.16)$  and  $(0.96 \pm 0.11)$  mg/dL,  $P < 0.01$  and  $P < 0.001$ ], respectively compared to group II animals. Figure 1 and 2 depicted the levels of the tumor markers AFP and CEA. Their levels were found to be increased significantly (AFP,  $47.23 \pm 4.71$  ng/mL; CEA,  $6.81 \pm 0.83$  ng/mL,  $P < 0.001$ ) in NDEA-induced rats whereas they were significantly decreased [AFP,  $(32.73 \pm 3.42)$  and  $(18.31 \pm 2.91)$  ng/mL,  $P < 0.01$  and  $P < 0.001$ ; CEA,  $(4.63 \pm 0.61)$  and  $(2.39 \pm 0.47)$  ng/mL,  $P < 0.01$  and  $P < 0.001$ ] on cotreatment with 200 and 400 mg/kg of FIE.



**Figure 1.** Effect of FIE on the levels of AFP in the serum of control and NDEA induced HCC in rats.

\* $P < 0.001$  compared with respective control group I. # $P < 0.01$  and \*\* $P < 0.001$  compared with group II (NDEA + CCl<sub>4</sub>).

**Table 2**

Effect of FIE on the development of nodules in the liver of control and NDEA induced HCC in rats.

| Groups | Treatment                                       | Nodules incidence [n(%)] | Total no of nodules | Average no of nodules/nodules bearing liver |
|--------|---|--------------------------|---------------------|---|
| I      | Control   | 0(0.00)                  | 0                   | 0.0   |
| II     | NDEA (200 mg/kg) + CCl <sub>4</sub> (3 mL/kg)   | 6(100.00)                | 43                  | 7.2   |
| III    | FIE (200 mg/kg) + NDEA + CCl <sub>4</sub>       | 4(66.67)                 | 27                  | 6.8   |
| IV     | FIE (400 mg/kg) + NDEA + CCl <sub>4</sub>       | 2(33.33)                 | 13                  | 6.5   |
| V      | Silymarin (200 mg/kg) + NDEA + CCl <sub>4</sub> | 2(33.33)                 | 9                   | 4.5   |
| VI     | FIE alone (400 mg/kg)                           | 0(0.00)                  | 0                   | 0.0   |

Values are expressed as mean of 6 rats in each group.

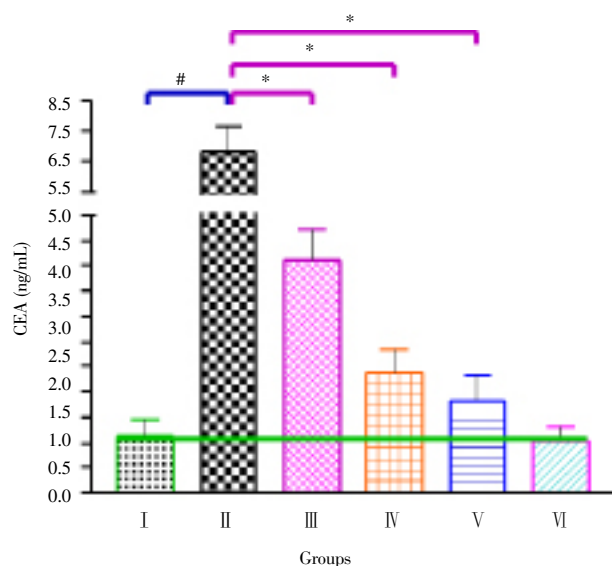
**Table 3**

Effect of FIE on the activities of marker enzymes in the serum of control and NDEA induced HCC in rats.

| Groups | Treatment                                       | AST (U/L)                    | ALT (U/L)                    | ALP (U/L)                  | $\gamma$ -GT (U/L)         | TBL (mg/dL)               |
|--------|---|------------------------------|------------------------------|----------------------------|----------------------------|---------------------------|
| I      | Control   | 92.13 ± 11.06                | 38.81 ± 5.11                 | 57.14 ± 5.77               | 29.56 ± 4.37               | 0.73 ± 0.09               |
| II     | NDEA (200 mg/kg) + CCl <sub>4</sub> (3 mL/kg)   | 353.12 ± 20.23*              | 203.57 ± 16.68*              | 142.65 ± 10.12*            | 133.42 ± 14.43*            | 2.14 ± 0.23*              |
| III    | FIE (200 mg/kg) + NDEA + CCl <sub>4</sub>       | 247.63 ± 16.47 <sup>##</sup> | 133.41 ± 12.22 <sup>##</sup> | 111.56 ± 8.17 <sup>#</sup> | 92.13 ± 9.82 <sup>#</sup>  | 1.48 ± 0.16 <sup>#</sup>  |
| IV     | FIE (400 mg/kg) + NDEA + CCl <sub>4</sub>       | 129.18 ± 12.67 <sup>##</sup> | 68.81 ± 8.91 <sup>##</sup>   | 84.76 ± 8.63 <sup>##</sup> | 49.48 ± 5.13 <sup>##</sup> | 0.96 ± 0.11 <sup>##</sup> |
| V      | Silymarin (200 mg/kg) + NDEA + CCl <sub>4</sub> | 114.36 ± 10.21 <sup>##</sup> | 54.17 ± 6.47 <sup>##</sup>   | 68.54 ± 5.31 <sup>##</sup> | 38.22 ± 4.66 <sup>##</sup> | 0.87 ± 0.09 <sup>##</sup> |
| VI     | FIE alone (400 mg/kg)                           | 86.21 ± 13.01                | 36.23 ± 7.46                 | 54.43 ± 5.17               | 27.98 ± 4.13 <sup>##</sup> | 0.77 ± 0.06               |

Values are expressed as mean ± SEM of 6 rats in each group. \* $P < 0.001$  compared with respective control group I. # $P < 0.01$ , <sup>##</sup> $P < 0.001$  compared with group II (NDEA + CCl<sub>4</sub>).





**Figure 2.** Effect of FIE on the levels of CEA in the serum of control and NDEA induced HCC in rats.

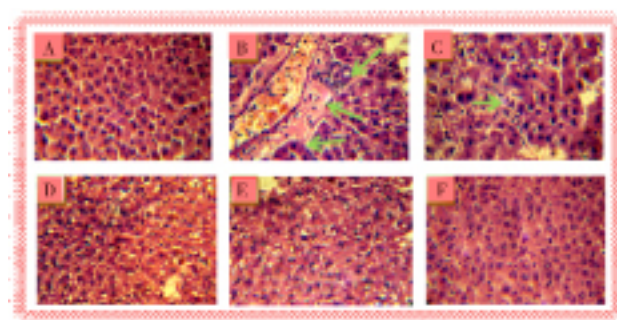
\* $P < 0.001$  compared with respective control group I. # $P < 0.05$  and ## $P < 0.001$  compared with group II (NDEA + CCl<sub>4</sub>).

### 3.4. Histopathological observations

The histopathological examinations basically support the results obtained from serum enzyme and tumor marker assays. Figure 3A revealed the normal architecture (group I) and hepatic cells with granulated cytoplasm, small uniform nuclei and nucleolus. Group II NDEA-treated rats showed loss of architecture and neoplastic cells arranged in lobules separated by fibrous septa with inflammatory collection and small bile duct proliferation. Neoplastic cells were larger than normal cells with granular cytoplasm and larger hyperchromatic nuclei and hyaline globules (arrow) that represent proteins produced by the tumor cells (Figure 3B). Architecture of liver sections of FIE cotreated (200 mg/kg) group III rats showed normal architecture with some hepatocytes and minimal inflammatory cell infiltration around the portal triads with few malignant hepatocytes. (Figure 3C), whereas FIE cotreated (400 mg/kg) group IV rats showed normal architecture with few preneoplastically transformed cells and hepatocytes maintaining near normal architecture which was almost comparable to the standard silymarin-cotreated group V rats (Figure 3D). Administration of 50% ethanolic extract of *F. indica* (400 mg/kg) alone exhibited normal architecture of hepatocytes with granulated cytoplasm (Figure 3E).

### 3.5. Effect of FIE treatment alone

Surprisingly, when FIE (400 mg/kg) was administered to the non-NDEA-treated rats, no significant changes were observed in any of the enzyme and non-enzyme activities assayed when compared to normal control group I rats. At this dose level, there were no significant changes in the histological observations depicting the non-toxic nature of FIE (Figure 3F).



**Figure 3.** Histological study of liver tissue in control and experimental groups of rats.

(A) Group I: Control animals revealed normal architecture. (B) Group II: NDEA + CCl<sub>4</sub> induced carcinoma bearing animal showing neoplastic hepatocyte with inflammatory collection and loss of architecture. Neoplastic cells were larger than normal cells with larger hyperchromatic nuclei and hyaline globules (arrow) that represent proteins produced by the tumor cells. (C) Group III: Administration of 50% ethanolic extract of FIE (200 mg/kg) on HCC bearing animal hepatocyte showing minimal inflammatory cell with few malignant hepatocytes. (D) Group IV: Administration of 50% ethanolic extract of FIE (400 mg/kg) on HCC bearing animals exhibited hepatocyte maintaining near normal architecture. (E) Group V: Administration of silymarin (200 mg/kg) on HCC bearing animals shows the structure close to proximity of normal hepatocytes. (F) Group VI: Administration of 50% ethanolic extract of *F. indica* (400 mg/kg) alone exhibited normal architecture of hepatocytes indicating the non-toxic nature of the extract.

## 4. Discussion

Natural products have long been used to prevent and treat many diseases, including cancer and thus they are good candidates for the development of anti-cancer drugs. The large population use ayurvedic medicine worldwide. Different *in vivo* and *in vitro* screening models are available for anticancer activity. The present investigation showed that oral administration of FIE counteracts the activities of tumor marker enzymes and prevents the development of HCC that is usually induced by NDEA and CCl<sub>4</sub> in experimental rats. On metabolic biotransformation of NDEA produces promutagenic products, O<sup>6</sup>-ethyldeoxyguanosine and O<sup>4</sup> and O<sup>6</sup>-ethyldeoxythymidine in liver which are responsible for their carcinogenic effects<sup>[31–37]</sup>. It is well established that CCl<sub>4</sub> induces hepatotoxicity by metabolic activation and therefore selectively causes toxicity in liver cells maintaining a semi-normal metabolic function. CCl<sub>4</sub> is bio-transformed by cytochrome P<sub>450</sub> enzyme system in the endoplasmic reticulum to produce trichloromethyl free radicals. Trichloromethyl free radicals (CCl<sub>3</sub>•) then combine with cellular lipids and proteins in the presence of oxygen to form trichloromethyl peroxy radical, which further attack lipids on the membrane of endoplasmic reticulum faster than trichloromethyl free radical. Thus, trichloromethyl peroxy free radical leads to elicitation of lipid peroxidation and destruction of Ca<sup>2+</sup> homeostasis, resulting in cell death<sup>[38]</sup>.

The results of the present study seem to provide support for the chemopreventive effects of FIE against NDEA-induced hepatocarcinogenesis in rats. There is an appreciable reduction in body weight and increase in liver weight observed in HCC bearing group II rats as compared to control group I rats. Decreased appetite and food intake contribute to the weight loss which could be an indirect indication of the declining hepatic function, an increase in the liver weight of the animals, which could be attributed to the formation of nodules and tumors in the liver following carcinogen exposure. Sreepriya and Bali<sup>[9]</sup> have also reported marked loss of body weight and increase in liver weights. The steadily increase in body weight and decrease in liver weight after FIE treatment (groups III and IV) indicate that, increased appetite and reduced tumor incidence shows its anticancer effectiveness. Administration of NDEA is reported to produce neoplastic nodules in experimental animals<sup>[9]</sup>. Group II rats given NDEA showed an incidence of 100% in the presence of nodules. Administration of FIE was able to reduce the percentage incidence of nodules as compared to group II. The effect of FIE to prevent the multiplicity of neoplastic nodules gives substantial support to the chemopreventive effects of plant extract. Hepatic damage caused by NDEA and CCl<sub>4</sub> generally reflects instability of liver cell metabolism which leads to distinctive changes in the serum enzyme activities<sup>[39]</sup>. Serum transaminases (AST and ALT), ALP, TBL and  $\gamma$ -GT are representative of liver function and their increased levels are sensitive indicators of hepatic injury<sup>[4]</sup>. Elevated activities of serum AST and ALT in NDEA and CCl<sub>4</sub> treated rats may be due to NDEA induced hepatic damage and subsequent leakage of these enzymes from the neoplastic cell into circulation<sup>[40]</sup>. In accordance with the above report we also observed an increase in liver marker enzyme as AST and ALT in NDEA and CCl<sub>4</sub> treated group II when compared to respective control group I rats. Similarly, increase in ALP reflects pathological alteration in biliary flow and discharge of TBL reflects a non-specific alteration in the plasma membrane integrity and/or permeability<sup>[4]</sup>.  $\gamma$ -GT is an enzyme embedded in the hepatocyte plasma membrane, mainly in the canalicular domain and its liberation into serum indicates damage of the cells and thus injury to liver<sup>[5]</sup>. It is important to point out that serum  $\gamma$ -GT activity is considered to be one of the best indicators of liver damage<sup>[41]</sup>. In the present investigation, cotreatment with FIE significantly lowered the enhanced level of activities of these enzymes. It is suggested that FIE aids in parenchymal cell regeneration in liver and thereby protects membrane integrity by decreased enzyme leakage against carcinogenic effect of NDEA.

AFP is widely used as tumor marker for diagnosis of HCC, which is a unique immunomodulatory glycoprotein (65 kDa) normally made by the immature liver cells in the fetus<sup>[29]</sup>. Its detection during monitoring of HCC treatment is well accepted in patients with increased AFP levels prior to therapy, and is recommended by the European Association for the Study of the Liver. It has long been recognized that exposure of rats to certain carcinogens like NDEA increases the circulating AFP levels. This corroborates the results showing significant rise in levels of AFP obtained in NDEA-induced rats<sup>[5]</sup> and AFP levels were found to be

significantly reduced in FIE cotreated (groups III and IV) rats. CEA, a member of the immunoglobulin supergene family, is a 180–200 kDa heavily glycosylated protein. Frequently it is detected in a high concentration in the serum of individuals with malignancy in the liver<sup>[30,42]</sup>. In this study, an increase in serum CEA levels following NDEA treatment was presumably associated with production rates of tumor, its location, stage, size, differentiation and vascularity. The significant reductions in the levels of CEA in FIE cotreated groups III and IV rats were presumably due to decreased production rates of tumors. To verify the anticancer activity of FIE, histopathological studies were carried out. In this investigation, marked changes were observed in the architecture of liver of cancer bearing animals. These indicate the presence of neoplastic conditions following NDEA and CCl<sub>4</sub> administration. In FIE treated animals, the NDEA and CCl<sub>4</sub> damage was recovered due to anticancer potency of *F. indica* extract. From our study, it is concluded that the oral administration of *F. indica* would exert regression of hepatocarcinogenesis induced by NDEA and CCl<sub>4</sub> may be due to restoring the activities of entire liver cancer marker enzymes and diminution in tumor incidence. Further investigations are required to understand the detailed mechanism of action which may lead to identification of potent molecules from *F. indica* against NDEA and CCl<sub>4</sub>-induced HCC.

### Conflict of interest statement

The authors declare that there are no conflicts of interest.

### Acknowledgements

The author(s) would like to acknowledge gratefully the efficient help extended by the Director of National botanical research institute (CSIR) and Honorable Vice Chancellor, Prof. S. W. Akhtar for providing necessary facilities for this research work.

### References

- [1] Ferlay J, Shin HR, Bray F, Forman D, Mathers C, Parkin DM. Estimates of worldwide burden of cancer in 2008: GLOBOCAN 2008. *Int J Cancer* 2010; **127**: 2893–2917.
- [2] Jemal A, Bray F, Center MM, Ferlay J, Ward E, Forman D. Global cancer statistics. *CA: Cancer J Clin* 2011; **61**: 69–90.
- [3] Paraskevi A, Ronald A. Hepatocellular carcinoma pathogenesis: from genes to environment. *Nat Rev Cancer* 2006; **6**: 1–14.
- [4] Singh BN, Singh BR, Sarma BK, Singh HB. Potential chemoprevention of *N*-nitrosodiethylamine-induced hepatocarcinogenesis by polyphenolics from *Acacia nilotica* bark. *Chem Biol Interact* 2009; **181**: 20–28.
- [5] Sivaramakrishnan V, Shilpa PNM, Kumar VRP, Devaraj SN. Attenuation of *N*-nitrosodiethylamine-induced hepatocellular carcinogenesis by a novel flavonol–Morin. *Chem Biol Interact* 2008; **171**: 79–88.
- [6] Khan MS, Halagowder D, Devaraj SN. Methylated chrysin, a

- dimethoxy flavone, partially suppresses the development of liver preneoplastic lesions induced by *N*-nitrosodiethylamine in rats. *Food Chem Toxicol* 2011; **49**: 173–178.
- [7] Ramakrishnan G, Raghavendran HRB, Vinodhkumar R, Devaki T. Suppression of *N*-nitrosodiethylamine induced hepatocarcinogenesis by silymarin in rats. *Chem Biol Interact* 2006; **161**: 104–114.
- [8] Feo F, Pascale RM, Simile MM, De Miglio MR, Calvisi DM, Calvisi MRD. Genetic alterations in liver carcinogenesis: implications for new preventive and therapeutic strategies. *Crit Rev Oncol* 2000; **11**: 19–62.
- [9] Sreepriya M, Bali G. Chemopreventive effects of embelin and curcumin against *N*-nitrosodiethylamine/phenobarbital-induced hepatocarcinogenesis in Wistar rats. *Fitoterapia* 2005; **76**: 549–555.
- [10] Agarwal BB, Shishodia S. Molecular targets of dietary agents for prevention and therapy of cancer. *Biochem Pharmacol* 2006; **71**: 1397–1421.
- [11] Ravindranath MH, Ramasamy V, Moon S, Ruiz C, Muthugounder S. Differential growth suppression of human melanoma cells by tea (*Camellia sinensis*) epicatechins (ECG, EGC and EGCG). *E-CAM* 2009; **6**: 523–530.
- [12] Chopra RN, Nayar SL, Chopra SN. *Glossary of Indian medicinal plants*. NISCAIR: New Delhi; 1985 p. 122.
- [13] Khattak SG, Gilani SN, Ikram M. Antipyretic studies on some indigenous Pakistani medicinal plants. *J Ethnopharmacol* 1985; **14**: 45–51.
- [14] Rao ChV, Verma AR, Gupta PK, Vijayakumar M. Anti-inflammatory and anti-nociceptive activities of *Fumaria indica* whole plant extract in experimental animals. *Acta Pharm* 2007; **57**: 491–498.
- [15] Gilani AH, Bashir S, Janbaz KH, Khan A. Pharmacological basis for the use of *Fumaria indica* in constipation and diarrhea. *J Ethnopharmacol* 2005; **96**: 585–589.
- [16] Gilani AH, Janbaz KH, Akhtar MS. Selective protective effect of the extract from *Fumaria perviflora* on paracetamol-induced hepatotoxicity. *Gen Pharmacol* 1996; **27**: 979–983.
- [17] Rao KS, Mishra SH. Anti hepatotoxic activity of monomethyl fumarate isolated from *Fumaria indica*. *J Ethnopharmacol* 1998; **60**: 207–213.
- [18] Nimbkar SR, Juvekar AR, Jogalekar SN. Hepatoprotective activity of *Fumaria indica* in hepatotoxicity induced by anti-tubercular drugs treatment. *Ind Drugs* 2000; **37**: 537–542.
- [19] Rathi A, Srivastava AK, Shirwaikar A, Rawat AKS, Mehrotra S. Hepatoprotective potential of *Fumaria indica* Pugsley whole plant extracts, fractions and an isolated alkaloid protopine. *Phytomed* 2008; **15**: 470–477.
- [20] Pandey VB, Gupta BD, Bhattacharya SK, Lal R, Das PK. Chemistry and pharmacology of the major alkaloid of *Fumaria indica*. *Curr Sci* 1971; **40**: 455–457.
- [21] Rahman AU, Bhatti MK, Choudhary MI, Ahmad SK. Alkaloidal constituent of *Fumaria indica*. *Phytochem* 1995; **40**: 593–596.
- [22] Sousek J, Guedon D, Adam T, Bochorakova H, Taborska E, Valka I, et al. Alkaloids and organic acids content of eight *Fumaria* species. *Phytochem Ana* 1999; **10**: 6–11.
- [23] Organisation for Economic Co-operation and Development. *Test no. 423: Acute oral toxicity—acute toxic class method*. Paris: Organisation for Economic Co-operation and Development; 2001.
- [24] Sundaresan S, Subramanian P. Prevention of *N*-nitrosodiethylamine-induced hepatocarcinogenesis by *S*-allylcysteine. *Mol Cell Biochem* 2008; **310**: 209–214.
- [25] Reitman S, Frankel S. A colorimetric method for the determination of serum glutamate oxaloacetate transaminase. *Am J Clin Pathol* 1957; **28**: 53–56.
- [26] King J. The hydrolases—acid and alkaline phosphatases. In: *Practical clinical enzymology*. London: Nostrand Company Limited; 1965, p. 191–208.
- [27] Szasz G. Reaction rate method for gamma glutamyl transferase activity in serum. *Clin Chem* 1976; **22**: 2051–2055.
- [28] Dangerfield WG, Finlayson R. Estimation of bilirubin in serum. *J Clin Pathol* 1953; **6**: 173.
- [29] Sell S, Beckar FF. Alpha fetoprotein. *Natl Cancer Inst* 1978; **60**: 19–26.
- [30] Macnab GM, Urbanowicz JM, Kew MC. Carcinoembryonic antigen in hepatocellular cancer. *Br J Cancer* 1978; **38**: 51–54.
- [31] Verna L, Whysner J, Williams GM. *N*-nitrosodiethylamine mechanistic data and risk assessment: bioactivation, DNA-adduct formation, mutagenicity, and tumor initiation. *Pharmacol Ther* 1996; **71**: 57–81.
- [32] Nirmala M, Girija K, Lakshman K, Divya T. Hepatoprotective activity of *Musa paradisiaca* on experimental animal models. *Asian Pac J Trop Biomed* 2011; **2**(1): 11–15.
- [33] Kiran PM, Raju AV, Rao BG. Investigation of hepatoprotective activity of *Cyathea gigantea* (Wall. ex. Hook.) leaves against paracetamol-induced hepatotoxicity in rats. *Asian Pac J Trop Biomed* 2011; **2**(5): 352–356.
- [34] Machana S, Weerapreeyakul N, Barusrux S. Anticancer effect of the extracts from *Polyalthia evecta* against human hepatoma cell line (HepG2). *Asian Pac J Trop Biomed* 2011; **2**(5): 368–374.
- [35] Singh K, Singh N, Chandy A, Manigauha A. *In vivo* antioxidant and hepatoprotective activity of methanolic extracts of *Daucus carota* seeds in experimental animals. *Asian Pac J Trop Biomed* 2011; **2**(5): 385–388.
- [36] Machana S, Weerapreeyakul N, Barusrux S, Thumanu K, Tanthanuch W. Synergistic anticancer effect of the extracts from *Polyalthia evecta* caused apoptosis in human hepatoma (HepG2) cells. *Asian Pac J Trop Biomed* 2011; **2**(8): 589–596.
- [37] Thirumalai T, David E, Therasa SV, Elumalai EK. Restorative effect of *Eclipta alba* in CCl<sub>4</sub> induced hepatotoxicity in male albino rats. *Asian Pac J Trop Dis* 2011; **1**(4): 304–307.
- [38] Rao GMM, Rao ChV, Pushpangadan P, Annie S. Hepatoprotective effects of rubiadin, a major constituent of *Rubia cordifolia* Linn. *J Ethnopharmacol* 2006; **103**: 484–490.
- [39] Wolf Jr, Harrelson CR, Nastainczyk WG, Philpot WM, Kalyanaraman RMB, Mason RP. Metabolism of carbon tetrachloride in hepatic microsomes and reconstituted monooxygenase systems and its relationship to lipid peroxidation. *Mol Pharmacol* 1980; **18**: 553–558.
- [40] Dakshayani KB, Subramanian Manivasagam PT, Essa MM, Manoharan S. Melatonin modulates the oxidant-antioxidant imbalance during *N*-nitrosodiethylamine induced hepatocarcinogenesis in rats. *J Pharm Pharmaceut Sci* 2005; **8**: 316–321.
- [41] Jeena KJ, Joy KL, Kuttan R. Effect of *Embllica officinalis*, *Phyllanthus amarus* and *Picrorrhiza kurroa* on *N*-nitrosodiethylamine induced hepatocarcinogenesis. *Cancer Lett* 1999; **136**: 11–16.
- [42] Maeda M, Tozuka S, Kanayama M, Uchida T. Hepatocellular carcinoma producing carcinoembryonic antigen. *Dig Dis Sci* 1988; **33**: 1629–1631.