



Contents lists available at ScienceDirect

Asian Pacific Journal of Tropical Medicine

journal homepage: www.elsevier.com/locate/apjtm

Document heading doi: 10.1016/S1995-7645(14)60062-6

Effect of matrine on transforming growth factor β 1 and hepatocyte growth factor in rat liver fibrosis model

Jian-Lan Yu¹, Jun-Hua Li², Rong-Gui Cheng¹, Yan-Mei Ma³, Xiao-Juan Wang³, Jing-Chun Liu^{4*}

¹Heji Hospital affiliated to Changzhi Medical School, Changzhi 046011, China

²Tumor Hospital of Shanxi Province, Taiyuan 030013, China

³Shanxi Medical School, Taiyuan 030001, China

⁴The First Clinical Hospital of Shanxi Medical School, Taiyuan 030001, China

ARTICLE INFO

Article history:

Received 10 January 2014

Received in revised form 15 February 2014

Accepted 20 April 2014

Available online 20 May 2014

Keywords:

Liver fibrosis

Matrine

Transforming growth factor β 1

Hepatocyte growth factor

ABSTRACT

Objective: To observe the preventive and control effect of matrine on transforming growth factor (TGF- β 1) and hepatocyte growth factor (HGF) of liver fibrosis tissue in rats. **Methods:** A total of 48 SD rats were randomly divided into A, B, C, D groups with 12 in each, group A as the normal control group and groups B, C, D as liver fibrosis models using composite modulus method with carbon tetrachloride (CCL₄). Group B was the model group, group C adopted γ -interferon lavage therapy in the second day of modeling, and group D adopted matrine lavage treatment, at 4 and 8 weeks after treatment. Six rats were executed for detection of TGF- β 1 and HGF, liver tissue histology and comparison fibrosis degree changes of rat liver tissue between groups. **Results:** Groups B, C, D showed a more significantly increased TGF- β 1 at each time point compared with group A ($P < 0.05$); Group B showed a more significantly increased TGF- β 1 than groups C and D at weeks 4 and 8 ($P < 0.05$); group D showed a lowest level of TGF- β 1, followed by groups C and B. HGF of group B decreased more significantly than A group at weeks 4 and 8 ($P < 0.05$); HGF of groups C and D was significantly elevated at 4 and 8 weeks than groups A and B ($P < 0.05$), in which the group D showed the highest level of HGF. According to tissue histologic observation, rat liver tissue structure of group A was clear and normal, tissue structure of group B was destroyed with obvious fibrous tissue hyperplasia and fatty change of hepatic cells; groups C and D showed a slighter liver tissue damage, cell necrosis and connective tissue hyperplasia in collect abbcy than group B with a trend of obvious improvement. **Conclusions:** Matrine can reduce TGF- β 1 expression and enhance the activity of HGF, so as to realize the inhibition effect on liver fibrosis in rats.

1. Introduction

Liver fibrosis is a process with liver cell degeneration necrosis due to various pathogenic factors and hepatic fibrous tissue excessive deposition[1–3]. Hepatic fibrosis is the early stage of liver cirrhosis which yet is the only reversible stage, and liver fibrosis is one of the important pathological features of chronic liver disease as a main intermediate link to the development of liver cirrhosis,

and if this is persist, it is quite likely to develop into liver cirrhosis, followed by liver cancer[4]. Liver cancer is the top lethal cause among tumors, which threatens the patient's life and health seriously, so it is significant for prevention of liver cirrhosis to block its pathological development of liver fibrosis stage[5]. Research has shown that a variety of cytokines and inflammatory mediators are related to liver fibrosis, and interaction of these cytokines forms a complex network, playing a key role in the formation of liver fibrosis[6]. The anti fibrosis effect of γ -interferon has gained clinically common approval, and AASLD has officially recommended it as the drug of first choice for liver fibrosis[7]. But the shortcomings as short half-life, antibodies induction and serious side effects due to a large dose limits its clinical application. Matrine has made certain achievements in the prevention and treatment of

*Corresponding author: Jing-Chun Liu, The First Clinical Hospital of Shanxi Medical School, Taiyuan 030001, China.

Tel: 13703512891

E-mail: yjlang@163.com

Foundation project: This work was supported by the Science and Technology Projects of Technology Bureau of Taiyuan City (Grant No: 11016203).

fibrosis in recent years, with a good application prospect. Modern pharmacology study has shown that curative effect of matrine on tissue fibrosis treatment is distinct^[8]. To observe the preventive and control effect of matrine on liver fibrosis, this research set up rat liver fibrosis models using composite modulus method with carbon tetrachloride^[9], combined with γ -interferon and matrine therapy in the modeling. The expression of TGF- β 1 and HGF as well as histological cell change were studied.

2. Materials and methods

2.1. Experimental animals

A total of 48 male SD rats (clean level of class II, age of 8-10 weeks) weighing (151.3±22.5) g were provided by the laboratory animal center. They were free for access to food and water. Experiment processes on animals strictly followed the "Administration Regulations on the Experimental Animals".

2.2. Instruments and reagents

CCL₄ was provided by Tianjin Fine Chemical Research Institute. Matrine was provided by Nanjing Zinze Science And Technology Development Company. Restructuring γ -interferon and olive oil for experimental use were provided with Lizhu Biological Engineering Pharmaceutical Factory. Mouse anti-human TGF- β monoclonal antibody and mouse anti-human HGF monoclonal antibody were provided by Beijing Boaosen Biological Technology Co., LTD. RT-PCR one-step kit, tissue DNA extraction kit and TRIZOL reagent were manufactured by Beijing BioTeke Biological Technology Co., LTD. S-3000N scanning electron microscope was provided by HITACHI Company (Japan), and 5804 centrifuges were provided by Eppendorf Company. Tissue array instrument and gel imaging analysis system were provided by Beecher Instruments Company (USA), and CS-930 TLC scanner was manufactured in Japan.

2.3. Animal model establishment and grouping

A total of 48 SD rats were randomly divided into groups A, B, C, D with 12 in each, group A as the normal control group, groups B, C, D as liver fibrosis models using composite modulus method with CCL₄. Subcutaneous injection of 6 mL/kg CCL₄ analytical pure concentrate reagent was adopted in initial stage of modeling, then every 3 days after modeling initiation added CCL₄ olive oil mixture 3 mL/kg sc., and from 2 weeks after modeling, adding 0.5 mL/100 g alcohol (25%) for intragastric administration once a day. Group A was treated with equivalent amount of normal saline lavage, group B was the model control group without any processing after modelling, group C adopted γ -interferon 0.2 mu/kg lavage therapy in the second day of modeling once a day, and group D adopted matrine 100 mg/kg lavage treatment in the second day of modeling once a day. All groups of rats were fed with high-fat diet.

2.4. Experimental method

At 4 and 8 weeks after treatment, six rats of each group were executed, using Western blot method for detection of rat liver tissue TGF- β 1 and HGF mRNA expression. And liver tissue specimen was taken for HE staining to observe issue morphology at 8 weeks after modeling and observation. After intraperitoneal injection of 10% chloral hydrate anesthesia, extracted the middle of liver tissue by caesarean section, soaked liver middle small blocks in 10% of formaldehyde solution for fixation; water rinsed for 2 h, processed the specimen using automatic dewatering machine for biological tissue dehydration and transparent, procedure was strictly according to operating instructions. Cut specimen into 5 μ m slice and put in oven bake at 40 °C for 1 h, xylene skim was used for 10 min, followed by conventional gradient alcohol dehydration, made the tissue blue by using distilled water hydration for 5 min, hematoxylin staining for 15 min, and water flushing for 1 min; 1% of hydrochloric acid ethanol for color separation was used for 1 min to make slice red, water rinsed for 30 min, different gradient ethanol for dehydration was used for 5 min, 95% eosin ethanol for color separation was used for 2 min, 100% ethanol I, II for dehydration was used for 2 min. Used xylene for transparency, neutral resin for sliding, and microscope for observation histological changes.

2.5. Result determination

UVP type gel image analysis system was applied to analyze integral absorbance measurement of the bands in Western blot-electrophoresis method; absorbance ratio of each group of genes with internal reference control gene was used to determine the differences of mRNA expression. The mRNA expression intensity = Absorbance density value of samples target mRNA/Absorbance density value of corresponding β -actin mRNA.

2.6. Statistical analysis

SPSS 19.0 statistical software was used for processing the group data with *t* test, and measurement data were expressed in (Mean±SD). *P*<0.05 for the difference was statistically significant.

3. Results

3.1. TGF- β 1 and HGF expression at each time point among groups

TGF- β 1 in B, C and D groups was significantly higher than that in group A at each time point (*P*<0.05). Group D showed the lowest level of TGF- β 1, followed by groups C and B. HGF in group B decreased more significantly than that in group A at weeks 4 and 8 (*P*<0.04). HGF in groups C and D was elevated more significantly than that in groups A and B at weeks 4 and 8 (*P*<0.05), in which group D showed the highest level of HGF. The results are shown in Table 1.

3.2. Tissue histologic changes observation among groups

The rat liver tissue structure in group A was clear without cell degeneration or necrosis, and liver cell line arrangement is neat with uniform cell. Tissue structure of group B was destroyed with obvious fibrous tissue hyperplasia, disappeared lobular structures and liver cell cord derangement, as well as fatty change or ballooning degeneration of hepatic cells, and severe infiltration of inflammatory cells was observed around the central vein and manifold. Compared with group B, groups C and D showed a slighter liver tissue damage, cell necrosis and connective tissue hyperplasia in collect abbacy with a trend of obvious improvement (Figure 1). The liver fibrosis histologic changes of four groups were analyzed using semi-quantitative scoring statistics (SSS). SSS score is 0 for group A, 11.62 ± 1.56 for group B, 7.59 ± 0.80 for group C and 7.43 ± 0.70 for group D. SSS scores of groups B, C and D were significantly higher than that of group A ($P < 0.05$). Scores of groups C and D were significantly lower than that of group B ($P < 0.05$). There was no statistical significant differences in SSS scores between groups C and D.

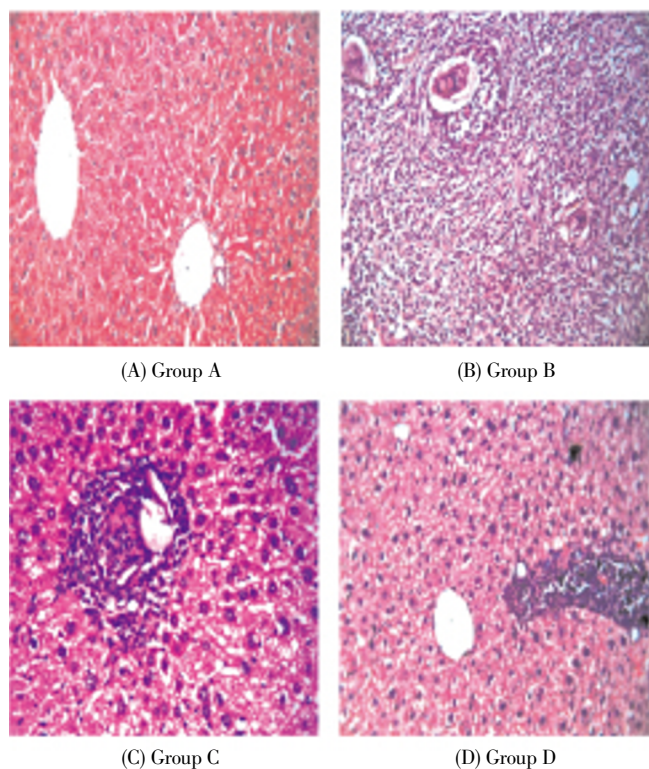


Figure 1. Tissue histologic changes of rats with liver fibrosis after treatment with matrine (HE, $\times 20$).

4. Discussion

Liver fibrosis is the repair reaction of liver of chronic damage and is also a rite among development and progression of a variety of chronic liver diseases. Of patients with liver fibrosis, 25%–40% eventually develop into liver cirrhosis and liver cancer^[10]. Studies have shown that process of liver fibrosis can be reversed^[11–13], so the reverse process of liver fibrosis is of great significance to block the formation of liver cancer. CCL_4 can dissolve the liver cell membrane, directly by the metabolism of liver cell cytochrome, start the lipid peroxidation of liver cells, and cause liver cell damage. It is the most widely used toxic chemical for inducing liver fibrosis experiments^[14–16]. Commonly used liver fibrosis model induced methods are CCL_4 simple method and CCL_4 complex method, with respective advantages and disadvantages^[17]. The composite method is adopted to establish the experimental rat liver fibrosis model. First, CCL_4 analysis pure concentrate 6 mL/kg was adopted by subcutaneous injection. Then, 3 days later, 3 mL/kg of 50% agents with 1:1 olive oil and CCL_4 sc. was used. A week later, 25% alcohol was used to lavage the rats. All the groups of rats were fed on a high-fat diet. After 4 weeks, tissue structure of group B was destroyed with obvious fibrous tissue hyperplasia and liver cell cord derangement, as well as fatty change or ballooning degeneration of hepatic cells, and severe infiltration of inflammatory cells was observed around the central vein and manifold, showing that the composite modeling method is faster, more reliable and effective than the simple modeling method. Histological observation in this study showed, according to the modeling results after 8 weeks, liver damage, liver cell edema, extent of ballooning degeneration, liver cell necrosis, and collect abbacy connective tissue hyperplasia of group D were reduced more significantly compared with groups B. Liver tissue damage of groups C and D had no significant differences, indicating matrine can obviously improve abnormal liver fibrosis tissue structure and effectively alleviate liver cell injury.

Studies have found that TGF- β 1 is the most important role in fibrosis factor, participating in the liver fibrosis process, and closely related to occurrence and development of liver fibrosis^[18–20]. In this study, quantity of TGF- β 1 expressed in groups B, C and D was significantly higher than that in group A, which is consistent with the previous result^[19]. Groups C and D showed a significantly reduced trend of TGF- β 1 expression than group B, suggesting that γ -interferon and matrine have inhibitory effect on TGF- β 1 protein expression at the mRNA and protein level. This plays a role in anti-liver fibrosis. HGF has many kinds of biological functions, such as promoting liver function

Table 1

Expression levels of TGF- β 1 and HGF in rat liver fibrosis model treated with matrine ($n=12$).

Group	Treatment	TGF- β 1		HGF	
		4 weeks	8 weeks	4 weeks	8 weeks
Group A	Normal saline	0.84 ± 0.07	0.91 ± 0.09	1.06 ± 0.09	1.11 ± 0.09
Group B	No treatment	1.44 ± 0.11	1.68 ± 0.15	0.81 ± 0.08	0.88 ± 0.09
Group C	0.2 mu/kg γ -interferon	1.00 ± 0.08	1.17 ± 0.09	1.23 ± 0.06	1.51 ± 0.10
Group D	100 mg/kg matrine	0.96 ± 0.06	1.15 ± 0.11	1.27 ± 0.09	1.58 ± 0.15

recovery and alleviating liver fibrosis^[20,22]. Studies have shown that HGF is a powerful stimulant for liver cell growth and DNA synthesis^[23,24]. HGF can inhibit fibrosis, decrease the expression of collagen, and promote the degradation of extracellular matrix. In CCL₄ toxicity model, a significant rise in early HGF mRNA showed that CCL₄ caused liver cell damage at the same time. HGF is highly expressed for promoting liver regeneration and repairment^[25]. In this study, HGF expression level in group B was lower than that in group A ($P < 0.05$), suggesting that HGF expression decreased in the liver fibrosis tissue. HGF content of groups C and D increased ($P < 0.05$), showing that γ -interferon and matrine can raise the expression of HGF in liver tissue, so as to play a role in resisting liver fibrosis. The results confirmed that TGF- β 1 and HGF have antagonistic effect of cell factor. The results showed that HGF of group B was with low expression, but the expression of TGF- β 1 was high. Expression of TGF- β 1 and HGF in groups C and D were the opposite to that of group B. TGF- β 1 cytokines plays a very important role in fibrosis disease, so the antagonism of its biological effect is of great significance^[26].

Matrine can reduce TGF- β 1 expression and enhance the activity of HGF, so as to realize the inhibition effect on liver fibrosis in rats.

Conflict of interest statement

We declare that we have no conflict of interest.

Acknowledgments

This work was supported by the Science and Technology Projects of Technology Bureau of Taiyuan City (Grant No: 11016203).

References

- [1] Zhang F, Wang X, Tong L, Qiao H, Li X, You L, et al. Matrine attenuates endotoxin-induced acute liver injury after hepatic ischemia/reperfusion in rats. *Surg Today* 2011; **41**: 1075–1084.
- [2] Zhou L, Zhang GH, Gan P. Matrine pretreatment for prevention of liver ischemia reperfusion injury in rats. *Chin Modern General Surg* 2009; **12**: 557–601.
- [3] Liang JX, Qu XF, Ceng WD. Anti-liver fibrosis of oxymatrine in the treatment of chronic hepatitis. *J Southern Med Univ* 2010; **30**: 1871–1876.
- [4] Li DS. 45 cases clinical observation of matrine in treatment of liver fibrosis of patients with chronic hepatitis. *China MingKang Med* 2011; **23**: 2701–2704.
- [5] Tsochatzis EA, Germani G, Dhillon AP. Noninvasive assessment of liver fibrosis: the clinical context and question are important. *Hepatology* 2011; **54**: 2276–2280.
- [6] Poynard T, Munteanu M, Deckmyn O, Ngo Y, Drane F, Castille JM, et al. Validation of liver fibrosis biomarker (FibroTest) for assessing liver fibrosis progression: proof of concept and first application in a large population. *J Hepatol* 2012; **57**: 541–548.
- [7] Wei D. Combined effect of anluohuaxian pill and matrine on the liver fibrosis therapy. *J Jilin Med* 2013; **34**: 2874–2875.
- [8] Wang XD. Clinical observation of α -interferon combination matrine on treatment of chronic hepatitis. *Chin Foreign Med Care* 2012; **33**: 99–100.
- [9] Zheng ZF, Luo LF. The influence of marin on peripheral blood Th1/Th2 balance and liver fibrosis indexes of posthepatitic cirrhosis patients. *Med Taiwan Strait* 2102; **24**: 117–118.
- [10] Jemal A1, Bray F, Center MM, Ferlay J, Ward E, Forman D. Global cancer statistics. *CA Cancer J Clin* 2011; **61**: 69–90.
- [11] Marin JJ, Romero MR, Martinez-Becerra P. Overview of the molecular bases of resistance to chemotherapy in liver and gastroin-testinal tumours. *Curr Mol Med* 2009; **9**: 1108–1129.
- [12] Zhang GX. Significance and value of cellular immune function test on the diagnosis and treatment of hepatitis B. *Chin Foreign Health Abstr* 2011; **8**: 116–117.
- [13] Zhang CG. Curative effect of matrine combined with interferon on treatment of chronic hepatitis B. *J Modern Chin Med Appl* 2009; **3**: 85–87.
- [14] Fu JM, Zhang W. Curative effect observation of matrine combined α interferon for patients with chronic hepatitis B and the influence on liver fibrosis indexes and cellular immune state. *Chin J Hosp Infect* 2013; **23**: 1777–1779.
- [15] Ma YH. Clinical observation of matrine injection treatment of liver fibrosis in chronic hepatitis C. *J Practical Med China* 2013; **8**: 160–161.
- [16] Féher J, Lengyel G. Silymarin in the prevention and treatment of liver diseases and primary liver cancer. *Curr Pharm Biotechnol* 2012; **13**: 210–217.
- [17] Han Y, Zhang S, Wu J. Matrine induces apoptosis of human multiple myeloma cells via activation of the mitochondrial pathway. *Leuk Lymphoma* 2010; **51**: 1337–1346.
- [18] Zhang S, Qi J, Sun L. Matrine induces programmed cell death and regulates expression of relevant genes based on PCR array analysis in C6 glioma cells. *Mol Biol Rep* 2009; **36**: 791–799.
- [19] Zha Y, Chun YL, Huang YC. The influence of matrine on autophagy and apoptosis related gene expression of hepatocellular carcinoma cell line SMMC-7721. *World Chin Digest Mag* 2010; **18**: 3078–3083.
- [20] Guo D, Chen NN, Zhou P. Inhibition effect of matrine on Hep3B HCC cell growth and transcription activity of β -catenin. *J Chin Med Materials* 2010; **33**: 778–781.
- [21] Xia BM, Zhou HJ, Hu YL. Experimental study of oxymatrine in inhibiting endometrial cancer Ishikawa cells. *Prog Modern Obstet Gynecol* 2009; **18**: 278–281.
- [22] Fan Y, Wang SM, Shi QQ. The influence of matrine on proliferation and autophagy of liver cancer cell. *Contemp Chin Med* 2013; **20**: 11–12.
- [23] Meng LZ. The clinical research in synthetic method of traditional Chinese medicine treatment of chronic hepatitis B liver fibrosis. *J Asia-Pacific Trad Med* 2013; **9**: 87–88.
- [24] Ferraioli G, Tinelli C, Dal Bello B, Zicchetti M, Lissandrin R, Filice G, et al. Performance of liver stiffness measurements by transient elastography in chronic hepatitis. *World J Gastroenterol* 2013; **19**: 49–56.
- [25] Kumar R, Rastogi A, Sharma MK, Bhatia V, Tyagi P, Sharma P, et al. Liver stiffness measurements in patients with different stages of nonalcoholic fatty liver disease: diagnostic performance and clinicopathological correlation. *Dig Dis Sci* 2013; **58**: 265–274.
- [26] Hannivoort RA, Hernandez-Gea V, Friedman SL. Genomics and proteomics in liver fibrosis and cirrhosis. *Fibrogenesis Tissue Repair* 2012; **5**: 1–3.