



Contents lists available at ScienceDirect

Asian Pacific Journal of Tropical Medicine

journal homepage: www.elsevier.com/locate/apjtm

Document heading doi: 10.1016/S1995-7645(14)60060-2

Reinforcing effect of calcium sulfate cement bovine bone morphogenetic protein on vertebral in the rabbit model of osteoporosis

Jie Zhang¹, Chen Sheng-Guo^{2*}, Kaken. Habaerxi¹, Shawuti. Alimujiang¹, Yu Chen³, Ming-Zhen Peng¹, Rong Yue¹, Yu-Lian Wu¹, De-Quan Wang¹, Yu-Ming Chen¹

¹Xinjiang Autonomous Region People's Hospital, Urumqi, Xinjiang 830001, China

²Anatomy Section, Xinjiang Medical University, Urumqi, Xinjiang 830001, China

³Otolaryngology, Xinjiang Medical University, Urumqi, Xinjiang 830001, China

ARTICLE INFO

Article history:

Received 10 December 2013

Received in revised form 15 January 2014

Accepted 15 February 2014

Available online 20 May 2014

Keywords:

CSC

BBMP

Rabbit

Osteoporosis

Vertebral reinforcing

ABSTRACT

Objective: To observe reinforcing effect of calcium sulfate cement (CSC) bovine bone morphogenetic protein (bBMP) on vertebral in the rabbit model of osteoporosis. **Methods:** A total of 48 New Zealand white rabbits were randomly divided into group I (blank control group), group II (CSC injection group), group III (CSC/bBMP injection group) and control group. White rabbit osteoporosis model was established rapidly by using castration method+methylprednisolone candidate. After modeling, groups II, III were given corresponding vertebral body injection material, and 4 animals were sacrificed respectively at 24 h, 6 weeks, 12 weeks after vertebral plasty. Tissue pathological status, vertebral mineral density and vertebral body bone mechanical strength were observed. **Results:** Vertebral body structure form was normal in the groups II and III. Trabecular bone coarsens, connection and repair were observed in micro fracture and bone defects, bone trabecular connectivity was superior to group I significantly; vertebral body compression strength in the group I was on the decline, vertebral compression strength in the groups II and III was on the rise, the largest vertebra. Postoperative BMC and BMD in groups II and III were increased, and significantly higher than group I after 6 weeks ($P<0.05$), BMC and BMD in group III after 12 weeks were higher than the other three groups. **Conclusion:** Compound bBMP CSC has good bone induction. It can improve the three-dimensional construction effect for osteoporosis vertebral trabecula, and can significantly improve the vertebral strength, as a vertebral packing material with good application prospect.

1. Introduction

With the change of the living environment and diet, osteoporosis (OP) has become the main health problems of old people[1]. Vertebral compression fracture is common complication of OP. Vertebral plasty (VP) is commonly used in the treatment of vertebral compression fractures with curative effect, and has become an important approach to minimally invasive interventional treatment of the spine[3–5].

Packing material commonly used in VP is polymethyl methacrylate (PMMA). But the postoperative vertebral lesion has different strength from adjacent vertebral bodies, it will lead to adjacent vertebral fractures, it also has poor histocompatibility[6]. Because of its good biocompatibility, calcium sulfate cement (CSC) can be completely degraded in the body, with certain strength. It can promote the OP bone growth and renovation, and is widely used in bone defect filling[7]. Bovine bone morphogenetic protein (bBMP) is compound of cytokines, it can promote bone formation[8]. To observe the effect of CSC composite bBMP on OP vertebral strengthening effect, we used the castration method+methylprednisolone candidate to establish New Zealand white rabbit OP model, and observe reinforcing effect of CSC bovine bBMP on vertebral.

*Corresponding author: Chen Sheng-Guo, MD, Ph.D., Associate Professor, Anatomy Section, Xinjiang Medical University, Urumqi, Xinjiang 830001, China.

Tel: 15199171332

E-mail: zhangjt@163.com

Foundation project: It is supported by Scientific Research Project of People's Hospital number IN Xinjiang Uygur Autonomous Region (20130255)

2. Materials and methods

2.1. Experimental animal

A total of 60 healthy adult New Zealand white female rabbits were elected, aged 5 to 7 months, weighting 2.1–2.7 kg. They were provided by Experimental Animal Center of Xinjiang Medical University. Experiments were in accordance with Guidance on Treating Experimental Animals.

2.2. Instrument and reagent

S–3000N scanning electron microscope, HITACHI company (Japan); MTS 858 mini (System Inc Minneapolis, U.S.A.); Dual–energy X–ray absorptiometry bone mineral density instrument (Discovery Wi, Hologic Inc, Bedford MA, U.S.A.). Speed sleep new II number provided by the southwest pharmaceutical co., LTD.; Methylprednisolone (methyl prednisone Long Hupo acid sodium), CSC, CSC/bBMP reagents were purchased from Army Orthopaedic Institute.

2.3. Model establishment

A total of 48 New Zealand white rabbits were randomly divided into group I (blank control group), group II (CSC injection group), group III (CSC/bBMP injection group) and control group. OP model was established by castration method + methylprednisolone candidate. BMD was measured by dual–energy X–ray absorptiometry bone mineral density instrument 2 days before surgery. All animals were in fasting for 12 h, and group II was injected with 0.25 mg/kg anesthesia drug intramuscularly. Abdominal bilateral ovary was resected and fallopian tubes were ligated. Animals in control group only had bilateral ovaries resection. White rabbit were given antibiotics preoperative and postoperative to prevent infection. After wound healing, methylprednisolone 1 mg/kg·d was given for 4 weeks. Two months postoperatively, significantly decreased lumbar BMD, vertebral BMC and BMD showed successful modeling. All animals were under the same feed conditions of low calcium.

2.4. Methods

After modeling, rabbits in groups II, III were given CSC, CSC/bBMP injection within vertebral body. CSC and CSC/bBMP was packed separately to make preparation for different vertebral injection. After anesthesia, animals underwent midline incision at prone position, tissues were cut and separated. Junction between L2, L4, L6 pedicle and transverse was exposed, periosteal was stripped to expose

the bone marker. #12 needle was pierced into the vertebral body bone in 5–7 mm depth. After no breakthrough around the bone cortex was confirmed, 0.2 mL required material was injected to vertebral body till solidification. Without leakage, the needle was pulled out, and bleeding was stopped. Then layered suture was performed after washing the wound, and antibiotics was given after surgery postoperative to prevent infection.

2.5. Indexes observation

Four animals were sacrificed after the experiment after 6 weeks, L2 and L4, L6 vertebral body specimens were fixed in neutral formaldehyde and decalcified. All were soaked in plastic liquid after dehydration, tissues were embedded after 3 weeks. Tissues were cut along the horizontal section of vertebral body bone, sliced into 30 microns thickness specimen, to observe the bone trabecular microstructure morphology under light microscopy. Vertebral body bone structure mechanical strength was evaluated. L2, L4, L6 vertebral specimen was taken vertically in the MTS 858 mini System. Between the mold and axial, they were pressed gradually (5 mm/min), until a compression fracture bone occurred. According to the collect data the structure mechanical strength of the vertebral body bone was evaluated, and the mineral density of vertebral bones in groups was calculated.

2.6. Statistical analysis

Data were analyzed by t test using SPSS19.0 statistical software, and were expressed as mean±sd. $P < 0.05$ was considered as statistically significant difference.

3. Results

3.1. Histological observation of vertebral body

Normal trabecular bones form was the circular or elliptic arch structure in the control group. Mutual connection between the trabecular bones showed uniform degree of thickness, rare trabecular bone fracture or the defects. Compared with the control group, group I showed sparse vertebral body bone trabecular, decreased bone trabecular thickness, and bone defect after absorption of micro fractures and fracture forms. In group II trabecular bone structure showed apparent high density, a lot of blue new bone along the trabeculae, repaired connection at trabecular bone splits, with a complete ring of trabecular bone. Group III became coarsen, and showed apparent high density, a lot of new bone along the bone trabecular, and a lot of repair links were observed at bone trabecular splits, with a

complete ring of trabecular bone, indicating a better repair compared with group II (Figure 1).

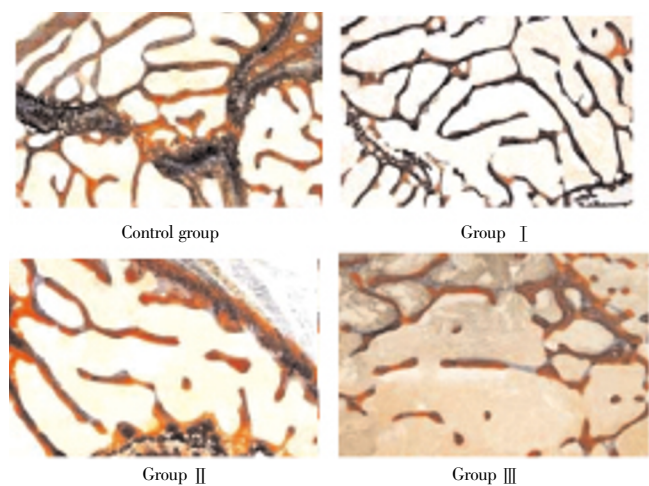


Figure 1. Histological observation of vertebral body (Ponceau trichrome staining, $\times 16$).

3.2. Structure mechanical strength of vertebral body bone

Bone trabecular connectivity was significantly superior to group I; vertebral body compression strength in the group I was decreased, vertebral compression strength in the groups II and III was increased. The largest vertebral compression strength after 12 weeks in group III was higher than that of group II ($P < 0.05$). Postoperative BMC and BMD in groups II and III were increased and significantly higher than group I after 6 weeks ($P < 0.05$), BMC and BMD in group III after 12 weeks were higher than the other three groups. There was no statistical difference at different time points in the control group with the biggest vertebral compression strength ($P > 0.05$). The biggest vertebral body compression strength in the group I was decreased, and in the groups II and III it was increased. Largest vertebral compression strength after 6 and 12 weeks in groups II and III was higher than that of group I, with significant differences between groups ($P < 0.05$), but was lower than that of control group ($P < 0.05$). There was no statistical difference between groups II and III with the highest vertebral compression strength at 6 weeks postoperatively ($P > 0.05$). But at 12 weeks postoperatively, group III showed significantly higher vertebral compression strength than that of group II ($P < 0.05$), (Table 1).

Table 2

Mineral content and density after VP at postoperative 6 and 12 weeks.

Groups	BMC (mg)		BMD(mg/cc)	
	6 weeks	12 weeks	6 weeks	12 weeks
Group I	0.10 \pm 0.04	0.09 \pm 0.03	37.21 \pm 16.10	36.52 \pm 15.70
Group II	0.18 \pm 0.05	0.42 \pm 0.09	76.12 \pm 13.81	171.70 \pm 30.82
Group III	0.32 \pm 0.07	0.48 \pm 0.17	119.21 \pm 23.92	186.21 \pm 61.70
Control group	0.41 \pm 0.04	0.42 \pm 0.05	160.11 \pm 15.24	167.20 \pm 18.91

Table 1

Structure mechanical strength of vertebral body bone at different time points.

Groups	24 h	6 weeks	12 weeks
Group I	6.80 \pm 2.18	6.38 \pm 2.52	5.33 \pm 2.15
Group II	7.11 \pm 2.42	9.29 \pm 2.17	12.03 \pm 1.41
Group III	6.91 \pm 2.15	9.57 \pm 1.41	12.47 \pm 2.49
Control group	14.52 \pm 4.48	14.92 \pm 3.50	15.00 \pm 4.08

3.3. Mineral content and mineral density after VP at postoperative 6 and 12 weeks

There was no significant change in BMC and BMD values in control group at each time point ($P > 0.05$); BMC and BMD were significantly lower in group I at 6 and 12 weeks after than that of groups II and III. BMC and BMD in groups II and III was increased, after 6 weeks postoperatively BMC and BMD were significantly higher than that of group I, but still significantly lower than control group ($P < 0.05$), at postoperative 12 weeks BMC and BMD group II was increased, but had no statistical difference compared with the control group ($P > 0.05$); BMC and BMD of group III after 12 weeks were significantly higher than the other three groups, with statistically significant differences ($P < 0.05$) (Table 2).

4. Discussion

OP is a common metabolic bone disease. As the aging and the change of the environment and diet, the incidence is increased year by year. Early treatment and prevention of fractures can significantly improve the OP patients' quality of life[8]. Suitable animal model is the foundation for research on OP treatment. Studies have showed that[9–15], white rabbit is main OP model of experimental animals due to its early bone mature, but with shortcomings such as long modeling time. This research adopts the castration method + methylprednisolone method for induction of OP model. After 2 months, the lumbar BMD and mechanical properties showed a significant reduction, indicating that castration method + methylprednisolone method can induce OP model quickly, modeling cycle became shorter than the pure castration method significantly.

Polymethyl methacrylate is only materials for clinical

VP filling, but there is a lot of side effects such as high leakage, hindrance to reconstruction of the bone due to lack of biodegradability. High hardness and strength also can easily cause secondary fractures to the adjacent vertebral body^[16–18]. Therefore, materials replacement of polymethyl methacrylate becomes a clinical problem. In this study, vertebral strength intensity of group I showed gradual decline, groups II and III using CSC, CSC/bBMP as VP filling materials shows that the vertebral strength increases gradually at postoperative 6 and 12 weeks, bone mineral content and density were significantly higher than that of group I. And vertebral strength of group III after 12 weeks intensity is significantly better than that of group II; in addition, compared with groups I, II the coarsen bone trabecular structure of group III has higher density. Along the bone trabecular a lot of new bones appeared, a lot of links, repair and a complete ring of trabecular bone appeared in bone trabecular splits and. It suggests that CSC composite bBMP as filling material of VP has better osteogenesis performance than that of pure CSC filling treatment.

Compound bBMP/CSC has good bone induction, with an improvement of the three-dimensional construction effect for OP vertebral trabecula. It can significantly improve the vertebral strength, as a vertebral packing material with good application prospect.

Conflict of interest statement

We declare that we have no conflict of interest.

References

- [1] Calori GM, Mazza E, Colombo M, Ripamonti C. The use of bone-graft substitutes in large bone defects: any specific needs? *Injury* 2011; **42**(S2): S56–63.
- [2] Thomas MV, Puleo D. Calcium sulfate: properties and clinical applications. *J Biomed Mater Res Part B: Appl Biomater* 2009; **88B**(3): 597–610.
- [3] Al-Ali F, Barrow T, Luke KB. Vertebroplasty; what is important and what is not. *Am J Neuroradiol* 2009; **30**(10): 1835–1839
- [4] Dumazer G, Narayan V, Smith A, Lemarchand A. Modeling gypsum crystallization on a submicrometric scale. *J Phys Chem C* 2009; **113**(4): 1189–1195.
- [5] Saha A, Lee J, Pancera SM, Brä̃eu MF, Kempter A, Tripathi A, et al. New Insights into the transformation of calcium sulfate hemihydrate to gypsum using time-resolved cryogenic transmission electron microscopy. *Langmuir* 2012; **28**(30): 11182–11187.
- [6] Levy H, Seydafkan S, Rice JD, Easley KA, Tangpricha V. Comparative efficacy of vertebroplasty, kyphoplasty, and medical therapy for vertebral fractures on survival and prevention of recurrent fractures. *Endocr Pract* 2012; **18**(4): 499–507.
- [7] Lemarchand A, Boudoire F, Boucard E. Plaster hydration at different plaster-to-water ratios: acoustic emission and 3-dimensional submicrometric simulations. *J Phys Chem C* 2012; **116**(7): 4671–4678.
- [8] Kang SK, Lee CW, Park NK, Kang TW, Lim JW, Cha KY, et al. Predictive risk factors for refracture after percutaneous vertebroplasty. *Ann Rehabil Med* 2011; **35**(6): 844–851.
- [9] Fisher RD, Mbogoro MM, Snowden ME, Joseph MB, Covington JA, Unwin PR, et al. Dissolution kinetics of polycrystalline calcium sulfate-based materials: influence of chemical modification. *ACS Appl Mater Interfaces* 2011; **3**(9): 3528–3537.
- [10] Li YA, Lin CL, Chang MC, Liu CL, Chen TH, Lai SC. Subsequent vertebral fracture after vertebroplasty; incidence and analysis of risk factors. *Spine* 2011. [Epub ahead of print].
- [11] Mbogoro MM, Snowden ME, Edwards MA, Peruffo M, Unwin PR. Intrinsic kinetics of gypsum and calcium sulfate anhydrite dissolution: surface selective studies under hydrodynamic control and the effect of additives. *J Phys Chem C* 2011; **115**(20): 10147–10154.
- [12] Yen CH, Teng MM, Yuan WH, Sun YC, Chang CY. Preventive vertebroplasty for adjacent vertebral bodies; a good solution to reduce adjacent vertebral fracture after percutaneous vertebroplasty. *Am J Neuroradiol* 2012; **33**(5): 826–832.
- [13] Massaro FR, Rubbo M, Aquilano D. Theoretical equilibrium morphology of gypsum ($\text{CaSO}_4 \cdot 2\text{H}_2\text{O}$). 1. A syncretic strategy to calculate the morphology of crystals. *Cryst. Growth Des* 2010; **10**(7): 2870–2878.
- [14] Chen LH, Hsieh MK, Liao JC. Repeated percutaneous vertebroplasty for refracture of cemented vertebrae. *Arch Orthop Trauma Surg* 2011; **131**(7): 927–933.
- [15] Massaro FR, Rubbo M, Aquilano D. Theoretical equilibrium morphology of gypsum ($\text{CaSO}_4 \cdot 2\text{H}_2\text{O}$). 2. The stepped faces of the main [001] zone. *Cryst Growth Des* 2011; **11**(5): 1607–1614.
- [16] Lin WC, Lu CH, Chen HL, Lai PL, Niu CC, Fu TS, et al. The impact of preoperative magnetic resonance images on outcome of cemented vertebrae. *Eur Spine J* 2010; **19**(11): 1899–1906.
- [17] Rubbo M, Bruno M, Massaro FR, Aquilano D. The five twin laws of gypsum ($\text{CaSO}_4 \cdot 2\text{H}_2\text{O}$): A theoretical comparison of the interfaces of the penetration twins. *Cryst Growth Des* 2012; **12**(6): 3018–3024.
- [18] Woo KM, Yu B, Jung HM, Lee YK. Comparative evaluation of different crystal-structured calcium sulfate as bone-filling materials. *J Biomed Mater Res B Appl Biomater* 2009; **91B**(2): 545–554.