

Contents lists available at [ScienceDirect](http://www.sciencedirect.com)

Asian Pacific Journal of Tropical Medicine

journal homepage: www.elsevier.com/locate/apjtm

Document heading doi:

Primary hepatic tuberculosis: A rare but fatal clinical entity if undiagnosed

Singh Sneh, Jain Promil, Aggarwal Garima*, Dhiman Pratibha, Singh Sunita, Sen Rajeev

Department of pathology, Pt. B.D. Sharma PGIMS, Rohtak India

ARTICLE INFO

Article history:

Received 10 November 2011

Received in revised form 15 January 2012

Accepted 15 March 2012

Available online 20 June 2012

Keywords:

Hepatic tuberculosis

Diagnosis

Treatment

ABSTRACT

Hepatic tuberculosis particularly in the absence of military tuberculosis is rare. It can occur as a primary case or due to reactivation of an old tubercular focus. We report case of a 24 year old married female who died of primary hepatic tuberculosis. She had no evidence of tuberculosis elsewhere. Appropriate treatment initiated early can result in marked recovery whereas failure to recognize this entity can prove to be fatal.

1. Introduction

Hepatic tuberculosis particularly in the absence of military tuberculosis is rare^[1]. It can occur as a primary case or due to reactivation of an old tubercular focus. Primary hepatic tuberculosis result from tubercular bacilli gaining access to portal vein from a microscopic tubercular focus in the bowel with subsequent healing taking place at the site of entry leaving no trace of it.

Clinically, hepatic tuberculosis can present as fever of unknown origin, loss of weight, lassitude, abdominal pain and jaundice which if not timely diagnosed and properly managed can culminate in fulminant hepatic failure that may prove fatal^[2].

2. Case report

We present the case of a 24 year old married female who was admitted with complains of low grade fever, loss of weight and appetite along with mild jaundice for the past two months, acute onset dyspnea, vomiting, altered sensorium and irritability since one day. Treatment details were not available. On examination she was comatose, with pallor, icterus and grade 4 hepatic encephalopathy

with liver span of 12 cm, no splenomegaly or free fluid. She had bilateral chest crepitations and grossly malnourished. Clinical diagnoses of ARDS with septicemia and tuberculosis was made. She was put on ventilator support in ICU and supportive care provided. The relevant haematological investigations included ESR: 48 mm in 1st hour (Westergren's method), total leucocyte count: $11,800 \times 10^9/L$, Alkaline phosphatase: 300 U/L and HIV was non reactive. The CXR did not show any opacities and on ultrasonography the liver revealed three hypoechoic lesions the largest measuring (4.5×2.8) cm, other abdominal viscera was normal and there was no free fluid seen. A liver biopsy was planned to rule out malignancy, but the patient died before it could be performed. Partial autopsy was conducted after due consent and her viscera (brain, heart, lungs, liver, spleen, kidneys and intestines) were sent to the Department of Pathology for histopathological examination and forensic laboratory for chemical analysis.

Representative microsections from the liver revealed multiple confluent necrotizing epithelioid cell granulomas along with mononuclear inflammatory cell infiltrate in the adjacent areas. Staining for AFB with 20% sulphuric acid was positive. Liver histopathology was suggestive of hepatic tuberculosis. Representative microsections examined from the lungs, spleen, kidneys and gut showed mild congestion, the brain showed congestion along with edema whereas the heart was unremarkable. The chemical analysis report from forensic laboratory was negative, so the cause of death was primary hepatic tuberculosis.

*Corresponding author: Dr. Garima Aggarwal, H. No. 107, Bank Enclave, Luxmi Nagar New Delhi, 110092 India.

Tel: +91-9812148657

E-mail: drgimuaggarwal@gmail.com

3. Discussion

Liver histology in an individual indigenous to a tropical country differs from those who live in temperate regions of the world^[3]. This organ is subjected to numerous systemic infections as it lies at the distal end of portal circulation. The liver is a common site for granuloma formation because of its rich blood supply and large number of reticuloendothelial cells. They represent a complex interplay between the presenting antigen and the host immune response. These granulomas are usually located near the portal tract and there is only mild perturbation of hepatic function, so most patients are minimally symptomatic or asymptomatic.

Hepatic tuberculosis is one of the sub-types of abdominal tuberculosis. Granulomas are found in liver biopsy specimens in 25% of persons with pulmonary tuberculosis and 80% of those with extra pulmonary tuberculosis^[4]. Coexistence of HIV and HBV with mycobacterium tuberculosis should not be underestimated^[5] and evidence of HIV infection or other immunodeficiency states should be actively searched for. Hepatic tuberculosis can be classified as miliary TB, pulmonary TB with hepatic compromise, primary hepatic TB, focal or abscess tuberculosis and tuberculous cholangitis^[6]. The most common form of hepatic involvement is miliary TB due to hematogenous spread via hepatic artery. Primary hepatic tuberculosis is rare because low oxygen tension in the liver is unfavorable for growth of mycobacteria.

The clinical presentation is not specific and a high degree of clinical suspicion is required to diagnose this entity which can be medically managed easily but if not treated can lead to hepatic failure and ultimately death. Abdominal pain, fever and weight loss are common clinical complaints. Hepatomegaly may be found with an increase in alkaline phosphatase and normal transaminase levels. Acute liver failure in the early stages is not associated with objective signs, but with severe dysfunction there is onset of jaundice along with neurological signs such as sleep disturbance, liver flap, drowsiness, confusion and eventually coma.

Criteria for diagnosis of primary hepatic tuberculosis include recent evidence of tubercular infection, demonstration of necrotising granulomatous inflammation in liver and absence of old tubercular lesions elsewhere^[7]. The investigations of choice are liver biopsy and culture along with clinical and radiological exclusion of extrahepatic disease.

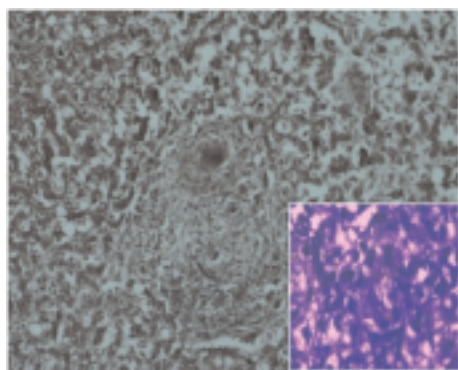


Figure 1. Low power view of granuloma in liver(100x); inset- ZN stain positive bacilli (1 000x).

Hepatic failure especially of the fulminant type with duration of less than seven days is of forensic medical relevance^[8]. Important causes are viral hepatitis (65%)

and hepatotoxic substances such as medications and poisons. This elucidates the importance of accompanying toxicological analysis. Potentially fatal complications are brain edema, gastrointestinal hemorrhages, as well as hypoglycemia and renal failure with electrolyte imbalances^[9]. The typical enzymes of liver metabolism as well as bilirubin levels represent important parameters and can be examined post mortem¹⁰. In this case all these chemical and biochemical parameters tested negative and on this basis the cause of hepatic coma was presumed to be hepatic tuberculosis.

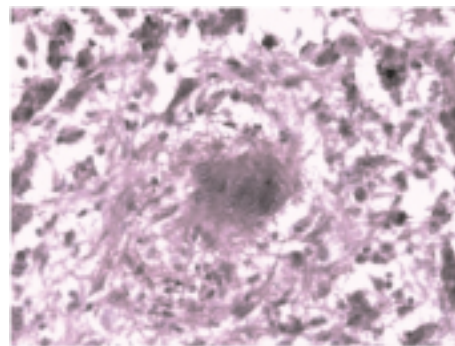


Figure 2. High power view of granuloma (400x).

Isolated hepatic tuberculosis, although uncommon should be included in the differential diagnoses of patients presenting with upper abdominal pain, fever and jaundice with hepatomegaly especially in areas endemic for tuberculosis. Appropriate treatment initiated early can result in marked recovery whereas failure to recognize this entity can prove to be fatal.

References

- [1] Brookes MJ, Field M, Dawkins DM, Gearty J, Wilson P. Massive primary hepatic tuberculoma mimicking hepatocellular carcinoma in an immunocompetent. *Med Gen Med* 2006; **8**(3):11.
- [2] Mert A, Ozaras R, Tabak F, Ozturk R, Bilir M. Localized hepatic tuberculosis. *Eur J Intern Med* 2003; **14**: 511–512.
- [3] Reynolds TB, Campra JL, Peters RL. Granulomatous liver diseases. In: Zakim D, Boyer TD. (eds). *Hepatology: A textbook of liver diseases*. 3rd ed. Philadelphia: WB Saunders; 1996. p. 1472–89.
- [4] Hoffman CJ, Thio CL. Clinical implications of HIV and hepatitis B coinfection in Asia and Africa. *Lancet Infect Dis* 2007; **7**: 402–409.
- [5] Levine C. Primary macronodular hepatic tuberculosis: US and CT appearances. *Gastro intestinal Radiol* 1990; **15**: 307–309.
- [6] Chien RN, Lin PY, Liaw YF. Hepatic tuberculosis: Comparison of military and local form. *Infection* 1995; **23**: 5–8.
- [7] Loja OD, Vilca VM, Alveraz BP. Granulomatous tubercular hepatitis as a cause of fever of unknown origin. *Rev Gastroenterol* 2002; **22**: 324–329.
- [8] Kernbach-Wighton G. The diagnosis of functional causes of death. In: Madea B. (ed). *Practice of legal medicine*. Berlin, Heidelberg, New York, Tokyo: Springer; 2003; p. 239–244.
- [9] Kernbach G, Brinkmann B. Postmortem patho-biochemistry used for the diagnosis of fatal diabetic coma as a cause of death. *Pathology* 1983; **4**: 235–240.
- [10] Madea B, Musshoff F. Postmortem biochemistry. *Forensic Sci Int* 2007; **165**: 165–171.