



Contents lists available at ScienceDirect

Asian Pacific Journal of Tropical Medicine

journal homepage: www.elsevier.com/locate/apjtm



Document heading doi:

Primary human hepatocyte transplantation in the therapy of hepatic failure: 2 cases report

Zhuo-Ri Li^{1#*}, Xian-Hai Mao^{2#}, Xiao-Xuan Hu³, Sheng-Dan Nie³, Yong-Zhong Shi⁴, Hua Xiang⁵, Jian-Hui Yang², Ou-De Cao⁴

¹Department of Hepatobiliary Surgery, Hainan Provincial People's Hospital, Haikou 570311, Hainan, China

²Department of Hepatobiliary Surgery, Hunan Provincial People's Hospital, Changsha 410005, Hunan, China

³Department of Internal Medicine of Hepatopathy, Hunan Provincial People's Hospital, Changsha 410005, Hunan, China

⁴Clinical Research Institute, Hunan Provincial People's Hospital, Changsha 410005, Hunan, China

⁵Minimally Invasive and Interventional Center, Hunan Provincial People's Hospital, Changsha 410005, Hunan, China

ARTICLE INFO

Article history:

Received 3 November 2011

Received in revised form 15 November 2011

Accepted 15 December 2011

Available online 20 February 2012

Keywords:

Cell transplantation

Hepatocyte

Liver failure

ABSTRACT

Liver failure is the end stage of hepatopathy with unfavorable prognosis. In two patients with liver failure, viable primary human hepatocytes, obtained from resected liver tissue of patients with hepatolithiasis, were transplanted into the spleen by interventional therapy through femoral arterial cannula. After transplantation, the patients' clinical symptoms and liver function were significantly improved. However, their bilirubin increased within six days following transplantation. One suffered from hepatic coma and give up treatment and the other patient died fourteen days after transplantation. It is technically safe to treat liver failure by intrasplenic transplantation of adult hepatocytes and the clinical efficacy has been confirmed. How to make transplanted hepatic cells proliferate and functionally survive is the key point to maintain continuous improvement of the recipient's hepatic function.

1. Introduction

Liver failure is the end stage of hepatopathy with unfavorable prognosis. Liver transplantation is considered as the most effective therapy for liver failure^[1,2]. However, due to donor liver shortages, immunological rejection, difficulties in preserving donor liver, it is difficult to perform liver transplantation on a large scale. As an effective transitional and alternative therapy, hepatocyte transplantation is increasingly attracting much attention for it is simpler, effective and has less impact on recipients^[3,4]. Hopefully, it will become another practical therapy for hepatic failure after liver transplantation. Nevertheless, searching for suitable hepatocyte sources is one of the keys to clinical hepatocyte transplantation^[5–10]. We treated two patients with liver failure by hepatocyte transplantation in January and February, 2009 respectively and achieved preliminary results. The transplanted hepatocytes were

obtained from human allergenic hepatic lobes with benign lesions and then were transplanted intrasplenically by interventional therapy.

2. Case report

2.1. Case 1

Male, 35 years of age, blood type B, was hospitalized because of having suffered from hepatitis B for 6 years and generalized jaundice for 3 months. Physical examination at the time of admission: BP 120/70mmHg, conscious, serious icteric skin and sclerae, abdominal distention and hydroperitoneum. Total bilirubin (TBIL) 463.13 μ mol/L, indirect bilirubin 160.93 μ mol/L, alanine aminotransferase (ALT) 69 U/L, aspartate aminotransferase (AST) 118 U/L, K^+ 4.38 mmol/L, Na^+ 130.7 mmol/L, Cl^- 86.1 mmol/L, prothrombin time (PT) 67.3 s, prothrombin activity (PTA) 12.9%, thrombin time (TT) 30.0 s, HBsAg, HBeAb and HBcAb (+), HBV DNA (-), normal AFP, hyaluronic acid (HA) >800 μ g/L. He underwent adult hepatocyte allotransplantation on January 6, 2009. The preparation and process of hepatocyte allotransplantation were listed as follows.

*Corresponding author: Zhuo-Ri Li, M.D., Department of Hepatobiliary Surgery, Hainan Provincial People's Hospital, Haikou 570311, Hainan, China.

Tel: 86-898-68622452

Fax: 86-898-68622456

E-mail: ri2010sun@yahoo.cn

#: These authors contributed equally to this work.

The sources of donor liver were diseased liver lobes acquired from patients who suffered from hepatolithiasis. The biopsy showed that there were no obvious cholangitis and fibrosis in the liver lobes. The protocol for the present study was approved by the regional committee of medical ethics. Informed consent was obtained from all participants. The surgically resected liver tissue was weighed. The hypothermic perfusion/infusion via the hepatic artery and the portal vein was carried out at 4 °C using University of Wisconsin (UW) solution until the color of the liver tissue turned white (Figure 1). Afterwards, the hepatic artery and the portal vein were completely perfused and rinsed using calcium-free and magnesium-free solution /infusion I for 10 min at 37 °C so as to remove the UW solution remaining inside the liver tissue. Then, the liver tissue was fully digested using solution II containing 0.1% collagenase P at 37 °C for 20 to 30 min until the liver surface turned rhagadiform. The digestion was ended using solution III (D2Hanks) at 4 °C followed by opening the hepatic capsula with scissors (Figure 2). Cell filtration was performed using a screen of 60-mesh sieve and a screen of 120-mesh sieve, followed by cell centrifugation at 50 g/min for 5 min and for 3 times at 4 °C, and finally, the hepatocytes were resuspended in nutrient fluid. The hepatocyte purity examination by an immunocytochemistry test revealed that the purity was up to 95%. The hepatocellular quantity and viability were tested by trypan blue exclusion method (Figure 3). The number of transplanted hepatocytes in case 1 was 2.7×10^8 , their viability was 92%.

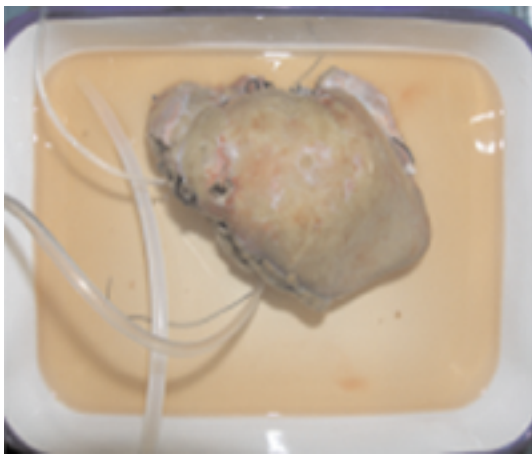


Figure 1. The hepatic lobe after UW perfusion.

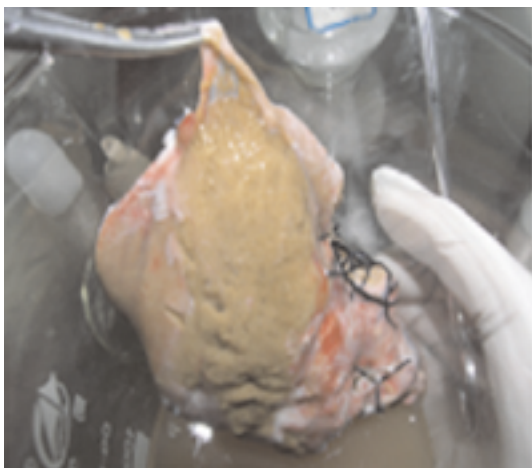


Figure 2. Rather lossely organized hepatocytes after collagenase

digestion treatment.




Figure 3. The cultured hepatocytes.

The donors underwent femoral artery catheterization for super-selective splenic arterial perfusion/ infusion transplantation. The end of the inserted catheter passed through pancreatic, gastric and colonic ramifications of splenic artery (Figure 4) in order to ensure that the transplanted hepatocytes were planted inside the donor's splenic pulp and would not affect blood supply of other organs. The hepatocyte suspension was infused at 150 mL/h via a syringe pump. The methylprednisolone was employed to avoid acute allograft rejection. Blood routine tests and routine tests of liver function, PT/PTA, cholinesterase, IgA, IgG, IgM, C3 and C4 were performed 1 day before the transplantation, and 1 day, 7 days, 2 weeks and 4 weeks post-transplantation.

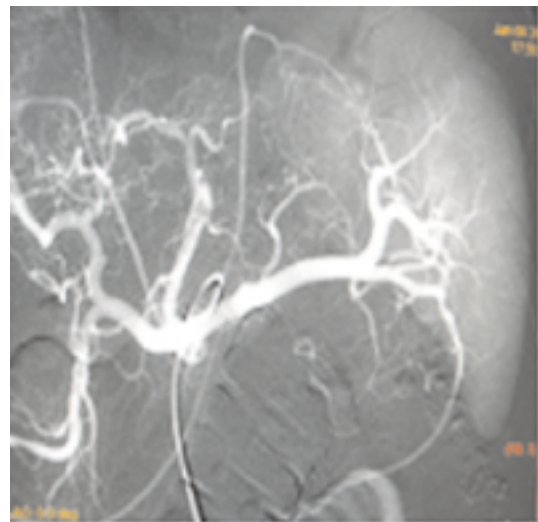


Figure 4. Intrasplenic transplantation of hepatocytes via interventional therapy.

The operation was successful. He had improvement in hypodynamia, poor appetite and abdominal distention. TBIL was 404 μ mol/L one day after the transplantation, PTA and cholinesterase increased compared to pre-transplantation, and there was no significant difference between blood

levels of IgA, IgG, IgM and C3 and C4 prior to and following transplantation. On the 6th day after the transplantation, TBIL had increased to 471 $\mu\text{mol/L}$. The patient became restless and disoriented with progressive increases in blood/arterial/serum ammonia levels and icteric index. Consequently, he decided to give up the treatment and left the hospital.

2.2. Case 2

Male, 28 years of age, blood type A, was hospitalized after presenting with generalized jaundice for one week. TBIL 319 $\mu\text{mol/L}$, direct bilirubin 205 $\mu\text{mol/L}$, albumin 33.68 g/L, ALT 611 U/L. His coagulation function couldn't be tested on the second day after admission and he was diagnosed with severe hepatitis and acute liver failure, and was treated with therapies such as liver protection, diurese and immunomodulation. On the third day after admission his TBIL continuously increased and blood/arterial/serum ammonia level increased. He exhibited clinical manifestation of hepatic encephalopathy such as obtundation along with ascites, splenomegaly and decompensated hepatocirrhosis. The patient underwent hepatocyte transplantation 7 days after admission. The process of hepatocyte allotransplantation was the same to the Case 1. The number of transplanted hepatocytes in case 2 was 7.5×10^8 , and their viability was 93%. Prednisone and freeze-dried human serum albumin were administered to him after the transplantation. On the 3rd day after transplantation, he had improvement in icteric index and other indexes such as coagulation function. TBIL dropped from 489 $\mu\text{mol/L}$ to 445 $\mu\text{mol/L}$, and the coagulation function indexes returned to normal. There was no significant difference between blood levels of IgA, IgG, IgM and C3 and C4 before and after transplantation. However, his TBIL was up to 629 $\mu\text{mol/L}$ one week after the transplantation, and he complained of abdominal distending pain on the 11th day. Abdominal X-ray plane film indicated that he had an incomplete obstruction of small intestine and died of liver failure on the 14th day after the transplantation. No postmortem examination/autopsy was made after the death.

3. Discussion

The difficulty in treating hepatic failure is very considerable and its mortality is high. Hepatocyte transplantation is a cell engineering technology that has been developed since the 1970's^[5,6]. It has therapeutic effects on acute and chronic hepatic failure and is an effective way for the patients who are awaiting donor liver sources and in transition to orthotopic liver transplantation^[5–10]. The technology involves the following steps: first, catheterization & perfusion/infusion, isolation, purification and culture

of the donor's liver tissue are carried out in situ; then the viable hepatocytes with normal cellular function are injected into the recipient aiming at partial recovery of the recipient's hepatic secretory and metabolic function and so on. The spleen is the optimal site for hepatocyte transplantation as it is large in size, and can hold sufficient amounts of hepatocytes, and intrasplenic reticular tissue is able to capture phagocytes and prevent the transplanted hepatocytes from being phagocytized by phagocytes^[7,8]. In addition, rich blood supply in the spleen offers favorable conditions for the hepatocytes' long-term survival and proliferation. A great number of hepatocytes became degenerative, necrotic and with reversion differentiation/division in the early stage following hepatocyte transplantation. However, hepatocytes basically recovered in three months. Hepatic lobules-like architectures were formed in 5 months, and in about 1 year, the hepatocytes could line up as paved bricks or ropes along with solid reticular fibers in which there were glandular tubular architectures appearing, covered with bile capillaries of short columnar epithelium.

It is a significantly important research project to search for suitable hepatocytes for transplantation nowadays. Although heterogenic hepatocytes like swine hepatocytes are a rich source, there are risks of zoonoses and relatively serious immunological rejection if they are applied for hepatocyte transplantation in humans; immortalized hepatocytes have unlimited proliferation ability, but their carcinogenic risk limits their clinical application to a certain degree. Adult hepatic stem cells (oogonia/hepatic stem cells) are capable of differentiating into mature hepatic cells, but, currently there are no effective methods available for identifying and culturing this type of cells. For human fetal hepatocytes and hepatic stem cells, social ethics restricts their application, although some people have transplanted them into human bodies. Further research is required to evaluate their efficacy for transplantation. Nowadays, primary human hepatocytes are the most suitable cells to approach/meet requirements for clinical application^[9]. However, they are unable to proliferate in large quantities and be applied in emergencies due to source shortages.

There have been no reports available in the literature about using primary human hepatocytes from liver tissue obtained by hepatectomy on patients with benign hepatic lesions for hepatocyte transplantation. In this study, the viable primary human hepatocytes obtained from the hepatic lobes surgically resected from the two patients with hepatolithiasis were intrasplenically transplanted via interventional therapy, which expanded hepatocellular sources. If adequate amounts of viable adult hepatocytes can be gained from surgically resected liver tissue with benign lesions, shortages of hepatocyte sources will be radically improved. Further, fewer issues regarding ethics, medical risks and so on are involved in this practice. To ensure that adequate amounts of hepatocytes of high purity and good viability could be isolated and acquired, we modified methods of

hepatectomy and hepatocyte isolation in the study. We performed left liver lobectomy by adopting highly selective regional vascular clamping in which the hepatic artery of the left lobe of liver, the branches of the portal vein and left hepatic vein were isolated and retained at first, and then the preparatory catheterization was done, the cutting surface of left hepatic lobe was separated and cut by clamping technique, the vascular branches on both sides of the hepatic cutting surface were ligated, and the biliary duct on the cutting surface of the left hepatic lobe was closed by ligation. Shortly afterwards, the surgically resected liver tissue underwent hypothermic perfusion/infusion via the hepatic artery and the portal vein at 4°C using UW solution until the color of the liver tissue turned white. We changed conventional two-step isolation technique of hepatocytes into a three-step collagenase isolation technique of hepatocytes. Preventive antibiotics were administered to the donors, and samples of the bile was obtained for bacterial culture during transplantation, the common bile duct was not opened when liver resection was performed, which aimed to greatly reduce the warm ischemia time of the donor liver tissue, prevent intrahepatic bile from contaminating the hepatocytes and make their effective acquisition rate, purity and viability meet requirements for hepatocyte transplantation.

After the acquired hepatocytes were transplanted in the spleen via splenic artery, and the state of illness of the two recipients took a favorable turn to a certain degree, their hepatic function improved. Neither of the two patients suffered from bleeding, splenic infarctions or infarctions of extrasplenic organs, and they didn't suffer from infection and other complications from the procedure. There was no increase in IgA, IgG, IgM and C3 and C4 which indicated that no obvious allograft rejection was provoked in the recipient bodies after hepatocyte transplantation. Limited observation showed that it is technically feasible and of some clinical efficacy to acquire viable primary human hepatocytes from surgically resected liver tissue with benign lesions and to transplant them intrasplenically. The transplanted hepatocytes may provide the recipients with support in terms of liver function, and therefore, bridging the time between the recipient's native liver regeneration and hepatic transplantation.

The reasons that the recipients' serum bilirubin level rose to some extent one week after transplantation were probably related to: 1) The transplanted number of hepatocytes was much lower than the theoretical effective amount, 10^9 , and as a result, the hepatocytes' functional compensation after transplantation was not completed, and therefore, it is difficult to radically reverse the recipients' status of hepatic failure; 2) Although the transplanted hepatocytes could partially serve as a substitute for the

recipients' liver function in a short period of time and improved it to a certain degree, the number of viable and functional hepatocytes were reduced and more transplanted hepatocytes became apoptotic as time went by; 3) Further studies are required on whether there is immunological rejection or not, and to what degree. Therefore, in terms of maintaining and constantly improving the recipients' liver function, it is vital importance to seek methods to make transplanted hepatocytes proliferate and become less apoptotic and how to establish hepatocyte banks of a variety of donor hepatocyte sources with the intention of providing adequate amounts of functional primary human hepatocytes from multiple donors for a single recipient.

Conflict of interest statement

We declare that we have no conflict of interest.

References

- [1] Alqahtani SA, Larson AM. Adult liver transplantation in the USA. *Curr Opin Gastroenterol* 2011; **27**(3): 240–247.
- [2] Merion RM. Current status and future of liver transplantation. *Semin Liver Dis* 2010; **30**(4): 411–421.
- [3] Dhawan A, Strom SC, Sokal E, Fox IJ. Human hepatocyte transplantation. *Methods Mol Biol* 2010; **640**: 525–534.
- [4] Dhawan A, Puppi J, Hughes RD, Mitry RR. Human hepatocyte transplantation: current experience and future challenges. *Nat Rev Gastroenterol Hepatol* 2010; **7**(5): 288–298.
- [5] Huang P, He Z, Ji S, Sun H, Xiang D, Liu C, et al. Induction of functional hepatocyte-like cells from mouse fibroblasts by defined factors. *Nature* 2011; **475**(7356): 386–389.
- [6] Puppi J, Strom SC, Hughes RD, Bansal S, Castell JV, Dagher I, et al. Improving the techniques for human hepatocyte transplantation: Report from a consensus meeting in London. *Cell Transplant* 2011. [Epub ahead of print].
- [7] Tsuruga Y, Kiyono T, Matsushita M, Takahashi T, Kasai N, Matsumoto S, et al. Effect of intrasplenic transplantation of immortalized human hepatocytes in the treatment of acetaminophen-induced acute liver failure SCID mice. *Transplant Proc* 2008; **40**(2): 617–619.
- [8] Ahmad TA. Study of the survival of hepatocytes transplanted to the spleen in rats. *Hepato-gastroenterology* 2011; **58**(107–108): 892–895.
- [9] Dhawan A, Puppi J, Hughes RD, Mitry RR. Human hepatocyte transplantation: current experience and future challenges. *Nat Rev Gastroenterol Hepatol* 2010; **7**(5): 288–298.
- [10] Li ZR, Wu YF, Lu XS. Development in clinical study on hepatocyte transplantation. *Chinese J General Surg* 2009; **7**(18): 756–759.