

Contents lists available at [ScienceDirect](http://www.sciencedirect.com)

Asian Pacific Journal of Tropical Medicine

journal homepage: www.elsevier.com/locate/apjtm

Document heading doi:

The role of endotoxin in the pathogenesis of gastric mucosal damage in cirrhotic rats with portal hypertensive gastropathy

Cheng Lan*, Xiaoning Sun, Liwei Dong, Baili Huang, Su Yuan, Keli Wu

Hainan Provincial People's Hospital, Haikou 570311, China

ARTICLE INFO

Article history:

Received 29 November 2010

Received in revised form 27 December 2010

Accepted 15 January 2011

Available online 20 March 2011

Keywords:

Endotoxin

Cirrhosis

Portal vein hypertension gastropathy

TNF- α

ABSTRACT

Objective: To study the role and the mechanism of endotoxin in the pathogenesis of gastric mucosa during portal vein hypertension gastrography (PHG) in the rats with cirrhosis. **Methods:** Rat model for PHG was established by injection of tetrachloride. The animals were injected with endotoxin i.p. at 3 mg/kg and endotoxin antagonist BPI21 i.v. at 2.0 mg/kg. The plasma level of endotoxin as well as the gastric mucosal level of tumor necrosis factor alpha (TNF- α) was measured with azobenzene and ELISA respectively. Furthermore, the pathological changes of the gastric mucosa were studied with HE staining. **Results:** In rats with PHG, increased endotoxin and TNF- α as well as the gastric pathological lesion were observed. Injection of endotoxin remarkably increased plasma level of endotoxin as well as the gastric mucosal level of tumor necrosis TNF- α and induced more serious gastric lesion. Animals injected with endotoxin antagonist BPI21 showed improved gastric mucosal lesion, accompanied by the declining TNF- α level. **Conclusions:** Our results suggests that endotoxin may play a pathogenetic role in PHG by inducing the expression of TNF- α .

1. Introduction

It is observed that gastric mucosal injure is involved in the upper digestive tract bleeding in the patients with liver cirrhosis and portal hypertension. This kind of gastric mucosal injure is called portal hypertension gastropathy (PHG)[1]. The pathogenesis of PHG includes the impaired protective function of gastric mucosa except for portal hypertension. As it is observed that the permeability of the intestinal barrier increases and toxic substances from the intestine are spread in the liver during PHG, It is presumed that in PHG, the endotoxin from the intestine could induce a lot of factors to destroy the gastric mucosal barrier[2]. But the hypothesis is still short of enough experimental evidence. The current research is to study the presumed role of endotoxin in the gastric mucosal injure during PHG.

2. Materials and methods

Forty male Wistar rats purchased from an experimental animal center (Chongqing University of Medical Science,

China), weighing about 200–250 g, were randomly assigned into four groups: the normal control group (Group A), PHG model group (Group B), PHG model+endotoxin group (Group C), PHG model+BPI21 group (Group D).

2.1. Main reagents

Escherichia coli were from Staff Room of Microbiology, Second Military Medical University, Shanghai, China. Recombinant bactericidal/permeability increasing protein BPI21 was purchased from XOMA Corporation, U.S.A. ELISA kits for tumor necrosis factor alpha (TNF- α) of rats were purchased from Jingmei Biotec. Limited Corporation, Shengzhen, China.

2.2. Modeling of liver cirrhosis and PHG

The rats were feed in a standard laboratory for one week before modeling.

The animals were injected subcutaneously with 60% tetrachloride in vegetable oil (0.3 mL/100 g weight) every 3–4 days. About 12 weeks later, the rat model for liver cirrhosis was successfully established. One week later, the animals were anesthetized with Ketamine at 40mg/kg i.p. The abdomen was excided and the trunk of the portal vein was isolated, which was punctured with trocar No.26. Subsequently, a pipe was linked with portal vein and the

*Corresponding author: Professor Cheng Lan, Department of Gastroenterology, Hainan Provincial Hospital, Hainan Medical University, Haikou, China(570311).

E-mail: lancheng71@hotmail.com

Foundation project: Supported by Natural Science Foundation of Hainan Province Grant (No. 80599)

portal vein pressure was measured.

2.3. Injection of endotoxin and BPI21

The rats in Group C were injected i.p. with lipopolysaccharides (LPS) at 3 mg/kg in the 4th, 6th, 8th week during establishment of PHG model. Meanwhile, animals in Group D were injected by tail vein with BPI21 at 2.0 mg/kg.

2.4. Determination of plasma endotoxin and TNF- α

Endotoxin and TNF- α levels in gastric tissue or plasma were measured according to manufacturer's instructions of the kits (Endotoxin Kit from Yihua Biotech Corp, Shanghai and rat TNF- α ELISA Kit from Jinmei Biotech Corp, Shanghai, No.FRK0003). To detect the levels of TNF- α protein, gastric tissue samples were homogenized in ice-cold physiological saline, smashed by ultrasonic, then centrifuged at 3 000 r/min for 10 min at 4 °C. The supernatant was stored at -70 °C until analysis.

2.5. Histological study

The tissues were embedded in paraffin for blinded histological analysis. Sections were stained with hematoxylin-eosin. Histological scoring was performed in a blind way. The gastric mucosa damage index was calculated as described by Guth *et al*[3], which was accumulated by the lesion of erosion, ulcer and bleeding restricted within gastric epithelia. The score's standard is: 0 for normal, 1 for less than 1 mm, 2 for 1–2 mm, *etc.* Meanwhile, the pathological score of gastric mucosa was counted according to the standard described by Mascuda *et al*[4]: 0 for normal, 1 for the lesion of surface epithelia, 2 for the surface mucosal hyperemia and edema, 3 for that of middle or bottom layer, 4 for the turbulence or necrosis of mucosal gland, and 5 for the necrosis or ulcer of deep layer.

2.6. Statistical analysis

Data were described as mean \pm SD, and statistical analysis was carried out using SPSS 13.0. Significance was considered at a $P < 0.05$ level.

3. Results

3.1. Successful modeling of PHG

The liver of the PHG rats appeared filemot, smaller, with big and small nodus on the surface. The portal vein of the model animals became wider and bended. The histological study revealed the occurrence of cirrhosis. Meanwhile, the PHG model rats showed much higher PVP [(17.21 \pm 4.72) cmH₂O vs (8.15 \pm 2.80) cmH₂O, $P < 0.01$, $n=10$] and more serious damage in the gastric mucosa, compared with their counterparts in the normal groups, suggesting that PHG model was successfully established (Figure 1). Twenty-three rats were used as PHG model, including 8 in group B, 7 in group C, 8 in group D with success rate of modeling as 76.7%.

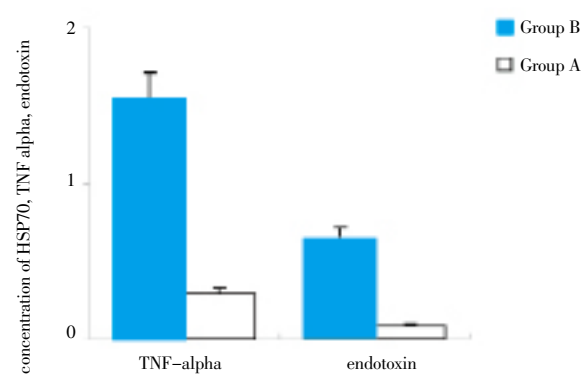


Figure 1. Changes of the levels of gastric mucosal, TNF- α and plasma endotoxin in PHG rats.

* $P < 0.01$ compared with Group A.

3.2. Changes of the levels of mucosal TNF- α and plasma endotoxin during PHG

Compared with the normal rats, PHG rats showed significantly decreased gastric mucosal HSP70, as well as increased mucosal TNF- α and plasma endotoxin ($P < 0.01$), suggesting that HSP70 could act as a protective factor, but TNF- α and endotoxin as destructive factors during PHG. (Figure 1).

3.3. Effects of exogenous endotoxin and BPI21 on the levels of plasma endotoxin and mucosal TNF- α in PHG rats

Exogenous endotoxin did not present any effect on the levels of mucosal TNF- α in normal rats ($P < 0.05$), but increased mucosal TNF- α in PHG rats ($P < 0.01$). In PHG rats exogenous endotoxin significantly increased plasma endotoxin, and that BPI21 did not present any effect on the levels of plasma endotoxin, but significantly decreased mucosal TNF- α level in PHG rats ($P < 0.01$), suggesting that endotoxin may be one of the most important pathogenetic factors in PHG (Figure 2).

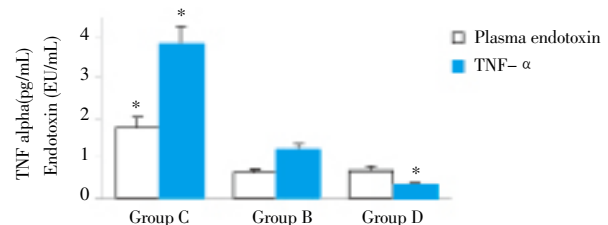


Figure 2. Effects of exogenous endotoxin and BPI21 on the levels of plasma endotoxin and mucosal TNF- α .

* $P < 0.01$ compared with group B.

3.4. Effects of exogenous endotoxin and BPI21 on the histological changes of the gastric mucosa

The PHG rats injected with endotoxin induced more serious damage in their gastric mucosa ($P < 0.01$). PHG rats, the PHG rats injected with LPS show serious damage in their gastric mucosa, including bleeding, edema, erosion, ulcer, as well as the disorganized epithelium, the disappeared gland and abundantly infiltrating inflammatory cells. Contrarily, injection of BPI21 remarkably ameliorate the damage ($P < 0.01$) (Figure 3, 4).

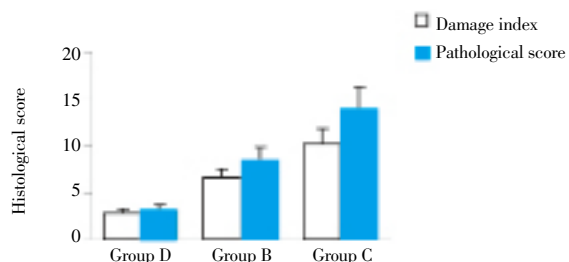


Figure 3. Effects of exogenous endotoxin and BPI21 on the histological score of the gastric mucosa in PHG rats. $P < 0.01$ compared with group B.

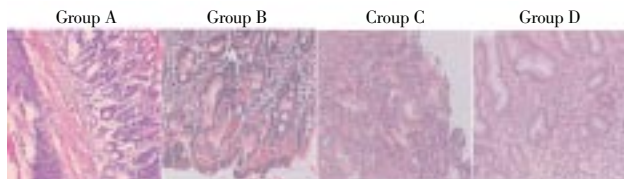


Figure 4. Effects of exogenous endotoxin and BPI21 on the pathological changes of the gastric mucosa in PHG rats.

4. Discussion

The imbalance between the protective and damage factors underlies the gastric mucosal injury during PHG. Endotoxin (potentially from intestine) not only induces abnormal hemodynamics, but also directly damages the mucosa. It is presumed that the endotoxin from intestine may trigger the gastric mucosal damage during PHG.

The results show that the endotoxin in the plasma from PHG rats significantly increased, which was consistent with the pathological damage in the gastric mucosa. The endotoxin level in the plasma increased remarkably in both normal and PHG rats injected with endotoxin, but only the latter show more serious mucosal injury. Watanabe *et al*[5] reported that endotoxin could not hurt the gastric mucosa from normal animals but induce serious injury in the gastric mucosa with venous congestion. These results suggest that exogenous endotoxin could induce the gastric mucosa during PHG. If the dosage continuously increase, the normal rats also show remarkable damage in their gastric mucosa (data not shown).

As a kind of protein universally located in the aniline blue granule within the neutrophilic granulocytes of human and mammal, BPI21 processes high affinity to the lipopolysaccharide molecule of endotoxin and competitively inhibits the contact between endotoxin and its target cell[6]. It is reported that BPI21 can alleviate the systemic inflammatory response induced by endotoxin and fight against the multiple organ dysfunction induced by intestinal endotoxemia/bacterial translocation after shock[7]. In the present study, the pathological performance of the gastric mucosa from PHG rats injected with BPI21 was significantly improved. These results ulteriorly support the concept that endotoxin may be one of the most important pathogenetic factors in PHG. Interestingly, this antagonist of endotoxin can not protect the animals from PHG if PHG has already occurred (data not shown).

The defensive mechanism of gastric mucosa is correlated with the microenvironment in which the epithelia cells

are located, including grume layer, cellular regeneration, mucosal blood stream and local compounds and cytokines. $TNF-\alpha$ is one of the most important local cytokines, which can induce local inflammation and organ lesion. It is reported that during PHG, $TNF-\alpha$ plays a pathogenetic[8] role by regulating the production of eNOS and prostacyclin. Meanwhile, $TNF-\alpha$ can increase the vascular permeability and aggravate the gastric injury[9]. Our results show that compared with their normal counterparts, the levels of the plasma endotoxin and mucosal $TNF-\alpha$ significantly increases in the PHG rats, together with the serious damage in the gastric mucosa, suggesting that $TNF-\alpha$ may be the major factor in the gastric mucosal injury induced by endotoxin. It remains unclear how endotoxin induces the mucosal expression of $TNF-\alpha$ during PHG.

In summary, this research shows that endotoxin could exert a pathogenetic role in the damage of the gastric mucosa during PHG, in which the mucosal expression of $TNF-\alpha$ may be involved. These results should be beneficial in exploring the novel therapy for the gastric mucosal injury during PHG in clinical practice in the future.

Role of funding source

This work was supported by a Natural Science Foundation of Hainan Province Grant (No. 80599).

Conflict of interest statement

We declare that we have no conflict of interest.

References

- [1] Perini RF, Camara PR, Ferraz JG. Pathogenesis of portal hypertensive gastropathy: translating basic research into clinical practice. *Nat Clin Pract Gastroenterol Hepatol* 2009; **6**(3): 150–158.
- [2] Nolan JP. The contribution of gut-derived endotoxins to liver injury. *Yale J Biol Med* 1979; **52**(1): 127–133.
- [3] Guth PH, Aures D, Paulsen G. Topical aspirin plus HCl gastric lesions in the rat: Cytoprotective effect of prostaglandin, cimetidine, and probanthine. *Gastroenterology* 1979; **76** (1): 88–93.
- [4] Itoh YH, Noguchi R. Pre-treatment with mild whole-body heating prevents gastric ulcer induced by restraint and water-immersion stress in rats. *Int J Hyperthermia* 2000; **16**(2): 183–191.
- [5] Watanabe D, Otaka M, Mikami K, Yoneyama K, Goto T, Miura K, et al. Expression of a 72-kDa heat shock protein, and its cytoprotective function, in gastric mucosa in cirrhotic rats. *J Gastroenterol* 2004; **39**: 724–733.
- [6] Wittmann I, Schonefeld M, Aichele D, Groer G, Gessner A, Schnare M. Murine bactericidal/permeability-increasing protein inhibits the endotoxic activity of lipopolysaccharide and gram-negative bacteria. *J Immunol* 2008; **180**: 7546–7552.
- [7] Sengupta M, Sharma GD, Chakraborty B. Hepatoprotective and immunomodulatory properties of aqueous extract of *Cucuma longain* carbon tetrachloride intoxicated swiss albino mice. *Asian Pac J Tro Biomed* 2011; **1**(3):193–199.
- [8] Chakraborty SP, Mahapatra SK, Sahu SK, Chattopadhyay S, Pramanik P, Roy S. Nitric oxide mediated staphylococcus aureus pathogenesis and protective role of nanoconjugated vancomycin. *Asian Pac J Tro Biomed* 2011; **1**(2): 102–109.
- [9] Devaraj VC, Krishna BG, Viswanatha GL, Kamath JV, Kumar S. Hepatoprotective activity of Hexap-A polyherbal formulation. *Asian Pac J Tro Biomed* 2011; **1**(2): 142–146.