

HOSTED BY



ELSEVIER

Contents lists available at ScienceDirect

Journal of Acute Disease

journal homepage: www.jadweb.orgCase report <http://dx.doi.org/10.1016/j.joad.2015.08.007>

A case of acute appendicitis in a patient with crossed renal ectopia

Ulvi Meral¹, Murat Zor^{2*}, Orhan Ureyen³, Nisa Cem Oren⁴, Hilmi Gungor³¹Department of Surgery, İzmir Military Hospital, İzmir, Turkey²Department of Urology, GMMMA Haydarpaşa Research and Training Hospital, Istanbul, Turkey³Department of Surgery, Bozyaka Research Hospital, İzmir, Turkey⁴Department of Radiology, İzmir Military Hospital, İzmir, Turkey

ARTICLE INFO

Article history:

Received 30 Jul 2015

Received in revised form 5 Aug 2015

Accepted 10 Aug 2015

Available online 13 Jun 2016

Keywords:

Crossed renal ectopia

Acute appendicitis

Appendectomy

Emergency

Abdominal pain

ABSTRACT

Crossed renal ectopia is a rare anomaly in urological clinical practice. Patients with this anomaly are usually asymptomatic. Herein, we reported a case of acute appendicitis in a patient with crossed renal ectopia. A 22-year-old man with abdominal pain admitted to the emergency department. His physical examination revealed muscular defense and painful mass at the lower quadrant. Abdominal ultrasonography revealed crossed renal ectopia with no sign of stones and acute appendicitis. Tomography confirmed crossed renal ectopia but not acute appendicitis. On-going clinical symptoms lead to surgical intervention and acute appendicitis diagnosis. The patient was treated with appendectomy with no perioperative complications. Appendectomy is a common surgical procedure in surgical clinical practice. Acute abdominal pain must be managed carefully in patients with unusual anatomy. Also surgeons should be aware of ectopic organs in surgical procedures, to avoid iatrogenic intraoperative injuries.

1. Introduction

Crossed renal ectopia is a rare condition and has a prevalence of 0.013%–0.500% in several case series^[1]. This congenital anomaly develops due to the migration defect of the kidney to the retroperitoneal fossa, and can be concomitant with other congenital anomalies^[2].

Acute appendicitis is a frequent surgical emergency in surgery clinics and differential diagnosis is very important before performing the surgical interventions^[3].

Several genitourinary, gastrointestinal and gynecological diseases must be kept in mind in differential diagnosis. In this study we reported a case of acute appendicitis who admitted to emergency clinic with abdominal pain, and whose initial evaluation revealed only left crossed renal ectopia.

2. Case report

A 22-year-old male patient was admitted to our emergency department with sudden onset abdominal pain. His physical examination revealed palpable right lower quadrant mass and muscular defense. He had no fever, vomiting and loss of appetite. Urinalysis and blood analysis were normal and the patient had no neutrophilia.

Abdominal ultrasonography revealed left crossed renal ectopia and grade 1 pelvicaliectasis. Kidney or ureteral stone disease was not documented with ultrasonography. Abdominal ultrasonography also did not reveal any sign of inflammation of the right lower quadrant region. The diagnosis was not highly suggestive for appendicitis or stone disease in an ectopic kidney.

Alvarado score was calculated according to all these signs and contrast-enhanced computed tomography was performed to the patient. Crossed renal ectopia was confirmed but no reason for abdominal pain was documented (Figure 1). The patient was hospitalized and oral fluid intake was stopped. Neither pain recovery nor resolution of defense and rebound were seen in his follow-up, and thus the patient underwent diagnostic laparotomy.

Intraoperative evaluation revealed an inflamed appendix within a fecaloma (Figure 2). Appendectomy was performed.

*Corresponding author: Murat Zor, Department of Urology, GMMMA Haydarpaşa Research and Training Hospital, Istanbul, Turkey.

Tel: +90 312 3045610

Fax: +90 312 3042150

E-mail: murat804@yahoo.com

Peer review under responsibility of Hainan Medical College. The journal implements double-blind peer review practiced by specially invited international editorial board members.

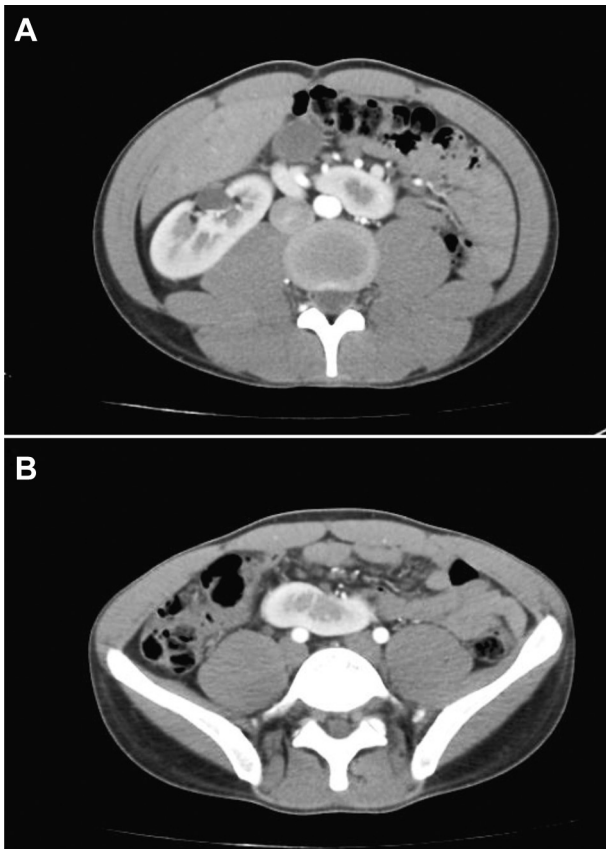


Figure 1. Computed tomographic image of crossed renal ectopia.

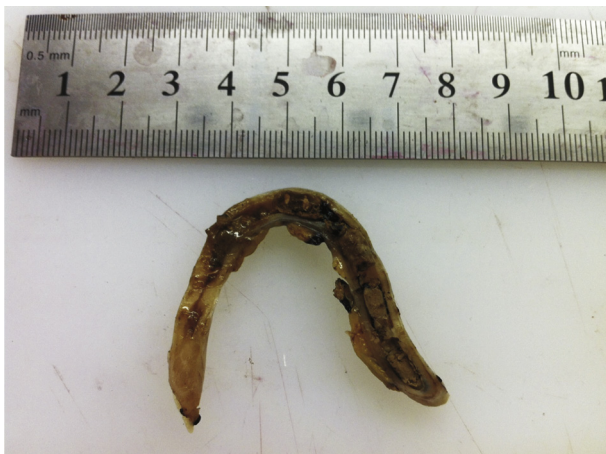

Figure 2. Appendectomy material within a fecaloma.

His complaints was totally resolved postoperatively and discharged on the fourth postoperative day.

3. Discussion

Crossed renal ectopia is a rare congenital anomaly and is thought to result from the abnormal development of the ureteric bud and metanephric blastema during the fourth to eighth weeks of gestation. The currently accepted classification is (a) unilateral fused kidney (inferior ectopia); (b) sigmoid or S-shaped kidney; (c) lump kidney; (d) L-shaped kidney; (e) disc kidney; (f) unilateral fused kidney (superior ectopia). It has a male predominance of 3:2 and left to right crossover occurs more

frequently^[2,4,5]. Acute appendicitis is a frequently seen clinic problem in surgery and emergency medicine departments. In different series it was reported that 20%–44% of the clinical diagnosis was false. Several surgeons suggest 30% false positivity as acceptable^[4]. Several clinical scoring systems are developed in order to reduce these false positivity rates and following morbidity and mortality associated with unnecessary surgery. Alvarado scoring system is one of these scoring systems, which is widely accepted by surgeons. Scoring is made according to loss of appetite, nausea, vomiting, abdominal tenderness, rebound positivity, high fever, and the presence of leukocytosis and neutrophilia. Scores between 0 and 3 are suggestible for follow-up, 3–7 for advanced imaging and scores above 7 for surgical intervention^[6]. In our patient Alvarado score was 5/10 and thus we performed abdominal contrast-enhanced computed tomography in order to confirm diagnosis. CT revealed crossed renal ectopia but no sign of stone disease, which could be a cause of abdominal pain. No sign highly suggestive for acute appendicitis were also documented and the patient underwent laparotomy due to on-going rebound, defense and abdominal pain. The final diagnosis could be done by surgical intervention.

Intraabdominal and retroperitoneal anomalies can sometimes hide and wreath the underlying disease. They may also be important in the surgical interventions of these regions, because of possible iatrogenic injuries. In their case report, Jindal and colleagues reported an iatrogenic dual ureteric and renal injury following appendectomy in a patient with crossed renal ectopia^[7]. In our patient initial ultrasonographic diagnosis of crossed renal ectopia was a confounder for the true diagnosis and CT results were not highly suggestive for acute appendicitis but clinical signs lead us to make the correct decision and treatment.

As a result we can easily conclude that congenital anomalies should not affect the diagnostic decisiveness and surgical intervention can be mandatory in suspected cases. On the flip side, one must keep in mind that surgical dissections must be made meticulously in order to avoid iatrogenic injuries associated with these anatomic variations.

Conflict of interest statement

The authors report no conflict of interest.

References

- [1] McDonald JH, McClellan DS. Crossed renal ectopia. *Am J Surg* 1957; **93**: 995-1002.
- [2] Wein AJ, Kavoussi LR, Novick AC, Partin AW, Peters CA. Anomalies of the upper urinary tract. In: *Campbell Walsh Urol*. 10th ed. Philadelphia: Saunders; 2011, p. 3140-5.
- [3] Drake FT, Flum DR. Improvement in the diagnosis of appendicitis. *Adv Surg* 2013; **47**: 299-328.
- [4] Hofenann J, Rasmussen OO. Aids in the diagnosis of acute appendicitis. *Br J Surg* 1989; **76**: 774-90.
- [5] Solanki S, Bhatnagar V, Gupta AK, Kumar R. Crossed fused renal ectopia: challenges in diagnosis and management. *J Indian Assoc Pediatr Surg* 2013; **18**(1): 7-10.
- [6] Ohle R, O'Reilly F, O'Brien KK, Fahey T, Dimitrov BD. The Alvarado score for predicting acute appendicitis: a systematic review. *BMC Med* 2011; **9**: 139.
- [7] Jindal T, Kamal MR, Mukherjee S, Mandal SN, Karmakar D. Management of an iatrogenic injury in a crossed ectopic kidney without fusion. *Korean J Urol* 2014; **55**(8): 554-6.