

HOSTED BY



ELSEVIER

Contents lists available at [ScienceDirect](http://www.sciencedirect.com)

Journal of Acute Disease

journal homepage: www.jadweb.orgCase report <http://dx.doi.org/10.1016/j.joad.2015.10.006>

A case report of acute injury in ankylosing spondylitis

Yu-Hang Yeh¹, Yu-Jang Su^{2,3,4,5*}¹Department of Emergency Medicine, Taipei City Hospital, Zhongxing Branch, Taipei City, Taiwan²Department of Emergency Medicine, Mackay Memorial Hospital, Taipei City, Taiwan³Department of Oral Hygiene, College of Oral Medicine, Taipei Medical University, Taipei City, Taiwan⁴Department of Emergency Medicine, Mackay Medical College, New Taipei City, Taiwan⁵Mackay Junior College of Medicine, Nursing and Management, Taipei City, Taiwan

ARTICLE INFO

Article history:

Received 14 Jun 2015

Received in revised form 19 Jun,

2nd revised form 17 Aug 2015

Accepted 18 Oct 2015

Available online 13 Jun 2016

Keywords:

Ankylosing spinal disorder

Cervical spine fracture

Trauma

CT scan

ABSTRACT

Ankylosing spinal disorders tend to fracture after minor trauma because of its changed biomechanical properties. Herein we presented an ankylosing spinal disorders case with cervical spine fracture in a trauma after neck protection and surgical airway application. On CT scan of cervical spine, ankylosing spondylitis with an extension C4–C5 fracture was found. The patients' family decided not to receive operation to immobilize his cervical spine, then he was admitted to our surgical intensive care unit. He was discharged against medical advice two months later with a permanent tracheostomy with ventilator dependence due to high-level spinal cord injury. Timely identification of unstable fractures is instrumental in avoiding adverse neurologic sequela.

1. Introduction

Ankylosing spinal disorders (ASDs) such as ankylosing spondylitis and diffuse idiopathic skeletal hyperostosis are chronic diseases that cause inflammation and fusion of the joints, especially the spine. ASD tends to fracture after minor trauma because of its changed biomechanical properties^[1]. Emphasis was placed on cervical spine protection in all trauma patients, and we should immobilize cervical spine when patients with loss of consciousness, midline neck tenderness, abnormal neurologic signs, or other suspicion on cervical spine injury. Herein we presented an ASD case with cervical spine fracture in a trauma, and we secured his airway, protected the C spine and diagnose the fracture rapidly in emergency department.

2. Case report

A sixty years old man suffered from a blunt trauma to the head in a motor vehicle collision and lost his consciousness. He was sent to our emergency department by emergency medical service. On arrival of emergency department, we applied neck collar and found he had severe dyspnea with hypoxia. We tried to intubate endotracheal tube but failed, then we performed emergent cricothyroidotomy immediately and he regained consciousness after adequate ventilation. Unfortunately, quadriplegia was noticed. Under the impression of spinal cord injury, we arranged a CT scan of cervical spine, which showed a distinct picture of the fused cervical spine and a break between the fourth and fifth cervical vertebra ([Figures 1 and 2](#)).

Ankylosing spondylitis with an extension C4–C5 fracture was concluded. Otherwise, there is no evidence of intracranial hemorrhage. His family decided not to receive operation to immobilize his cervical spine, then he was admitted to our surgical intensive care unit. He was discharged against medical advice two months later with a permanent tracheostomy with ventilator dependence due to high-level spinal cord injury.

*Corresponding author: Yu-Jang Su, Department of Emergency Medicine, Mackay Memorial Hospital, New Taipei City, Taiwan.

E-mail: yjsu.5885@mmh.org.tw

Peer review under the responsibility of Hainan Medical College. The journal implements double-blind peer review practiced by specially invited international editorial board members.

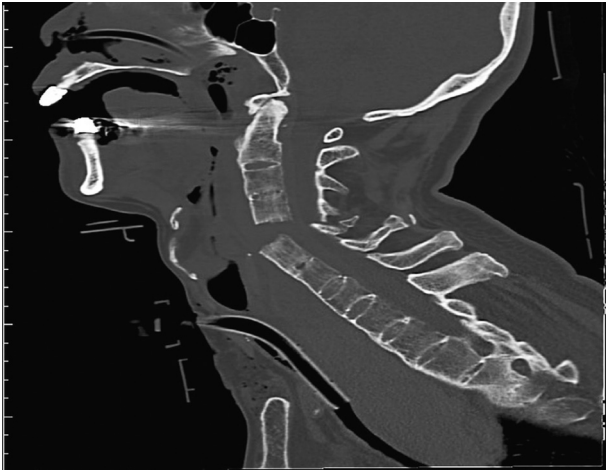

Figure 1. We noticed the extension fracture between the fourth and fifth cervical spine. Besides, the neck collar and the cricothyrotomy tube were also revealed.

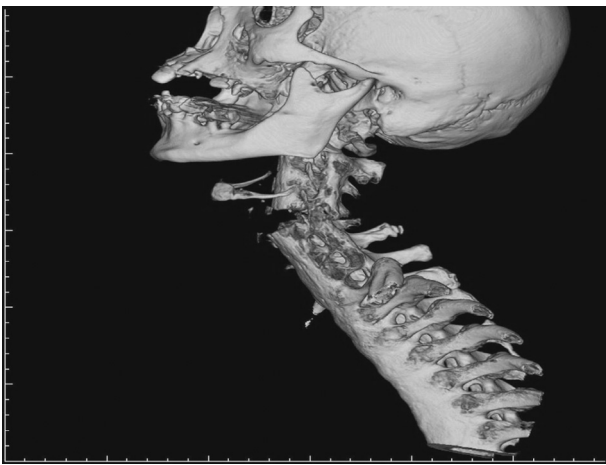


Figure 2. In the 3D reconstruction image of CT scan of cervical spine, a distinct picture of fused spine and extension fracture were demonstrated.

3. Discussion

In our case, we demonstrated a well cervical spine protection and secured the airway early. Accurate diagnosis and early operation may be helpful. However, his family decided not to receive operation and the outcome was poor.

Ankylosing spondylitis affects 0.5% of the population^[2]. Overall prevalence of ASD is increasing, because diffuse idiopathic skeletal hyperostosis becomes more and more commonly seen due to its association with age, obesity, and type 2 diabetes mellitus^[3]. In radiographs of cervical spine, the most typical findings are often bamboo spine in ankylosing spondylitis and flowing calcification along anterolateral aspect of vertebral bodies in diffuse idiopathic skeletal hyperostosis. Cervical spine injuries were most commonly seen and accounted for 75% of ASD patients having spine fractures^[4].

ASD is prone to fracture after minor trauma due to its poor elasticity. Patients with ASD often resulted in neurologic

complications and incomplete neurologic recovery. Many patients were unable to cite a specific causative trauma^[5]. Neurologic deficits were often subtle on initial presentation, resulting in many injuries being missed^[6]. Poor visualization of lower cervical fractures on conventional radiographs usually led to misinterpreting^[6]. About 65% of ASD patients with cervical spine fractures had neurological deficits while admission^[2].

In general populations, cervical spine injuries in young patients mostly involved in lower cervical spines, and that in the elderly and child usually occurred in upper ones. The majority of cervical spine fractures in ASD were transdiscal extension injuries, most commonly affecting C6–C7^[7]. In a 7-year period study, 58% of them had spinal cord injury and 19% had delayed diagnosis. Delayed diagnosis resulted in worse prognosis and more complications^[7]. In the management, long and rigid internal fixations are necessary owing to osteoporosis and ageing resulting from ankylosing spondylitis^[8]. Standard interventions were open reduction, anterior decompression and fusion, and anterior–posterior stabilization^[9]. Mortality correlated with age older than 70 years old, the number of comorbidities, and lower energy mechanism of injury^[7]. Timely identification of unstable fractures is instrumental in avoiding adverse neurologic sequela.

Conflict of interest statement

The authors report no conflict of interest.

References

- [1] Charles YP, Buy X, Gangi A, Steib JP. Fracture in ankylosing spondylitis after minor trauma: radiological pitfalls and treatment by percutaneous instrumentation. A case report. *Orthop Traumatol Surg Res* 2013; **99**(1): 115-9.
- [2] Gilard V, Curey S, Derrey S, Perez A, Proust F. Cervical spine fractures in patients with ankylosing spondylitis: importance of early management. *Neurochirurgie* 2014; **60**(5): 239-43.
- [3] Sencan D, Elden H, Nacitarhan V, Sencan M, Kaptanoglu E. The prevalence of diffuse idiopathic skeletal hyperostosis in patients with diabetes mellitus. *Rheumatol Int* 2005; **25**(7): 518-21.
- [4] Han SW, Kim SH. Ankylosing spondylitis with cervical fracture, cardiac arrest, locked-in syndrome and death. *BMJ Case Rep* 2012; **2012**: bcr0120125522.
- [5] Carnell J, Fahimi J, Wills CP. Cervical spine fracture in ankylosing spondylitis. *West J Emerg Med* 2009; **10**: 267.
- [6] Thumbikat P, Hariharan RP, Ravichandran G, McClelland MR, Mathew KM. Spinal cord injury in patients with ankylosing spondylitis: a 10-year review. *Spine (Phila Pa 1976)* 2007; **32**: 2989-95.
- [7] Caron T, Bransford R, Nguyen Q, Agel J, Chapman J, Bellabarba C. Spine fractures in patients with ankylosing spinal disorders. *Spine (Phila Pa 1976)* 2010; **35**: E458-64.
- [8] Koizumi M, Iida J, Shigematsu H, Satoh N, Tanaka M, Kura T, et al. Posterior fixation of a cervical fracture using the RRS loop spine system and polyethylene tape in an elderly ankylosing spondylitis patient: a case report. *Asian Spine J* 2012; **6**(1): 60-5.
- [9] Badve SA, Bhojraj SY, Nene AM, Varma R, Mohite S, Kalkotwar S, et al. Spinal instability in ankylosing spondylitis. *Indian J Orthop* 2010; **44**(3): 270-6.