



Contents lists available at ScienceDirect

Journal of Acute Disease

journal homepage: www.jadweb.org



Document heading doi: 10.1016/S2221-6189(13)60155-9

Survival after blunt left ventricular rupture with cardiac tamponade

Yu-Jang Su^{1,2*}, Chang-Chih Chen^{1,3}

¹Department of Emergency Medicine, Mackay Memorial Hospital, No.92, Sec 2, Chung-Shan North Rd. Taipei 10449, Taiwan

²Department of Oral Hygiene, College of Oral medicine, Taipei Medical University, Taipei 110, Taiwan

³School of Dentistry, College of Oral medicine, Taipei Medical University, Taipei 110, Taiwan

ARTICLE INFO

Article history:

Received 5 July 2013

Received in revised form 31 July 2013

Accepted 20 August 2013

Available online 20 December 2013

Keywords:

Chest contusion

Blunt heart rupture

Left ventricle

ABSTRACT

A 34-year-old man was drunk and drove to hit a traffic island. Cold sweating and unconscious status were found on arrival. Vital signs revealed BP 42/25, and heart rate 121/min. There was massive pericardial effusion with cardiac tamponade found by CT. Immediate surgical intervention and rupture of left ventricular (LV) free wall was found. He was discharged after 2 d intensive care unit (ICU) observation and 5-day regular ward care. There is high mortality rate in traumatic heart rupture although timely repair, over all mortality is around 20%–36% in recent 3 years.

1. Introduction

Survival after blunt cardiac rupture is rarely seen clinically. It is more commonly seen in middle-aged people and male by gender. Above half of cases have other injuries besides left ventricular rupture. The hospital stays are associated with concomitant injuries and comorbidity. Early diagnosis and immediate surgical intervention saves lives in traumatic LV rupture. Although timely repair the ruptures of heart, overall mortality rate is high, and it improved in recent three years. The outcome is significant associated with comorbid injury, especially the traumatic neurological injury. Here we presented a 34-year-old man who was drunk and drove to hit a traffic island. Tachycardia, shock, cold sweating and unconscious status were found on arrival to emergency department (ED). There was massive pericardial effusion with cardiac tamponade seen by image studies. Immediate consultation of cardiovascular surgeon and rupture of left ventricular (LV) free wall was found by emergent surgery. He was discharged after successful resuscitation and care.

2. Case report

A 34-year-old man was drunk and drove to hit a traffic island. He was transferred by emergency medical services without delay. Cold sweating and unconscious status were

found on arrival. Blood pressure was taken as 42/25, and the heart rate was 121/min. The chest X ray (CXR) showed indistinct heart border (star mark in Figure 1). Pericardial tamponade was highly suspected at that time and computed tomography (CT) showed massive pericardial effusion with cardiac tamponade (white arrow keys in Figure 2). Immediate consultation of cardiovascular surgeon and rupture of left ventricular (LV) free wall was found by emergent surgery. He was discharged after post-operative 2-day intensive care unit (ICU) observation and 5 d regular ward care.

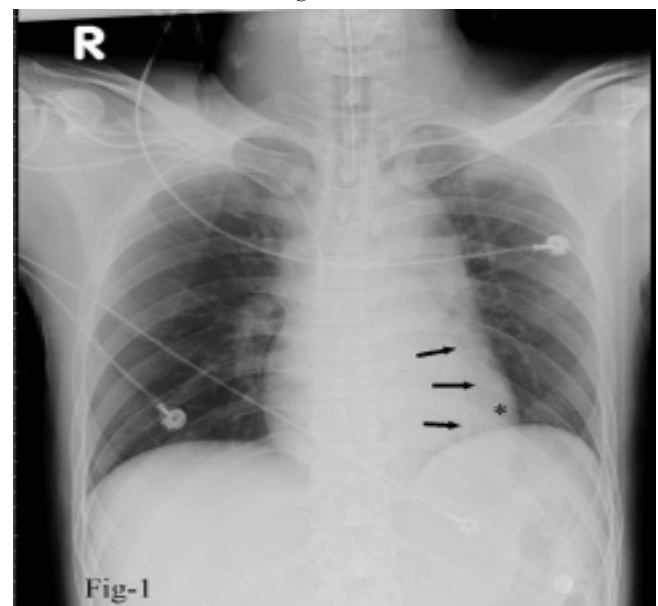


Figure 1. The chest X ray (CXR) showed indistinct heart border (black arrow keys) with a radio-lucent area (star-mark).

*Corresponding author: Yu-Jang Su, M.D. No.92, Sec 2, North Chung-Shan Rd. Taipei 10449. Department of Emergency Medicine, Mackay Memorial Hospital, Taipei, Taiwan.

Tel: 886-2-25433535*3126

E-mail: yjsu@ms1.mmh.org.tw

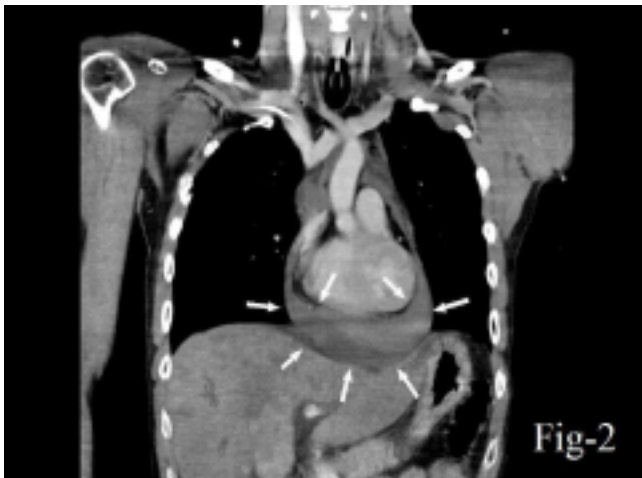

Figure 2. There was massive pericardial effusion with cardiac tamponade seen (white arrow keys).

Table 1.

Year	Author	Age	Etiology	Concomitant injury	Reference
1980	Leavitt	29	Motor vehicle accident	LLL lung injury, LV	Ann Thorac Surg[2]
1981	Hendel	48	Motor vehicle accident	RA, LV rupture	J Thorac Cardiovasc Surg[3]
1995	Nakamura	30	Motor vehicle accident	RA, LV rupture	ihon Kyobu Geka Gakkai Zasshi[4]
1996	Weiner	54	Motor vehicle accident	LV rupture	Am J Emerg Med[5]
2005	Nagahama	67	Multiple blunt trauma	LV rupture	Kyobu Geka[6]
2009	Su	34	Motor vehicle accident	LV rupture	This case
2010	Nakamura	27	Motor vehicle accident	LV, rib fracture	Kyobu Geka[7]
2011	Ueda	75	Blunt chest trauma	LV, rib fracture	Gen Thorac Cardiovasc Surg[8]
2012	Jennings	38	Fall	LV rupture	Crit Ultrasound J[9]

LLL=left lower lobe; LV=Left ventricle; RA=Right atrium.

3. Discussion

Blunt cardiac rupture commonly resulted from direct compression by sternum and spine[1]. From PubMed search for literatures review, we used keywords as blunt left ventricle rupture, cardiac tamponade and survival, then we found 8 cases (Table 1)[2–9].

Survival after blunt cardiac rupture is rarely seen clinically, because most of victims died at scene of trauma. It is more commonly seen in middle-aged people and male by gender. M:F=2:1[10]. Of all literatures review, there are nine cases (including our case) of survival after blunt left ventricular ruptures with cardiac tamponade. Mean age of nine cases is 44.6 years old and male are predominant with M:F=2:1. About 55.5% of cases have other injuries besides left ventricular rupture. The hospital stays are associated with concomitant injuries and comorbidity. In our case, he got recovered without sequelae and was discharged on post-operative seventh day.

In the location of ruptures, right side is more commonly involved than the left side. Right atrial ruptures are accounted for 40.6% to 59%, followed by right ventricle (31.3%), left atrium (25%) and the least common is left ventricular rupture (6.5% to 13%)[1,10,11]. Rupture of two chambers was accounted for 9.4%[10].

About 58.3% blunt cardiac rupture cases happened to cardiac tamponade and massive hemothorax were found in 10% of cases[10]. We should highly suspect traumatic heart rupture if there is hazy heart border in chest film. In this case, radio-lucent heart border of chest X ray (CXR) is highly suspected pericardial effusion after trauma.

For emergency physicians, focused abdominal sonography for trauma (FAST) is a helpful tool for rapid detecting pericardial

effusion after blunt injury of chest. Bedside echocardiogram was highly suggested in blunt chest trauma detecting conditions needing emergent surgical intervention[12]. Early diagnosis and immediate surgical intervention saves lives in traumatic LV rupture. Although timely repair the ruptures of heart, overall mortality rate is high as 81.3% in the year of 1990[10], and it lowered to 20%~36% in recent three years[13]. The outcome is significant associated with co-morbid injury, especially the traumatic neurological injury[13].

Blunt chest trauma related cardiac rupture is a surgical emergency with high mortality rate. Diagnosis relies on the presentation (shock and engorged jugular vein) and suspicious image study (cardiac tamponade or massive hemothorax). Timely and early surgical interventions save lives.

Conflict of interest statement

The authors report no conflict of interest.

References

- Türkmen N, Bilgen MS, Eren B, Fedakar R, Senel B. Cardiac rupture due to fall: a case study. *Ann Acad Med Singapore* 2009; **38**(2): 156–157.
- Leavitt BJ, Meyer JA, Morton JR, Clark DE, Herbert WE, Hiebert CA. Survival following nonpenetrating traumatic rupture of cardiac chambers. *Ann Thorac Surg* 1987; **44**(5): 532–535.
- Hendel PN, Grant AF. Blunt traumatic rupture of the heart. Successful repair of simultaneous rupture of the right atrium and left ventricle. *J Thorac Cardiovasc Surg* 1981; **81**(4): 574–576.
- Nakamura T, Konobu T, Murao Y, Tabuse H, Miyamoto S, Kitamura S. A successful management of acute ruptures of the right atrium and left ventricle due to blunt trauma. *Nihon Kyobu Geka Gakkai Zasshi* 1995; **43**(3): 407–412.
- Weiner Y, Berkenstadt H, Segal E. Survival after left ventricular rupture following blunt chest injury. *Am J Emerg Med* 1996; **14**(2): 186–188.
- Nagahama H, Fukushima Y, Fukuda T, Hayase T, Yoshioka M. Acute left ventricular rupture and cardiac tamponade caused by blunt trauma; report of a case. *Kyobu Geka* 2005; **58**(10): 911–914.
- Nakamura K, Toyama S, Nakashima K, Maekawa Y, Minagawa T, Yoshimura Y, et al. Successful repair of left ventricular laceration due to traumatic broken ribs. *Kyobu Geka* 2010; **63**(3): 194–197.
- Ueda S, Ito Y, Konnai T, Suzuki S, Isogami K. Delayed cardiac rupture occurring two months after blunt chest trauma. *Gen Thorac Cardiovasc Surg* 2011; **59**(1): 45–47.
- Jennings SB, Rice J. Supporting the early use of echocardiography in blunt chest trauma. *Crit Ultrasound J* 2012; **4**(1):7.
- Brathwaite CE, Rodriguez A, Turney SZ, Dunham CM, Cowley R. Blunt traumatic cardiac rupture. A 5-year experience. *Ann Surg* 1990; **212**(6): 701–704.
- Pevec WC, Udekwu AO, Peitzman AB. Blunt rupture of the myocardium. *Ann Thorac Surg* 1989; **48**(1): 139–142.
- Symbas NP, Bongiorno PF, Symbas PN. Blunt cardiac rupture: the utility of emergency department ultrasound. *Ann Thorac Surg* 1999; **67**(5): 1274–1276.
- Nan YY, Lu MS, Liu KS, Huang YK, Tsai FC, Chu JJ, et al. Blunt traumatic cardiac rupture: therapeutic options and outcomes. *Injury* 2009; **40**(9): 938–945.