

HOSTED BY



ELSEVIER

Contents lists available at ScienceDirect

Journal of Acute Disease

journal homepage: www.jadweb.orgReview article <http://dx.doi.org/10.1016/j.joad.2015.04.002>

The research progress of acute small bowel perforation

Rudolf Schiessel*

Em.Chief Surgical Department Donauspital, Vienna, Austria

ARTICLE INFO

Article history:

Received 14 Apr 2015

Received in revised form 15 Apr 2015

Accepted 20 Apr 2015

Available online 7 Jul 2015

Keywords:

Small bowel perforation

Aetiologies

Treatment

ABSTRACT

This article reviews the various aetiologies of small bowel perforations and their management. In addition to the well-known aetiologies such as trauma, inflammation and circulatory disorders, several new causes of small bowel perforation have been described in recent years. The spectrum reaches from iatrogenic perforations during laparoscopic surgery or enteroscopies to drug-induced perforations with new anti-cancer agents. The management of small bowel perforations requires a concept consisting of the safe revision of the leaking bowel and the treatment of the peritonitis. Depending on the local situation and the condition of the patient, several treatment options are available. The surgical management of the bowel leak can range from a simple primary closure to a delayed restoration of bowel continuity. When the condition of the bowel or patient is frail, the risk of a failure of a closure or anastomosis is too high, and the exteriorization of the bowel defect as a primary measure is a safe option. The treatment of the peritonitis is also dependent on the condition of the patient and the local situation. Early stages of peritonitis can be treated by a simple peritoneal lavage, either performed by laparoscopy or laparotomy. Severe forms of peritonitis with multi-organ failure and an abdominal compartment syndrome need repeated peritoneal revisions. In such cases, the abdomen can only be closed temporarily. Different technical options are available in order to overcome the difficult care of these patients.

1. Introduction

Small bowel perforation is a well-known, but not very common cause of an acute abdomen. The estimated incidence in one study was 1 in 300 000–350 000^[1]. How often an emergency unit has to deal with this problem depends on the regional situation of a hospital. In our own busy institution, we observed from 1992 to 2005, 66 (26%) small bowel perforations out of 256 intestinal perforations.

Intestinal perforations are still a major challenge for the involved medical personnel. Since the time factor plays an important role for the survival, a highly motivated team is necessary to handle this life-threatening condition.

In the past, several innovations in the surgical management have been published. However, the superiority over the conventional methods is still under investigation.

2. Causes of small bowel perforation

Various aetiologies can cause a perforation of the small bowel (Table 1).

2.1. Trauma

Penetrating injuries after stabbing or gunshots are daily business in emergency rooms of big cities all over the world. Gunshots with pellets of lead or soft iron can occur as a serious hunting accident. In particular, when the shot comes from a short distance, myriads of pellets can perforate the bowel. The removal of the pellets and the repair of the damaged bowel can take many hours.

Non-penetrating injuries occur during traffic accidents usually in combination with other intra-abdominal injuries, such as liver and spleen rupture. A common blunt injury is caused by the handlebars of bicycles.

2.2. Foreign bodies

Penetration of the bowel can also occur from the inside: ingested toothpicks perforating the intestine are a life-

*Corresponding author: Rudolf Schiessel, MD, Professor of Surgery, Em.Chief Surgical Department Donauspital, Klosterneuburg, Jasmingasse 2, Vienna 3400, Austria.

E-mail: schiesselprof@aon.at

Peer review under responsibility of Hainan Medical College.

Table 1

Various aetiologies of the small bowel perforation.

Causes of small bowel perforation	Specific forms
Trauma	Shot, stab, explosives, blunt injury
Foreign bodies	Toothpicks, fishbone, magnetic toys
Iatrogenic	Laparoscopy: Veress-needle, trocar, diathermy, instruments Enteroscopy Peritoneal dialysis
Irradiation	
Bowel obstruction	Strangulation Volvulus
Inflammatory diseases	Crohn's disease Tuberculosis Typhoid fever Actinomycosis Ascariasis Cytomegaly infection
Vascular problems	Mesenteric embolism Mesenteric thrombosis Vasculitis
Drugs	Nonsteroid antiinflammatory drugs Steroids Oral contraceptive pills Potassium chloride Iron Cocaine. Crack Cytotoxic chemotherapy Bevacizumab Tocilizumab Ipilimumab Temsirolimus Cetuximab Sunitinib
Tumours	Primary tumours: lymphoma, adenocarcinoma, angiosarcoma Metastatic tumours: melanoma, mesothelioma, breast cancer, lung cancer
Congenital anomalies	Meckels diverticulum Ileal or jejunal duplication
Craft versus host reaction	Acute intestinal craft versus host disease after bone marrow transplantation

threatening condition with a mortality of 9.6%^[2]. In this study, 54% of the patients were not aware of the incident. In 30% of the patients, the toothpick could be removed by endoscopy. This was only possible in localizations reachable for gastroscopes or colonoscopes. Fishbones, chicken bones, needles and safety pins have also been described as a cause of perforation. In children, magnetic toys have been recognized as a serious hazard. When magnetic particles are ingested together with another magnet, or with a metal foreign body, the magnetic power can cause a bowel wall necrosis with perforation. In USA, the Consumer Safety Commission has become aware of this problem since 2003. Several products have been recalled from the manufacturers since then^[3].

2.3. Iatrogenic causes

Laparoscopic surgery needs for imaging and instrumentation ports which are inserted through the abdominal wall by means of trocars. Despite of several safety measures, a bowel perforation

is always possible. When such a perforation is not discovered immediately by the surgeon, the diagnosis might be difficult in the postoperative setting, because the symptoms of the consecutive peritonitis can be obscured by postoperative pain. In a large study, van Voort found 0.13% perforations under 329935 laparoscopic operations^[4]. From these, 56% comprised the small bowel. The perforation was caused in 46% by a trocar or Veress-needle for producing a pneumoperitoneum; in 26%, it was caused by diathermy or laser. The mortality of bowel perforation during laparoscopy was 3.6%. Umbilical piercing has been described as a particular risk factor for establishing a pneumoperitoneum leading to small bowel perforation due to adhesion formation between bowel and anterior abdominal wall^[5].

Another new problem is the perforation during an enteroscopy. Long enteroscopes are now used for the discovery of obscure intestinal bleeding sites and other rare conditions. In order to advance the enteroscope through the small bowel, two balloons are alternatively inflated, a potential hazard for perforation.

The insertion of catheters for peritoneal dialysis can lead to bowel perforation. Laparoscopic techniques have been advocated to minimize this risk factor^[6].

2.4. Irradiation

Inadvertent irradiation of the small bowel has been a problem in the past. In particular, the irradiation of tumours of pelvic organs has a high risk of small bowel damage. New radiation techniques minimize this risk in modern radiation therapy.

2.5. Bowel obstruction

Ischaemia is the main cause of perforation as a consequence of bowel perforation. Local pressure or the strangulation of the mesentery is the most common mechanism.

2.6. Inflammatory bowel disease

Crohn's disease has been described in several studies as a major cause of small bowel perforation. Although the inflammatory process usually leads to a thickening of the bowel wall and the progression results rather in fistula formation, free perforation can occur. In addition to the inflammatory process, other factors can contribute to a perforation. Medications such as corticosteroids and monoclonal antibodies may play a role. Perforations have been described after diagnostic procedures such as capsule endoscopy, when the capsule is caught in a stricture. Endoscopic dilatation of a stricture with a balloon can also lead to a perforation.

Infections such as typhoid fever and tuberculosis are common causes of bowel perforation in developing countries.

2.7. Drugs

New anticancer drugs can inhibit angiogenesis of tumours successfully, but in some cases a bowel perforation may occur. Bevacizumab has been shown to cause bowel perforation in 1%–4%^[7], when used for chemotherapy for colon cancer, ovarian

cancer, lung cancer, *etc.* Other biological agents in use for tumour therapy have also been reported to cause bowel perforation^[8] (Figure 1).

2.8. Congenital malformations

Meckel's diverticulum is a well-known malformation in the terminal ileum. These diverticula may contain displaced acid producing gastric mucosa. As a consequence, a peptic ulcer can develop. Typical complications are bleeding and perforation. Gastrointestinal stroma tumours in such diverticula can also occur and lead to a perforation.

3. Management of bowel perforations

The principle of management is always surgical closure or exclusion of the perforation and treatment of the peritonitis.

3.1. Surgical closure or exclusion of the perforation

Before the surgical management can take place, a proper evaluation of the patient is necessary. In case of an acute abdomen, the clinical picture and free air found either by means of a plain abdominal X-ray or by CT will usually lead quickly to the indication of a laparotomy or laparoscopy^[9]. Parallel to the diagnostic measures, eventual fluid and electrolyte imbalances and organ failures have to be treated.

Since the exact localization of a small bowel perforation is usually not known preoperatively, the surgeon has to perform a complete meticulous evaluation of the intestine in order to find all possible leaks. For the exploration of an acute abdomen, laparoscopy has been shown to be an important tool^[10]. However, the surgeon has to decide in the acute situation whether laparoscopy is the proper method for the particular patient and for himself. Many factors may influence the decision, such as the condition of the patient, experience of the surgeon and availability of technical equipment in the emergency situation.

When the leak is identified, a decision has to be made whether it can be closed safely by sutures or not (Figure 2). For a primary closure, the bowel wall has to be free of traumatization, inflammation or necrotic tissue. The closure has to be gastight and must not compromise the diameter of the bowel lumen, therefore, it should always be performed in transverse direction.

In case of resection, we have to consider whether bowel continuity can be restored immediately by means of a primary anastomosis or not. A primary anastomosis requires a healthy tissue on both ends and a good local and general circulation. Patients with multi-organ failure, severe faecal peritonitis, poor mesenteric circulation or dependence on high doses of vasoconstrictors are poor candidates for a primary anastomosis. An anastomotic failure might definitely lead to a further deterioration and death of such severely compromised patients.

Much safer than a primary anastomosis is in such cases a delayed anastomosis. In our institution, we found it very helpful to delay the restoration of bowel continuity. Both bowel ends are brought through the abdominal wall, then they are sutured together on the posterior wall. The now formed double lumen common stoma is sutured with mucocutaneous sutures to the skin (Figure 3). This technique allows a postoperative monitoring of the vitality of the bowel without a second look operation. After the recovery of the patient, the closure of the stoma with restoration of bowel continuity is easy and requires no a further laparotomy.

3.2. Treatment of the peritonitis

When the source of peritoneal infection is eliminated, it is important to consider the further treatment of the peritonitis. In a case with a fresh peritonitis, a complete debridement of the intestine combined with a peritoneal lavage will be sufficient for most cases. Patients with a delayed diagnosis of the peritonitis present with a severe form of the peritonitis with thick layers of fibrin, mesenterial abscesses and oedema of the bowel wall need a much more sophisticated treatment (Figure 1). These patients suffer usually from an abdominal compartment syndrome with high intra-abdominal pressure, respiratory insufficiency and

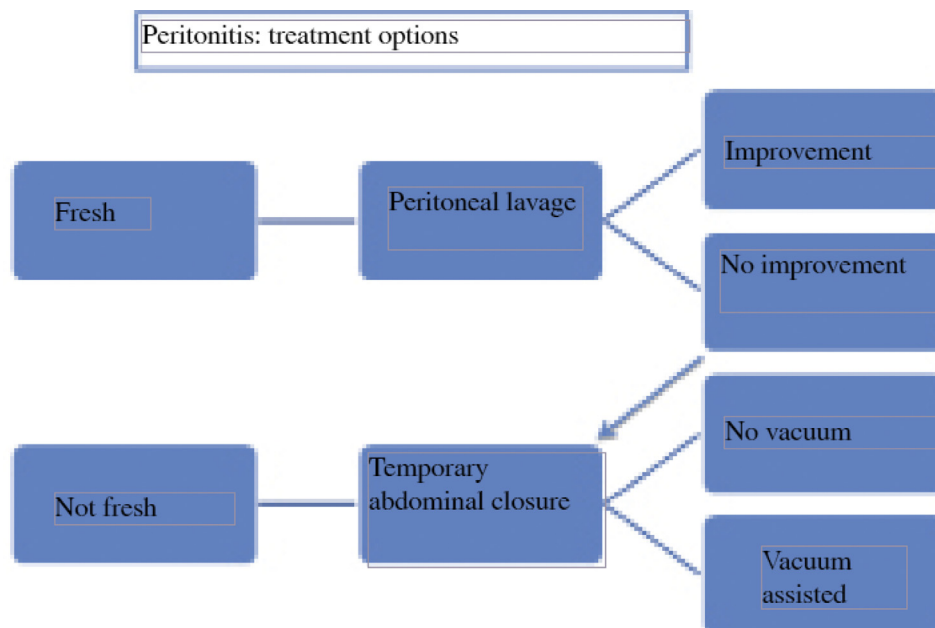


Figure 1. Peritonitis: treatment options.

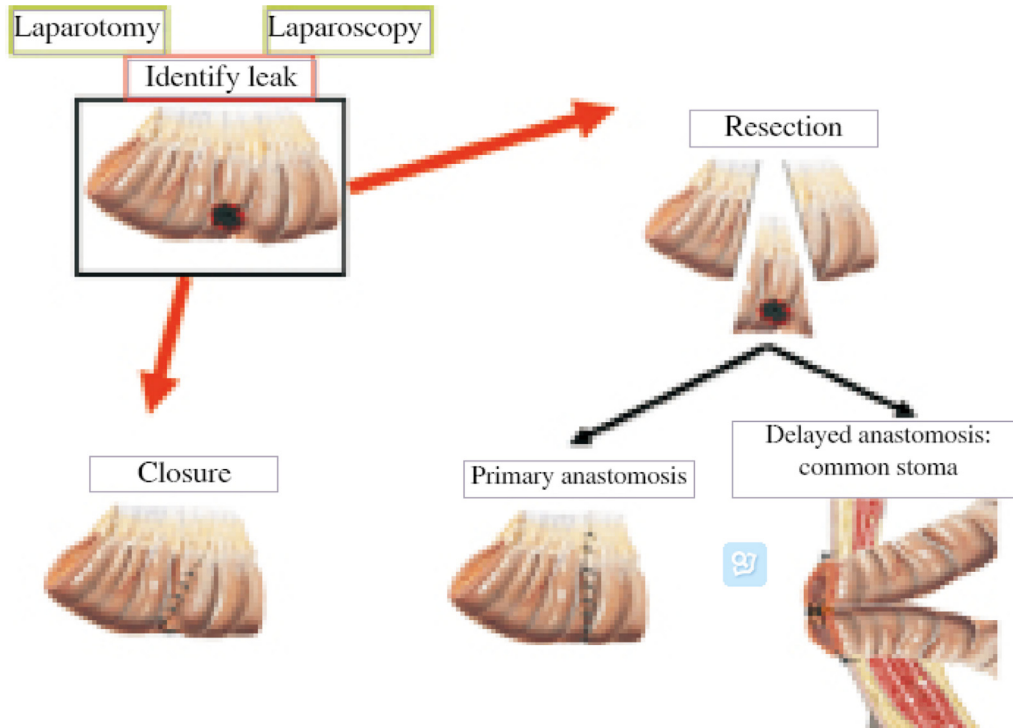


Figure 2. Small bowel perforation: surgical options.

other septic complications^[11]. It is important to develop for such patients an individual strategy together with the team of the intensive care unit. In recent years, several concepts have been developed in order to control a severe infection of the peritoneum and its consequences. Many years ago, relaparotomies for postoperative complications or sepsis were not very popular because of the high operative risk in these severely compromised patients. With the improvements in anaesthesia and intensive care, it could be shown that the risk of a relaparotomy is lower than the risk of an untreated septic

focus. The planned relaparotomy is based on the experience that for a severe purulent peritonitis, one lavage is not sufficient. Depending on the severity of the peritonitis, a relavage every day or every other day can be performed. The relaparotomy on demand is a strategy where the recovery or deterioration of the patient is the indicators for a relaparotomy.

Since a severe septic abdomen is usually combined with an abdominal compartment syndrome, a primary closure of the abdomen is not recommendable. Further relaparotomies are also easier only when a temporary closure of the abdomen is

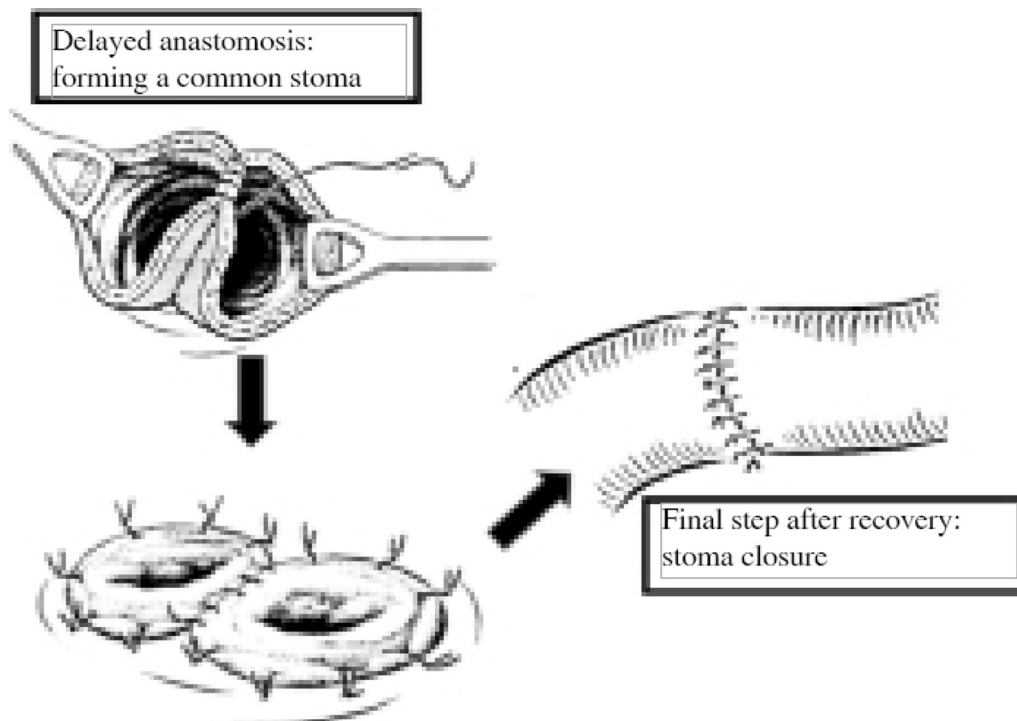


Figure 3. Double lumen common stoma sutured with mucocutaneous sutures to the skin.

performed. In recent years, several methods have been developed from simple packing, plastic bags, *etc.* In Europe, a zipper system is popular. A newer method is a vacuum assisted system with a continuous suction to collect peritoneal fluid and support the approximation of the abdominal wall. At this point, no data are available to prefer one of the different systems^[12].

Conflict of interest statement

The author reports no conflict of interest.

References

- [1] Kimchi NA, Broide E, Shapiro M, Scapa E. Non-traumatic perforation of the small intestine. Report of 13 cases and review of the literature. *Hepatogastroenterology* 2002; **49**(46): 1017-22.
- [2] Steinbach C, Stockmann M, Jara M, Bednarsch J, Lock JF. Accidentally ingested toothpicks causing severe gastrointestinal injury: a practical guideline for diagnosis and therapy based on 136 case reports. *World J Surg* 2014; **38**(2): 371-7.
- [3] Centers for Disease Control and Prevention. Gastrointestinal injuries from magnet ingestion in children: United States, 2003–2006. *Morb Mortal Wkly Rep* 2006; **55**(48): 1296-300.
- [4] van der Voort M, Heijnsdijk EA, Gouma DJ. Bowel injury as a complication of laparoscopy. *Br J Surg* 2004; **91**(10): 1253-8.
- [5] Park MH, Mehran A. Intestinal injury secondary to an umbilical piercing. *JLS* 2012; **16**(3): 485-7.
- [6] Asif A, Byers P, Vieira CF, Merrill D, Gadalean F, Bourgoignie JJ, et al. Peritoneoscopic placement of peritoneal dialysis catheter and bowel perforation: experience of an interventional nephrology program. *Am J Kidney Dis* 2003; **42**(6): 1270-4.
- [7] Abu-Hejleh T, Mezhir JJ, Goodheart MJ, Halfdanarson TR. Incidence and management of gastrointestinal perforation from bevacizumab in advanced cancers. *Curr Oncol Rep* 2012; **14**(4): 277-84.
- [8] Freeman HJ. Spontaneous free perforation of the small intestine in adults. *World J Gastroenterol* 2014; **20**(29): 9990-7.
- [9] Hines J, Rosenblat J, Duncan DR, Friedman B, Katz DS. Perforation of the mesenteric small bowel: etiologies and CT findings. *Emerg Radiol* 2013; **20**(2): 155-61.
- [10] Gupta A, Habib K, Harikrishnan A, Khetan N. Laparoscopic surgery in luminal gastrointestinal emergencies—a review of current status. *Indian J Surg* 2014; **76**(6): 436-43.
- [11] Ordoñez CA, Puyana JC. Management of peritonitis in the critically ill patient. *Surg Clin North Am* 2006; **86**(6): 1323-49.
- [12] Kirkpatrick AW, Roberts DJ, De Waele J, Jaeschke R, Malbrain ML, De Keulenaer B, et al. Intra-abdominal hypertension and the abdominal compartment syndrome: updated consensus definitions and clinical practice guidelines from the World Society of the Abdominal Compartment Syndrome. *Intensive Care Med* 2013; **39**(7): 1190-206.