



Contents lists available at ScienceDirect

Journal of Acute Disease

journal homepage: www.jadweb.org



Document heading doi: 10.1016/S2221-6189(13)60086-4

Bilateral iliopsoas haematomas

Taro Shimizu, Koichi Kitamura, Yusuke Tsuchiya, Naoki Fujiwara

Nerima Hikarigaoka Hospital, Tokyo, Japan

ARTICLE INFO

Article history:

Received 10 January 2012

Received in revised form 15 March 2012

Accepted 15 May 2012

Available online 20 November 2012

Keywords:

Bilateral

Iliopsoas

Hematomas

ABSTRACT

A 77-year-old man on warfarin therapy for persistent atrial fibrillation presented with bilateral anterior femoral pain and weakness. The pain was located in his bilateral thighs and groins. We concluded that the patient bilateral femoral pain and weakness were due to bilateral iliopsoas hematomas with anticoagulation therapy.

1. Introduction

Hemorrhage into iliopsoas muscles is an uncommon complication of anticoagulation therapy and is usually unilateral^[1]. Even more, bilateral hematomas have rarely been reported^[2,3].

2. Case report

A 77-year-old man on warfarin therapy for persistent atrial fibrillation presented with bilateral anterior femoral pain and weakness. The pain was located in his bilateral thighs and groins. The pain was more prominent in right side than in left side. On examination, his heart rate was 88 per min with atrial fibrillation, and blood pressure was 110/82. Psoas sign was positive in both sides. His hemoglobin was 11.4 g/L, platelet count was $24.9 \times 10^5/L$, prothrombin time international normalized ratio (PT-INR) was 2.54, and activated partial thromboplastin time (APTT) was 34.4 s. A magnetic resonance imaging (MRI) scan of the abdomen and pelvis revealed bilateral iliopsoas hematomas (Figure 1). He was admitted and warfarin was discontinued. His pain gradually alleviated over several days, and finally diminished. We concluded that the patient bilateral femoral pain and weakness were due to bilateral iliopsoas hematomas with anticoagulation therapy.

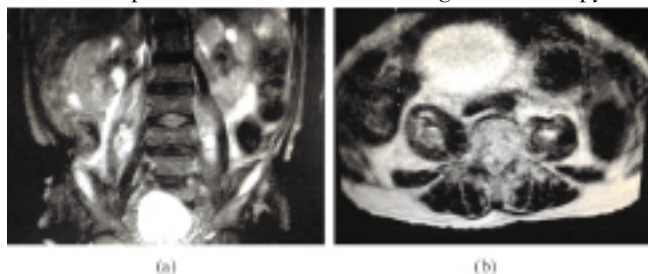


Figure 1. A magnetic resonance imaging (MRI) scan of the abdomen and pelvis revealed bilateral iliopsoas hematomas.

Patients with iliopsoas hematoma manifest a variety of symptoms, ranging from lumbar or groin pain, to lumbar plexus neuropathy or massive bleeding and shock. In our case, PT-INR was within therapeutic range when the bleeding started. In most reported cases, interestingly, iliopsoas hematomas occur even within therapeutic range. Whether or not hematomas be surgically resected remains controversial, while the first successful treatment with TAE for severe psoas hematoma due to anticoagulant therapy was recently reported^[4].

3. Discussion

Iliopsoas hematoma should be considered in any patient with anticoagulant treatment, even if APTT and PT-INR values are in the therapeutic anticoagulation range.

TAE might be a good therapeutic option for the bilateral iliopsoas muscle in addition to conservative and surgical treatment.

Conflict of interest statement

The authors declare that there are no conflicts of interest.

References

- [1] Sasson Z, Mangat I, Peckham KA. Spontaneous iliopsoas hematoma in patients with unstable coronary syndromes receiving intravenous heparin in therapeutic doses. *Can J Cardiol* 1996; **12**: 490–494.
- [2] Storen EJ. Bilateral iliopsoas haematoma with femoral nerve palsy complicating anticoagulant therapy. *Acta Chir Scand* 1978; **144**: 181–183.
- [3] Jamjoom ZA, al-Bakry A, al-Momen A, Malabary T, Tahan AR, Yacub B. Bilateral femoral nerve compression by iliopsoas hematomas complicating anticoagulant therapy. *Surg Today* 1993; **23**: 535–540.
- [4] Qanadli SD, EI Hajjam, Mignon F, Bruckert F, Chagnon S, Lacombe P. Life-threatening spontaneous psoas haematoma treated by transcatheter arterial embolization. *Eur Radiol* 1999; **9**: 1231–1234.

*Corresponding author: Taro Shimizu, Nerima Hikarigaoka Hospital, Tokyo, Japan.
E-mail: shimizutaro7@gmail.com