



Contents lists available at ScienceDirect

Journal of Acute Disease

journal homepage: www.jadweb.org

Document heading doi: 10.1016/S2221-6189(13)60079-7

Pellet in the stomach: Where did it come from?

Baris Dogu Yildiz¹, Barlas Sulu²¹Ankara Numune Teaching Hospital, General Surgery, Ankara, Turkey²Kafkas University Faculty of Medicine, General Surgery, Pasacayiri 36100, Kars, Turkey

ARTICLE INFO

Article history:

Received 5 February 2012

Received in revised form 20 February 2012

Accepted 3 March 2012

Available online 20 November 2012

ABSTRACT

Gunshot might have unexpected findings in the victim owing to the ballistics of the injury. The trajectory of the bullet plays a central role in the surprising findings in gunshot injuries. We are presenting a case with pellets seen in the stomach after a gunshot.

Keywords:

Gunshot wound

Abdomen

Non operative management

Computed tomography

Trajectory

1. Introduction

It is estimated that each year in United States there are approximately 70 000 gunshot victims[1]. Defining the trajectory, entrance and exit of the bullet is one of the first steps in evaluating a gunshot wound. There are cases of pellet migration to central nervous system[2], to peripheral arteries[3], and even in to the ureter[4].

2. Case report

47 years old male patient presented to the emergency department after a gunshot injury. The injury was aimed at his left shoulder. The patient was conscious; his pulse, blood pressure and respiration rate were 90/min, 92/55

mmHg, 30/min respectively at the initial presentation.

In physical examination there had been multiple pellet wounds around the shoulder, neck, thoracic wall and left arm (Figure 1). The patient had subcutaneous emphysema and the breath sounds were decreased on the left hemithorax. There were no pathological findings on abdominal examination.

His hemoglobin level was 14.1 g/dL and the leukocyte count was 14 200 / μ L. There was a slight elevation in liver enzymes but there were not any other findings in blood biochemistry.

The radiographic examination revealed multiple segmented fractures in left humerus and scapula and the cervical X-ray showed pellets around the neck. The computed tomography (CT) of the thorax revealed a defect in the anterior part of the trachea (Figure 2) and paranchymal lung injury besides pneumothorax. There were pellets around the pericardium and a pellet in stomach was also recognized in CT (Figure 3).

When questioned further, the patient remembered that he coughed pellets among with blood and phlegm and he swallowed them.

*Corresponding author: Baris Dogu Yildiz, MD. Ankara Numune Teaching Hospital, General Surgery, Ankara, Turkey.
Tel: 90-312-439 48 44
Fax: 90-312-424 15 20
E-mail: baris104@yahoo.com

A chest tube was inserted to the left hemithorax and the follow up was uneventful thereafter. Oral feeding was started on the second day and the patient was discharged 1 week after admission.

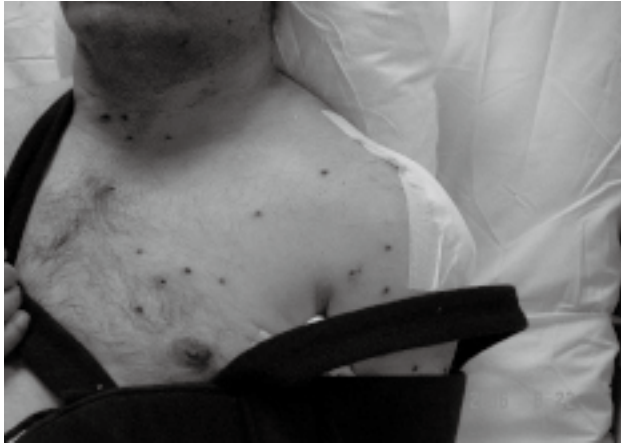


Figure 1. The patient with multiple pellet wounds.

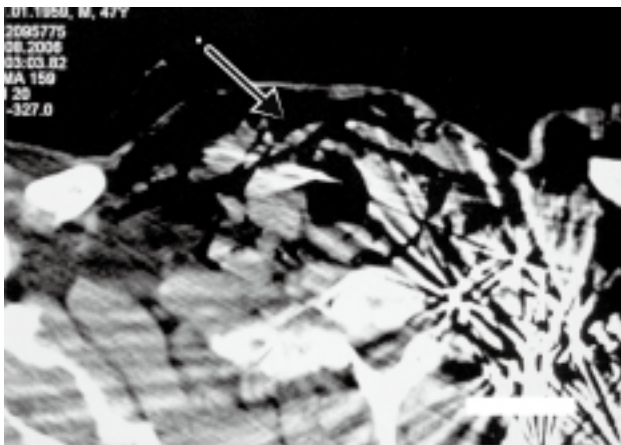


Figure 2. The black arrow shows the defect on trachea.

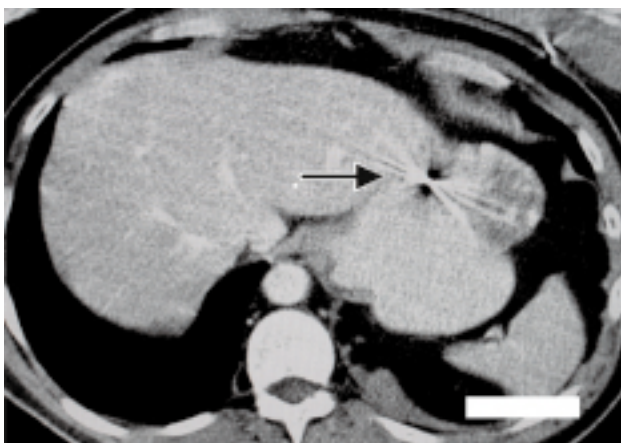


Figure 3. The black arrow shows the shining pellet inside gastric lumen.

3. Discussion

The difficulty in determining the trajectory in

thoracoabdominal area is caused by the motion of the diaphragm[5]. Although laparotomy is gold standart in management of abdominal wounds there are reports which support non-operative treatment in selected cases[6,7]. In our case, determination of the pellet in the stomach by the computed tomography caused us anxiety at first. We thought one of the pellets traversed thorax, diaphragm, gastric wall and ended up inside gastric lumen. Then considering the injury around the trachea we hypothesized that pellets moved to the patients mouth upon coughing and got swallowed. As the patient did not have any abdominal findings, he was managed non-operatively.

History and physical examination are still the major tools in patient management despite the technical improvements in radiology. Because of the ballistics of the weapons, the surgeon could deal with unexpected presentations[8]. Pellets may travel in every direction. Close patient follow-up is important both in decision making and management. Radiologists and surgeons should be cautious in interpreting the CT findings of gunshot patients.

Conflict of interest

We declare that we have no conflict of interest.

References

- [1] Denton JS, Segovia A, Filkins JA. Practical pathology of gunshot wounds. *Arch Pathol Lab Med* 2006; **130**: 1283–1289.
- [2] David W, Odeh Y, Mittal V. Shotgun pellet embolus to the middle cerebral artery: Case report. *J Trauma* 2003; **54**: 417.
- [3] Morales JM, Patel SG, Monarrez C, Saldehar A, Simpson JW. Air pellet embolization after penetrating cardiac injury. *J Trauma* 2000; **49**: 774–775.
- [4] Lojanapiwat B, Sripralakit S, Soonthornpun S, Wudhikarn S. Ureteric obstruction by shotgun pellet “pellet colic”. *J Med Assoc Thai* 1999; **82**(10): 1048–1050.
- [5] Pryor JP, Reilly PM, Dabrowski GP, Grossman MD, Schwab CW. Nonoperative management of abdominal gunshot wounds. *Ann Emerg Med* 2004; **43**: 344–353.
- [6] Saadia R, Degiannis E. Non-operative treatment of abdominal gunshot injuries. *Br J Surg* 2000; **87**(4): 393–397.
- [7] Oshodi TO, Bowrey D. Uncomplicated penetrating colonic injury. *J Accid Emerg Med* 1996; **13**(4): 296–297.
- [8] Volgas DA, Stannard JP, Alonso JE. Ballistics: a primer for the surgeon. *Injury* 2005; **36**: 373–379.