



Contents lists available at ScienceDirect

Journal of Acute Disease

journal homepage: www.jadweb.org



Document heading doi: 10.1016/S2221-6189(14)60019-6

## Stromal opacity secondary to preservative in dilating drops – A case report and review of literature

Madhusudhan, Evelyn–Tai LM, Ishak Siti–Raihan\*, Wan Hazabbah WH

Department of Ophthalmology, School of Medical Sciences, Universiti Sains Malaysia, Health Campus, 16150 Kubang Kerian, Kelantan, Malaysia

### ARTICLE INFO

#### Article history:

Received 4 September 2013

Received in revised form 29 September 2013

Accepted 22 October 2013

Available online 20 March 2014

#### Keywords:

Benzalkonium compounds

Drug toxicity

Stromal opacity

Corneal edema

Tropicamide

### ABSTRACT

This patient is a 64-year-old man who presented with painless progressive blurring of vision for one year. After a routine fundoscopy preceded by dilatation of both eyes with a drop of topical tropicamide, the left eye was noted to have stromal edema temporally. This was attributed to the preservative (BAC) in the medication. The stromal oedema persisted over the following weeks despite administration of a topical steroid, and was associated with deterioration in visual acuity to 6/30 (PH 6/21). This case reminds us that clinicians should be vigilant during instillation of any preservative-containing drops, even in routine practices like dilatation. Far from being restricted to chronic use of preservative-containing drugs, toxicity with BAC can occur even upon a single application. Ideally, all eyedrops should be single-use topical drug formulations, but in the absence of this option, it is imperative that ophthalmic drug prescription be done with adequate clinical justification.

## 1. Introduction

Preservatives in ophthalmic solutions have long been known to cause toxic effects on the cornea. The most frequently used preservative in eye drops, and one that has among the highest toxicity, is benzalkonium chloride (BAC)<sup>[1–3]</sup>. This quaternary ammonium has been shown to have a variety of pathological effects, including tear film instability, conjunctival squamous metaplasia, breakdown of conjunctival immunological tolerance and cytotoxicity of corneal epithelial, stromal, and endothelial cells<sup>[4–7]</sup>.

Clinically, use of BAC may cause dry eyes, red eyes, itchy eyes, photophobia, and other signs of ocular irritation<sup>[8]</sup>. Consequences of the use of these

preservatives in the eye have included chronic inflammation and hypersensitivity reactions like cicatricial pemphigoid and Steven–Johnson's syndrome<sup>[2,7,9]</sup>. BAC plays an important role in ocular surface damage, especially as its effects are dose- and time-dependent<sup>[4,8]</sup>.

In our unusual finding, the patient developed stromal opacity almost immediately after one instillation of topical tropicamide containing benzalkonium chloride, and to the best of our knowledge, this is the first reported case of such a condition.

## 2. Case presentation

A 64-year-old Malay gentleman presented to our clinic for painless progressive blurring of vision for the past 1 year. He was afflicted with poorly-controlled diabetes mellitus and hypertensive heart disease, under medical follow-up in our centre. On examination, the

\*Corresponding author: Siti Raihan Ishak, Department of Ophthalmology, School of Medical Sciences, Universiti Sains Malaysia, Health Campus, 16150 Kubang Kerian, Kelantan, Malaysia.

Fax: 09-7653370

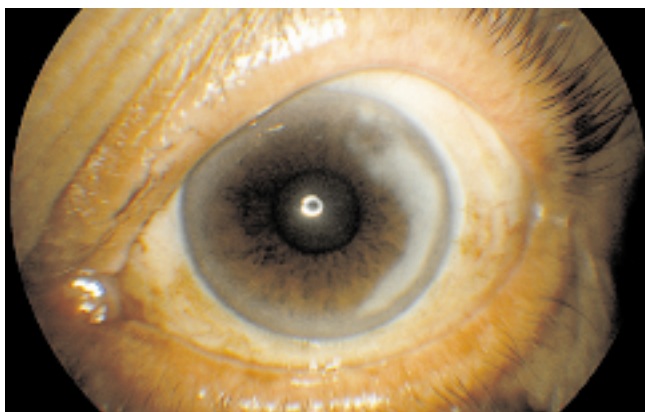
E-mail: citiey1974@gmail.com

vision in his right eye was 6/60 (PH 6/60), while that of the left eye was 6/15 (PH 6/12). He was noted to have bilateral cataract, which was more dense on the right than the left. The right eye showed posterior subcapsular cataract 2+ and nuclear sclerosis 2+, while the left had nuclear sclerosis 2+.

The remainder of the anterior segment examination was unremarkable. Intraocular pressure was within normal limits. We proceeded with a routine fundus examination, which was preceded by dilatation of both eyes with topical tropicamide. On fundoscopy, the optic disc in both eyes was pink, with a cup–disc–ratio of 0.3. There was no evidence of retinopathy.

Unfortunately, after dilatation, it was noted that the left eye had developed stromal edema temporally, extending from 2–5 o'clock and radiating towards the central visual axis. This was attributed to the preservative (benzalkonium chloride) in the topical tropicamide, as no other topical eyedrops had been administered during examination. Patient was reviewed again 2 weeks later, but there was no improvement of the left eye stromal oedema. Providentially, there was no impairment of his visual acuity, which remained static at 6/15 (PH 6/12). He was started on topical predforte 1.2% 6 hourly and preservative–free artificial tears 4 hourly.

On subsequent weekly follow up, the stromal oedema persisted, and sadly, his left eye visual acuity had now deteriorated to 6/30 (PH 6/21). Specular microscopy was performed; his right eye had an endothelial cell count of 2210 cells/mm<sup>2</sup>, while that of the left was 2 041 cells/mm<sup>2</sup>. On our latest examination at 4 months after his first visit, the area of stromal oedema remained the same. Currently, he is being maintained only on preservative–free artificial tears 4 hourly, and is planned for right eye phacoemulsification with posterior chamber intraocular lens implantation.



**Figure 1.** Anterior segment photograph showing stromal opacity in paracentral area of left cornea.

### 3. Discussion

Benzalkonium chloride is the most widely used preservative in ophthalmological solutions. With a wealth of literature testifying to the deleterious effects of this substance on the ocular surface, there is yet no denying the equally important advantages to be gained by its use. Messmer et al stated that preservatives are a legal requirement for eye drops in multidose containers<sup>[1]</sup>. Besides their role in stabilization and preservation of ophthalmic preparations<sup>[1,10]</sup>, they also enhance intraocular penetration of drugs<sup>[11,12]</sup>.

On the downside, this effect on corneal permeability has been correlated with electrophysiological changes of the corneal tissue, which may be indicative of epithelial toxicity<sup>[12]</sup>. Besides that, benzalkonium chloride has also been reported to impair induction of immune tolerance in a murine model, thus resulting in breakdown of immune balance of the conjunctiva<sup>[7]</sup>.

Across the board, there have been many instances of benzalkonium chloride toxicity. When used as a preservative in contact lens disinfecting solutions, benzalkonium chloride (BAC) has been reported to cause anterior chamber inflammation in a patient post extracapsular cataract extraction<sup>[13]</sup>. In another study of previously untreated patients with ocular hypertension who were given a short–term course of BAC–preserved timolol in one eye and preservative–free timolol in the other, this induction of anterior chamber inflammation was likewise demonstrated in the BAC–treated eyes<sup>[14]</sup>. On a different level, cytotoxicity of BAC on conjunctival and corneal epithelial cells has also been demonstrated, both *in vitro* and *in vivo*<sup>[15–17]</sup>.

Paradoxically, our patient neither had intraocular inflammation or epitheliopathy; in his case, the BAC–related toxicity took the form of a corneal decompensation–like picture, in which he developed stromal edema despite the presence of a normal endothelial cell count.

The circumstances under which this condition occurred render this case especially intriguing, as despite his medical comorbidities, this unfortunate gentleman had no underlying ocular disease apart from the normal age–related cataract. Ironically, he developed a persistent visual impairment secondary to stromal edema in the less cataractous eye, which can be directly attributed to the effect of the BAC–preserved dilating drops. As far as we know, there have been no reports of a similar

occurrence of stromal oedema secondary to BAC, and the pathophysiology of this phenomenon still remains elusive.

Our case provides additional evidence that clinicians should be vigilant during instillation of any preservative-containing ophthalmic solution, even in apparently routine practices like dilatation.

#### Learning points:

- Far from being restricted to chronic use of preservative-containing drugs, toxicity with BAC can occur even upon a single application, as demonstrated in this patient.

- Measures to reduce the risk of potential toxicity with BAC include using a small drop size or a less toxic alternative to BAC, especially in patients who require high doses or long duration of topical ophthalmic medication.

- Ideally, all preservatives should be avoided where single-use topical drug formulations are available. In the absence of this option, it is imperative that ophthalmic drug prescription be done with adequate clinical justification.

#### Conflict of interest statement

We declare that we have no conflict of interest

#### References

- [1] Messmer EM. Preservatives in ophthalmology. *Ophthalmologe* 2012; **109**(11): 1064–1070.
- [2] Hong J, Bielory L. Allergy to ophthalmic preservatives. *Curr Opin Allergy Clin Immunol* 2009; **9**(5): 447–453.
- [3] Epstein SP, Ahdoot M, Marcus E, Asbell PA. Comparative toxicity of preservatives on immortalized corneal and conjunctival epithelial cells. *J Ocular Pharmacol Ther* 2009; **25**(2): 113–119.
- [4] Baudouin C, Labbe A, Liang H, Pauly A, Brignole-Baudouin F. Preservatives in eyedrops: the good, the bad and the ugly. *Progress Retinal Eye Res* 2010; **29**(4): 312–334.
- [5] Huber-van der Velden KK, Thieme H, Eichhorn M. Morphological alterations induced by preservatives in eye

- drops. *Ophthalmologe* 2012; **109**(11): 1077–1081.
- [6] Hughes EH, Pretorius M, Eleftheriadis H, Liu CS. Long-term recovery of the human corneal endothelium after toxic injury by benzalkonium chloride. *Br J Ophthalmol* 2007; **91**(11): 1460–1463.
- [7] Galletti JG, Gabelloni ML, Morande PE, Sabbione F, Vermeulen ME, Trevani AS, et al. Benzalkonium chloride breaks down conjunctival immunological tolerance in a murine model. *Mucosal Immunol* 2013; **6**(1): 24–34.
- [8] Ouyang PB, Duan XC. Ocular surface injury resulted from topical anti-glaucoma medications: prevention and cure. *Chin J Ophthalmol* 2012; **48**(6): 557–561.
- [9] Chiambaretta F, Pouliquen P, Rigal D. Allergy and preservatives. Apropos of 3 cases of allergy to benzalkonium chloride. *J francais d'ophtalmologie* 1997; **20**(1): 8–16.
- [10] Kaur IP, Lal S, Rana C, Kakkar S, Singh H. Ocular preservatives: associated risks and newer options. *Cutaneous Ocular Toxicol* 2009; **28**(3): 93–103.
- [11] Okabe K, Kimura H, Okabe J, Kato A, Shimizu H, Ueda T, et al. Effect of benzalkonium chloride on transscleral drug delivery. *Invest Ophthalmol Visual Sci* 2005; **46**(2): 703–708.
- [12] Chetoni P, Burgalassi S, Monti D, Saettone MF. Ocular toxicity of some corneal penetration enhancers evaluated by electrophysiology measurements on isolated rabbit corneas. *Toxicol In Vitro* 2003; **17**(4): 497–504.
- [13] Gasset AR. Benzalkonium chloride toxicity to the human cornea. *Am J Ophthalmol* 1977; **84**(2): 169–171.
- [14] Stevens AM, Kestelyn PA, De Bacquer D, Kestelyn PG. Benzalkonium chloride induces anterior chamber inflammation in previously untreated patients with ocular hypertension as measured by flare meter: a randomized clinical trial. *Acta ophthalmologica* 2012; **90**(3): e221–e224.
- [15] Ammar DA, Noecker RJ, Kahook MY. Effects of benzalkonium chloride-preserved, polyquad-preserved, and sofZia-preserved topical glaucoma medications on human ocular epithelial cells. *Adv Ther* 2010; **27**(11): 837–845.
- [16] Brignole-Baudouin F, Riancho L, Liang H, Nakib Z, Baudouin C. *In vitro* comparative toxicology of polyquad-preserved and benzalkonium chloride-preserved travoprost/timolol fixed combination and latanoprost/timolol fixed combination. *J Ocular Pharmacol Ther* 2011; **27**(3): 273–280.
- [17] Pellinen P, Huhtala A, Tolonen A, Lokkila J, Maenpaa J, Uusitalo H. The cytotoxic effects of preserved and preservative-free prostaglandin analogs on human corneal and conjunctival epithelium *in vitro* and the distribution of benzalkonium chloride homologs in ocular surface tissues *in vivo*. *Curr Eye Res* 2012; **37**(2): 145–154.