



Contents lists available at ScienceDirect

Journal of Acute Disease

journal homepage: www.jadweb.org



Document heading doi: 10.1016/S2221-6189(13)60120-1

Tick in the outer ear canal: Two case reports

Özalkan Özkan^{1*}, Fatih Bingöl², Ali Budak²

¹Hınıs Şehit Yavuz Yürekseven Hospital, Department of Otorhinolaryngology, Erzurum, Turkey

²Education and Training Hospital, Department of Otorhinolaryngology, Erzurum, Turkey

ARTICLE INFO

Article history:

Received 2 March 2013

Received in revised form 15 March 2013

Accepted 20 March 2013

Available online 20 June 2013

Keywords:

Tick

Endoscopy

Outer ear canal

ABSTRACT

Serious systemic diseases such as Crimean Congo Hemorrhagic Fever, Lyme Disease, tularemia, typhus and Q fever can be transmitted by ticks. An 8-year-old boy and a 34-year-old woman were brought to our clinic with ear pains. No symptoms such as fever, headache or lethargy to suggest CCHF were present. The patients both lived in rural areas and were engaged in farming. Full blood count, liver and kidney function tests and serum electrolytes were within normal limits at laboratory tests. Prothrombin time, partial thromboplastin time and INR were normal. The tick was grasped with alligator forceps and removed from the outer ear in one piece with the help of 0-degree rigid otoendoscopy.

1. Introduction

Although cases of foreign bodies in the outer ear canal are common in Ear, Nose and Throat clinics, cases of ticks in the outer ear canal are comparatively rare[1,2]. As of the 2000s, ticks have come to prominence as transmitters to humans of several diseases with poor prognosis, and particularly crimean congo hemorrhagic fever (CCHF). Ticks are non-flying and non-jumping ectoparasites that feed on blood and can infect all terrestrial vertebrates[3]. Other associated significant systemic diseases apart from CCHF are Lyme disease (*Borrelia burgdorferi*), tularemia (*Francisella tularensis*), typhus (*Rickettsia conorii*) and Q fever (*Coxiella burnetii*)[4]. Transmission of CCHF is directly proportional to the length of time the tick remains in the body, and mortality ranges between 3% and 30%[5].

The purpose of this paper was to discuss methods of

removing ticks that enter the outer ear canal and what can be done at follow-up.

2. Case report

2.1. Case 1

A 34-year-old woman presented to our clinic with itching, the sensation of the presence of a moving foreign body and mild pain in the ear. There were no symptoms such as fever, headache or lethargy to suggest CCHF. We learned that she lived in a rural area and was engaged in farming. Examination of the outer ear canal revealed a tick adhering to the posterior part of the left outer ear passage (Figure 1). The patient had no other systemic or local finding. Family members had no similar symptoms. Full blood count, liver and kidney function tests and serum electrolytes were within normal limits at laboratory tests. Prothrombin time, partial thromboplastin time and INR were normal. The tick was grasped with alligator forceps and carefully removed from the outer ear in one

*Corresponding author: Dr. Özalkan Özkan, Hınıs Şehit Yavuz Yürekseven Hospital, Department of Otorhinolaryngology, Erzurum, Turkey.
Tel: 04425111530
Fax: 04422361301
E-mail: ozalkanozkan@gmail.com

piece with the help of 0-degree rigid otoendoscopy. The patient was monitored on an out-patient basis for 2 weeks and no problems were encountered.

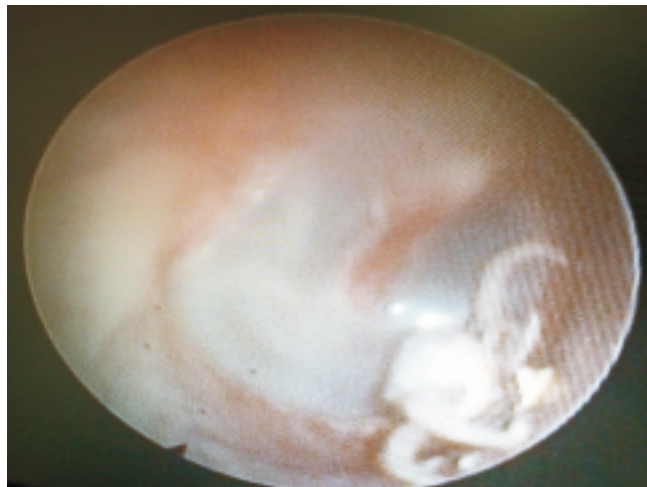


Figure 1. Examination of the outer ear canal revealed a tick adhering to the posterior part of the left outer ear passage.

2.2. Case 2

An 8-year-old male presented to our clinic with severe pain in the left ear. No symptoms such as fever, headache or lethargy to suggest CCHF were present. The patient lived in a village and belonged to a farming family. Outer ear canal examination revealed a tick attached to the upper posterior quadrant of the left tympanic membrane (Figure 2).

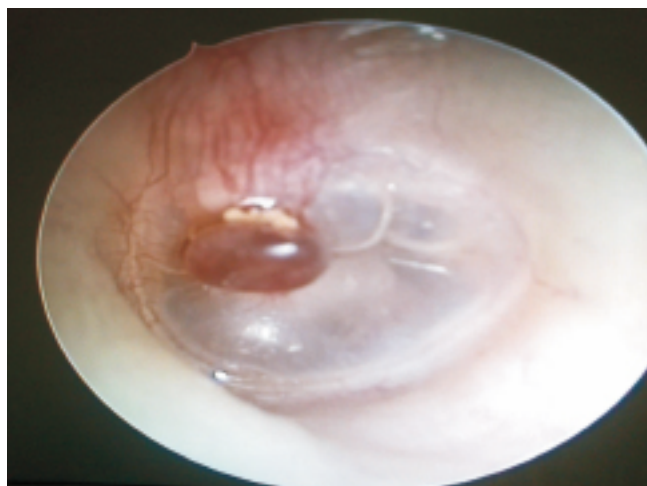


Figure 2. Outer ear canal examination revealed a tick attached to the upper posterior quadrant of the left tympanic membrane.

The patient had no other systemic or local finding. Family members had no similar symptoms. Full blood count, liver and kidney function tests and serum electrolytes were within normal limits at laboratory tests. Prothrombin time, partial thromboplastin time and INR

were normal. The tick was grasped with alligator forceps and carefully removed from the outer ear alive and in one piece with the help of 0-degree rigid otoendoscopy. The canal was later aspirated with batticon antiseptic solution. The patient and his family were informed about disease. The patient was monitored on an out-patient basis for 2 weeks and no problems were encountered.

3. Discussion

Foreign bodies in the outer ear canal generally consist of objects such as fruit seeds and nuts, beads or parts of toys, although living objects such as flies, insects and larvae deposited by these can also be seen^[6].

The ticks that enter the outer ear canal are blood-sucking arthropods found in all continents of the world. As ticks suck blood, they insert various mouth organelles into the skin, attach themselves there and suck blood from the same location until satiated^[7]. At time of biting, ticks release anesthetic, anti-inflammatory, anti-hemostatic and immunomodulator substances. Their bites are therefore generally asymptomatic. Symptoms generally consist of red papules caused by hypersensitivity or foreign body reaction^[8]. Itching, mild pain and the sensation of a moving foreign body were present in our first case, and severe pain in the ear in the second.

Leukopenia and thrombocytopenia are prominent in CCHF, and must be tested for in tick bites with hemograms, hepatic enzymes and bleeding diathesis. This is because a rise takes place in the enzymes alanine aminotransferase, aspartate aminotransferase, creatinine kinase and lactate dehydrogenase. Clotting tests are negatively affected. The first two weeks are important in the manifestation and monitoring of the disease^[9]. Following tick bite, the disease may begin with lethargy, lack of appetite, fever, headache and severe pain in the arms and legs. Nausea, vomiting and stomach ache may also be seen. Areas of bleeding in the form of reddening in the eyes and petechiae-purpura appear in the first days. Multiorgan failure with involvement of the kidney and lungs, in addition to hepatic involvement, may develop in advanced cases^[10]. No symptoms such as fever, headache or lethargy to suggest CCHF were present in our cases. At laboratory tests, full blood count, liver function tests, prothrombin time, partial thromboplastin time and INR were all normal. CCHF did not develop.

Otomicroscopy is classically used to determine the location of a blood-sucking tick in the outer ear canal. The use of rigid endoscopy to remove foreign bodies from the outer ear canal is reported to have become more

widespread in recent years and to be more practical^[11]. We used 0 degree rigid otoendoscopy in our cases.

The literature recommends that once the location of the tick has been established it should be extracted as quickly as possible with forceps, without crushing it or breaking off the mouth parts^[12]. In removing a tick from the outer ear canal, chemicals such as alcohol that might cause the organism to vomit and release its secretions should not be used^[1]. The tick should not be squeezed from the sides. It should be gripped from close to the bite site and removed upwards without force using fine tipped forceps^[13]. We did not use alcohol in our cases. We removed the ticks by gripping the head with alligator forceps and pulling upward from the point of attachment. Using that technique, no tick secretions came into contact with the patients. The ticks were safely removed from the body using this technique, even though they were not carrying the CCHF virus.

In conclusion, we think that the best course is for ticks attaching to the outer ear canal to be visualized using 0 degree rigid endoscopy and to be removed in an upward direction from the point of attachment using such devices as alligator forceps.

Conflict of interest

The authors declare they have no conflict of interests.

References

[1] Iwasaki S, Takebayashi S, Watanabe T. Tick bites in the external auditory canal. *Auris Nasus Larynx* 2007; **34**: 375–

- 377.
- [2] Singh GB, Sidhu TS, Sharma A, Dhawan R, Jha SK, Singh N. Management of aural foreign body: an evaluative study in 738 consecutive cases. *Am J Otolaryngol* 2007; **28**: 87–90.
- [3] Tanır G, Ozgelen S, Tuygun N. Biological features of tick-borne diseases and epidemiological investigation and evaluation in Turkey. *J Pediatr Infect* 2008; **3**(3): 117–123.
- [4] Kara A. Tick removal. *Türk Pediatr J* 2008; **51**(4): 117–122.
- [5] Ergönül O. Crimean–Congo haemorrhagic fever. *Lancet Infect Dis* 2006; **6**(4): 203–214.
- [6] Erpek MG, Yorgancıoğlu A, Çelik P. Kulak yabancı cisimleri. In: Çelik O, editor. *Kulak burun boğaz hastalıkları ve baş boyun cerrahisi. 1. baskı*. İstanbul: Turgut Yayıncılık; 2002, p. 985–995.
- [7] Vincent MJ, Sanchez AJ, Erickson BR, Başak A, Chretien M, Seidah NG, et al. Crimean–congo hemorrhagic fever virus glycoprotein proteolytic processing by subtilase SKI–1. *Soc Microbiol J Virol* 2003; **77**: 8640–8649.
- [8] Ribeiro JM, Francischetti IM. Role of arthropod saliva in blood feeding: sialome and post sialome perspectives. *Annu Rev Entomol* 2003; **48**: 73–78
- [9] Whitehouse CA. Crimean–Congo haemorrhagic fever. *Antiviral Res* 2004; **64**(3): 145–160.
- [10] Khan AS, Ksiazek TG, Peters CJ. Viral haemorrhagic fevers. *Semin Pediatr Infect Dis* 1997; **8**(1): 64–73.
- [11] Thompson SK, Wein RO, Dutcher PO. External auditory canal foreign body removal: management practices and outcomes. *Laryngoscope* 2003; **113**(11): 1912–1915.
- [12] Gündüz A, Türedi S, Aydın, Eroğlu O, Topbaş M, Kene ısırması. *Kor Hek* 2008; **7**(2): 173–178.
- [13] Görgülü O, Özdemir S, Selçuk T, Canbolat EP, Akbaş Y. Dış kulak yolundan kene ısırıklarında tedavi. *Türkiye Klinikleri J Med Sci* 2012; **32**(3): 827–381.

Professor Faran Bokhari visited Hainan Medical College & Editorial Office of JAD

Recently, Professor Faran Bokhari (Chicago Trauma Center) visited Hainan Medical College & Editorial Office of JAD for one week and gave some lectures. Both two sides wish to build Emergency and Trauma College, establish long-term care system to improve the quality, and promote school students and nursing education. Professor Faran Bokhari gives some important suggestions towards *Journal of Acute Disease* (ISSN 2221–6189).