



Contents lists available at ScienceDirect

Journal of Acute Disease

journal homepage: www.jadweb.org



Document heading doi: 10.1016/S2221-6189(13)60048-7

Diagnosis of acute surgical abdomen – The best diagnostic tool to reach a final diagnosis

Wong CS^{1*}, Al-Ajami AK², Boshahri M¹, Naqvi SA¹¹Department of Surgery, University Hospital Limerick, Dooradoyle, Co. Limerick, Ireland²Royal College of Surgeons in Ireland, Dublin, Ireland

ARTICLE INFO

Article history:

Received 1 October 2011

Received in revised form 1 December 2011

Accepted 2 January 2012

Available online 20 February 2012

Keywords:

Acute
Surgical abdomen
Diagnosis

ABSTRACT

Objective: To evaluate the best diagnostic tool (clinical, radiological, laboratory, or endoscopy) used to reach a final diagnosis of four most common presentations of acute abdomen to the surgical unit in the Limerick University Hospital, Limerick, Ireland. **Methods:** Data was analyzed retrospectively of prospective collected data of all patients who had been admitted at a single academic institution from July 2011 till September 2011. Radiology, operating theatre and histopathology, haematology and endoscopy databases were searched from the Hospital Inpatient Enquiry (HIPE) department for patients who had presented with acute abdominal pain. Patients' charts were searched manually and final diagnosis of each patient was recorded. **Results:** Out of 30 confirmed final diagnosis of appendicitis or appendicular mass, 9/30 (30.0%) were diagnosed with radiological (either on ultrasonography or CT scan). The remaining 21 cases (70.0%) were diagnosed clinically. Majority cases of diverticulitis 16/22 (72.7%) was diagnosed radiologically compared to only 6/22 (27.3%) of those confirmed by endoscopy. All diagnosis of gallstone-related diseases (cholecystitis, biliary colic, or cholelithiasis and/or choledocholithiasis) and bowel obstruction were confirmed by radiological investigation. **Conclusions:** Appendicitis can be accurately diagnosed clinically based on history and clinical examination alone. Diagnosis of diverticular disease, gallstone disease, and bowel obstruction further requires radiology intervention to confirm the provisional diagnosis.

1. Introduction

Acute abdomen is a group of acute life-threatening intra-abdominal condition that requires emergency hospital admission and often emergency surgical intervention within 24 h of duration. In general overview, appendicitis, diverticular disease, biliary disorders and intestinal disorders are common acute abdominal emergencies encountered by a general surgeon on acute take. Appendectomy is the commonest emergency surgical operation. It accounts for approximately 20/100 000 population on average yearly in Ireland from 1979–1982[1].

Early diagnosis and management of the common causes of acute abdominal pain is important to prevent potentially fatal conditions in these patients. Frequently, diagnosis of the majority of cases derived from the history and clinical examination alone. For example, the vast majority of patients with acute appendicitis present with marked localized pain and tenderness in the right iliac fossa (RIF).

It is often that provisional diagnosis supported by laboratory and imaging such as X-rays, ultrasonography (US), and CT-scan to complete or confirmed our diagnosis. Therefore, it is not uncommon to have more than one modality of investigation used to reach a final diagnosis.

The most readily available and less invasive tools are often employed as a first line investigation to rule out other differential diagnosis of any condition. They should be considered systematically under the following headings: Urine tests, Blood tests, and Radiological Imaging and Endoscopy. This is to ensure cost-effective investigations are in place and to avoid unnecessary radiation exposure when a clear-cut clinical diagnosis can be achieved.

Our aim in this study is to determine the best modalities of investigation performed to reach a final diagnosis of four most common non-traumatic cases of acute abdomen pain encountered in one of the busiest surgical referral centers at mid-west region in Ireland.

2. Materials and methods

We performed a retrospective study on a prospective

*Corresponding author: Dr Michael Wong, Department of Surgery, University Hospital Limerick, Dooradoyle, Co. Limerick, Ireland.
E-mail: cswmichael@yahoo.co.uk

collected data to determine the best diagnostic tools to achieve the final diagnosis of the four most common cases of acute abdomen. In our surgical unit, there were acute appendicitis, diverticular disease, gallstones related disorder (acute cholecystitis and biliary colic) and bowel obstruction. Patients' records were enquired from the Hospital Inpatient Enquiry (HIPE) department. Those who presented and admitted from Emergency Department (ED) with a provisional diagnosis of either any of those four conditions from July 2011 to September 2011 were recorded. Radiology, operating theatre, haematology and endoscopy databases for each individual patient were manually searched by one author (MB). Both provisional and final diagnosis were documented, compared and calculated as clinical accuracy in sensitivity.

3. Results

A total of 123 patients included in the study which was further divided into appendicular group; diverticular group; gallbladder groups; and bowel obstruction group. Appendicular was the largest group with 49 patients, followed by 22 patients in diverticular group, 24 patients in gallbladder group, and 28 patients in the bowel obstruction group. Out of the total of 49 patients with appendicitis as provisional diagnosis in the appendix group, almost half of them 42.9% (21/49) were diagnosed clinically confirmed appendicitis on laparoscopy and/or laparoscopic appendicectomy. The remaining 9 patients had also appendicitis but confirmed as final diagnosis on radiological investigation i.e. on ultrasound abdomen (in 3 patients) and CT abdomen and pelvis (in 6 patients). The sensitivity of clinical accuracy was calculated as 16.7% on ultrasonography examination, 75.0% on CT scan and 91.3% on clinical group (95% CI, 70.5% and 98.5%). This suggests

that a negative laparoscopy and/or appendicectomy on suspected appendicitis was low during this period of study. Although, 72.7% (16/22) of diverticulitis was diagnosed radiologically compared to 27.3% (6/22) of those with endoscopy but the sensitivity of clinical accuracy to reach final diagnosis of diverticulitis was higher with endoscopy (66.7%) compared to 37.5% in CT scan.

Acute cholecystitis accounts for 50.0% and it is as common as gallstone/biliary colic/choledocholithiasis (50.0%) in gallbladder group. Both conditions were diagnosed and can be confirmed with ultrasound abdomen. Sensitivity of clinical accuracy in diagnosing acute cholecystitis was 41.7% whilst 50% in gallstones with an ultrasound abdomen. In the bowel obstruction group, plain film of abdomen (PFA) was used to diagnoses the condition in most cases [67.9% (19/28) vs. 32.1% (9/28) with a CT scan]. However, a higher sensitivity of clinical accuracy was observed in CT scan compared to plain film of abdomen (55.6% vs. 31.6%).

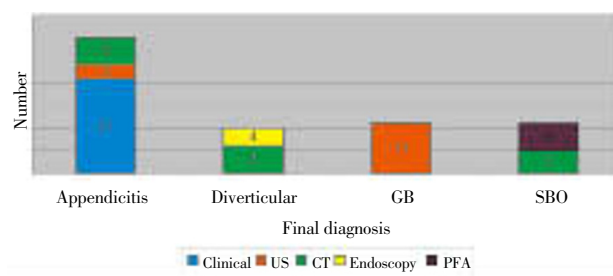


Figure 1. The rate or frequency of various tools or modalities in confirming the final diagnosis of acute surgical abdomen. *GB = Gallbladder disease; SBO = Subacute bowel obstruction; US = Ultrasound abdomen; CT = CT abdomen/pelvis; PFA = Plain film of abdomen.

Table 1

The rate of pick-up the final diagnosis of acute abdomen by various tests. *GB = Gallbladder disease; SBO = Subacute bowel obstruction; US = Ultrasound abdomen; CT = CT abdomen/pelvis; PFA = Plain film of abdomen.

Test	Result	Appendicitis	Diverticular	GB		SBO
				Gallstone	Cholecystitis	
Clinical	Positive	21	–	–	–	–
	Negative	2	–	–	–	–
US	Positive	3	–	6	5	–
	Negative	15	–	6	7	–
CT Scan	Positive	6	6	–	–	5
	Negative	2	10	–	–	4
Endoscopy	Positive	–	4	–	–	–
	Negative	–	2	–	–	–
PFA	Positive	–	–	–	–	6
	Negative	–	–	–	–	13

4. Discussion

This study demonstrates acute appendicitis can be diagnosed safely with history and clinical examination alone. Diagnosis of surgical abdomen is often supported by laboratory investigation and imaging. In female patient, it is mandatory to rule out the possibility of pregnancy at least with urine test for urine pregnancy test. In this retrospective study, we found that the calculated sensitivity of clinical

diagnosis of acute appendicitis was 91.3%. This suggests a high proportion of individuals with clinical suspicion of appendicitis were correctly identified by laparoscopy or laparoscopic appendicectomy. This may also reflect the low incidence of negative laparoscopic procedure and high accuracy of diagnosing acute abdomen by non-consultant hospital doctors (NCHD). Despite having high sensitivity (up to 100%), clinical evaluation has relatively low specificity (73%)^[2]. This means that surgeons are likely to overestimate

the presence of appendicitis in patients who present to the ED.

When the clinical picture is unclear, an ultrasound examination is a simple and cost effective tool to confirm the diagnosis. Abdominal ultrasonography (US) is commonly used as a diagnostic tool for diagnosing acute appendicitis. When ultrasound is unsatisfactory due to patient habitus or otherwise fails to clarify clinical uncertainty, abdominopelvic CT scan is the next best diagnostic tool of choice. However, CT scan is a less favourable tool in paediatric group because of radiation exposure in children. In a cohort study of 1021 consecutive patients with acute abdominal pain, US and CT were compared for the determination of urgent diagnoses. CT was significantly more sensitive than US (89% vs 70%, $P < 0.001$)^[3].

Compared to endoscopy, CT scan is more commonly used as a diagnostic tool to reach the diagnosis of diverticular disease. CT scan requires less technical skills compared to endoscopy procedure. In our study, the sensitivity of clinical accuracy in endoscopy was higher compared to CT scans (66.7% vs. 37.5%). It is not surprising because colonoscopy, for an example, can provide both diagnostic and therapeutic investigations for bowel-related pathologies. However, CT scanning is considered a better and safer tool to diagnosis acute presentation of diverticular disease due to risk of endoscopic perforation. Endoscopy is of importance but at a later date when acute diverticulitis has settled.

Ultrasound abdomen (US) is the best diagnostic tool in diagnosing all gallbladder-related disease (acute cholecystitis, biliary colic, choledocholithiasis). Sensitivity of clinical accuracy was determined as 45.8%, which approximately three times higher than the sensitivity of clinical accuracy in diagnosing appendicitis with an US. The remaining of right upper quadrant complaints may be likely attributed to other causes, for example, peptic ulcer disease (PUD), gastritis, or non-specific abdominal pain (NSAP). Several imaging techniques are available for the evaluation of suspected acute cholecystitis. In one study, US is the most frequently performed modality for right upper quadrant pain and yields a sensitivity of 88% and a specificity of 80% in the diagnosis of acute cholecystitis^[4].

PFA is a commoner tool compared CT scan in diagnosing bowel obstruction. The latter offers further diagnostic features, for examples, level of obstruction in bowel obstruction, evidence of solid organs metastases and intraabdominal collection of pleural or peritoneal fluid. According to one study, CT has the best reported accuracy for the diagnosis of small bowel obstruction, with a sensitivity of 94% and a specificity of 96%^[5]. In the same study, the cause of the obstruction was correctly identified at CT in 85% of patients with a clinically equivocal diagnosis of bowel obstruction.

Cocealed or small perforated viscus (*e.g.* perforated duodenal ulcer) which may not be seen on chest X-ray can also be detected with a CT scan. Conventional radiography is insensitive for the detection of air pockets smaller than 1 mm and only 33% sensitive for the detection of 1–13 mm pockets of air^[6]. The major advantage of CT, as compared with radiography and US, is that it can correctly depict the actual site of perforation in 86% of cases^[7].

Clinical suspicion of bowel ischemia is also best diagnosed by a CT scan. Sensitivity of a CT scan in diagnosing mesenteric ischaemia is higher when small bowel obstruction (SBO) is present^[8]. When splenic rupture, liver

laceration, and penetrating injury with possibilities of others vascular injury are suspected, CT scan provides a better clinical diagnosis in these acute or trauma situations. CT scan doesn't only reveal the severity and extend of the initial injuries, but also aid surgeons in the operating field.

Our study concludes sensitivity of clinical accuracy was the highest with clinical diagnosis in appendicitis (91.3%), endoscopy in diverticulitis (66.7%), ultrasound abdomen in gallstones-related disease (45.8%), and CT scan in bowel obstruction (55.6%). Sensitivity derived from each investigation does not reflect the 'true' sensitivity of each test in picking up a final correct diagnosis but it is a sensitivity solely based on how accurate clinical judgement by on-call surgical non-consultant hospital doctor. It is lower compared to other similar studies because of a small sample size in our study. Same principle or methodology can be applied to a larger sample population. In previous similar conducted study among Irish population, 79% of diagnoses of acute surgical abdomen made by NCHDs are the accurate final diagnoses^[9].

Radiological investigation is essential in diagnosis of surgical abdomen. They compliment clinical judgement and aid clinician to reach a final diagnosis correctly. In most cases, appendicitis can be diagnosed clinically, however, other cases of acute surgical abdomen requires further diagnostic tool to confirm the clinical diagnosis.

Conflict of interest statement

We declare that we have no conflict of interest.

References

- [1] Barker DJ, J Morris. Acute appendicitis, bathrooms, and diet in Britain and Ireland. *Br Med J (Clin Res Ed)* 1988; **296**(6627): 953–955.
- [2] Hong JJ, Cohn SM, Ekeh AP, Newman M, Salama M, Leblang SD, et al. A prospective randomized study of clinical assessment versus computed tomography for the diagnosis of acute appendicitis. *Surg Infect (Larchmt)* 2003; **4**(3): 231–239.
- [3] Wytze Laméris, Adrienne van Randen, H Wouter van Es, Johannes P M van Heeswijk, Bert van Ramshorst, Wim H Bouma, et al. Imaging strategies for detection of urgent conditions in patients with acute abdominal pain: diagnostic accuracy study. *BMJ* 2009; **338**: b2431.
- [4] Shea JA, Berlin JA, Escarce JJ, Clarke JR, Kinoshian BP, Cabana MD, et al. Revised estimates of diagnostic test sensitivity and specificity in suspected biliary tract disease. *Arch Intern Med* 1994; **154**(22): 2573–2581.
- [5] Megibow AJ. Bowel obstruction. Evaluation with CT. *Radiol Clin North Am* 1994; **32**(5): 861–870.
- [6] Stapakis JC, D Thickman. Diagnosis of pneumoperitoneum: abdominal CT vs. upright chest film. *J Comput Assist Tomogr* 1992; **16**(5): 713–716.
- [7] Hainaux B, Agneessens E, Bertinotti R, De Maertelaer V, Rubesova E, Capelluto E, et al. Accuracy of MDCT in predicting site of gastrointestinal tract perforation. *AJR Am J Roentgenol* 2006; **187**(5): 1179–1183.
- [8] Staunton M, DE Malone. Can acute mesenteric ischemia be ruled out using computed tomography? Critically appraised topic. *Can Assoc Radiol J* 2005; **56**(1): 9–12.
- [9] Cheema ST, Sotirovic S, Ahmad K, Grace P, Naqvi SA. Accuracy of admitting diagnosis in acute surgical patients by non consultant hospital doctors. *Ir Med J* 2005; **98**(4): 108–109.