

Contents lists available at [ScienceDirect](#)

## Asian Pacific Journal of Tropical Biomedicine

journal homepage: [www.elsevier.com/locate/apjtb](http://www.elsevier.com/locate/apjtb)

Document heading

Case report of *Plasmodium falciparum* malaria presenting as wide complex tachycardia

Sunil Kumar\*, Diwan SK, Mahajan SN, Shilpa Bawankule, Chetan Mahure

Department of Medicine, Jawahar Lal Nehru Medical College, Sawangi Wardha, Maharashtra, India

## ARTICLE INFO

## Article history:

Received 15 August 2011

Received in revised form 2 September 2011

Accepted 28 September 2011

Available online 15 October 2011

## Keywords:

*Plasmodium falciparum*

Malaria

Tachycardia

Palpitation

Electrocardiogram

## ABSTRACT

Malaria caused by *Plasmodium falciparum* is a multisystem disorder and may have diversity of clinical presentations. We are presenting a case report of patients of falciparum malaria who presented to us with palpitation and fever. On electrocardiogram he had wide complex tachycardia. This case reiterates the need to think of malaria in any case with symptoms of fever with chills, even with various unusual presentations like palpitation due to wide complex tachycardia, especially in endemic country like India.

## 1. Introduction

Malaria is a major disease of public health importance with a high morbidity and mortality in tropical countries. Various atypical presentations of malaria have been described in literature including cardiac complication which was believed historically to be fatal in 14% cases. However, more recent experience has demonstrated that cardiac involvement is actually a rare complication of malaria mainly due to *Plasmodium falciparum* (*P. falciparum*) infection<sup>[1]</sup>. We report a case of 55-year-old man with falciparum malaria presenting as wide complex tachycardia.

## 2. Case report

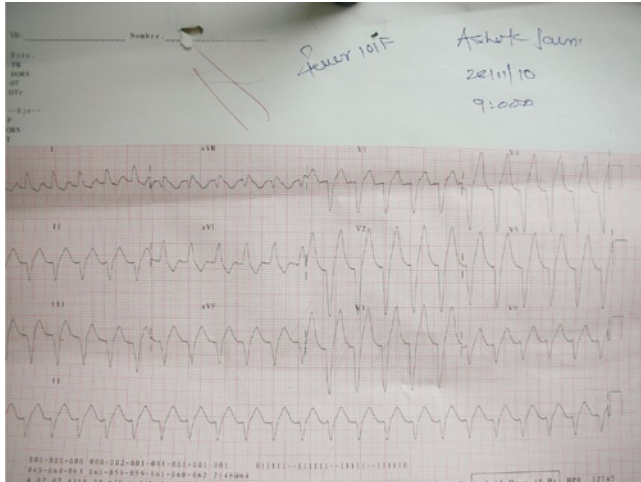
A 55-year-old male, from Chandrapur in Maharashtra State probably endemic zone for malaria, presented to the

medicine emergency department of this hospital with a 2-day history of palpitation, giddiness and fever which was associated with chills. There was no significant past medical history of rheumatic heart disease, lipid disorders, use of steroids and pain killers, nor was there a history of substance abuse. He was nonsmoker and nonalcoholic. There was no history of hypertension and diabetes mellitus. He had not received any antimalarial drugs like quinine or mefloquine.

On clinical examination at the time of presentation, he was alert, and febrile (103 °F). He had tachycardia with a regular pulse of 160/min. His blood pressure was normal. Systemic examinations were within normal limits, except soft splenomegaly. Examination of the cardiovascular system was otherwise unremarkable. Laboratory examination revealed haemoglobin 12.6 g/dL, total leucocyte count 3800/cmm (with granulocytes 68.6%), platelet count 70000 and haematocrit 32.2%. His kidney and liver function tests were normal. Serum sodium and potassium was 140 and 4.4 meq/L, respectively. The trans-thoracic echocardiographic examination was normal with no evidence of myocarditis or endocarditis. A Leishman-stained peripheral blood smear did not show any ring-form trophozoites of *P. falciparum*. However, his rapid antigen test for *P. falciparum* (parachek)

\*Corresponding author: Sunil Kumar, Associate Professor, Department of Medicine, Jawahar Lal Nehru Medical College, Sawangi Wardha, Maharashtra, India.  
E-mail: [sunilkumarmed@gmail.com](mailto:sunilkumarmed@gmail.com)

was positive. His chest X-ray was normal, there was no cardiomegaly. His continuous electrocardiogram (ECG) tracing showed wide complex tachycardia (Figure 1). He was treated with artesunate. Amiodarone was also started considering this tachycardia as ventricular tachycardia as there was no response from carotid sinus massage. There were marked improvements in his clinical symptoms, the ECG returned to normal pattern. Later on amiodarone was withdrawn. Artesunate was given for five days.



**Figure 1.** Electrocardiogram showing wide complex tachycardia.

### 3. Discussion

About two million malaria cases are being reported every year by the National Vector Borne Disease Control Programme, among them 50% is *P. falciparum*, the killer parasite. Cardiovascular manifestations in falciparum malaria include mainly hypotension and acute pulmonary oedema. In addition to these secondary infections, anaemia, hyperpyrexia, dehydration/fluid overload, metabolic acidosis, hypoxia, and disseminated intravascular coagulation can also contribute to the cardiovascular problems in malaria. Malaria can also complicate pre-existing cardiac decompensation.

In our case no malarial parasites were found on peripheral blood smears. This examination is operator dependent, requiring considerable expertise and adequate quality control. In expert hands, malaria microscopy is an accurate tool (sensitivity, 99.6%; specificity, 100%), but the accuracy of this test can be much lower if microscopists are not well trained (sensitivity, 69%; specificity, 62%)<sup>[2]</sup>. Negative results may partly be attributed to the absence of *P. falciparum* from the peripheral blood for a portion of its life cycle<sup>[3]</sup>. Newer histidine-rich protein (HRP-2)-based rapid diagnostic tests (RDTs) for falciparum malaria have

a high accuracy (sensitivity, 92.7%; specificity, 99.2%) and hence provide an alternative to microscopy<sup>[2]</sup>. Because the sensitivity of these tests in detecting other malaria species is low, RDTs have not yet replaced microscopy. Cardiac arrhythmias are very rarely observed in falciparum malaria. A variety of cardiac arrhythmias especially due to prolongation of QT interval have been reported frequently by the use of drugs like quinine and quinidine<sup>[4]</sup>. In this case no drug was administered and the patient had no evidence of any cardiac lesion. Possible mechanism may be from mechanical blockage of capillaries by malarial parasites and parasitized cells leading to ischemia. Toxic effects of a group of polypeptides especially tumor necrosis factor may also play a significant role in this pathophysiological process<sup>[5]</sup>. These polypeptides also increase thrombospondin secretion, which in turn enhances the sequestration of knob-bearing parasitized red cells<sup>[6]</sup>. The parasitized erythrocytes bind to receptors on the endothelial cells by the formation of knobs (electron-dense structures) and cause obstruction of capillary blood flow leading to ischemia<sup>[7]</sup>. However, more hypotheses should be explored for its mechanism. Physicians should be aware of the different ways in which malaria can present to ensure its early diagnosis and treatment.

### Conflict of interest statement

We declare that we have no conflict of interest.

### References

- [1] Franzan D, Curtius JM, Heitz W. Cardiac involvement during and after malaria. *Clin Invest* 1992; **70**: 670–673.
- [2] Joshi R, Colford JM, Reingold AL, Kalantri SP. Nonmalarial acute undifferentiated fever in a rural hospital in central India: diagnostic uncertainty and overtreatment with antimalarial agents. *Am J Trop Med Hyg* 2008; **78**(3): 393–399.
- [3] Khan MA, Smego RA, Razi ST, Beg MA. Emerging drug-resistance and guidelines for treatment of malaria. *J Coll Physicians Surg Pak* 2004; **14**: 319–324.
- [4] White NJ, Breman JG. Malaria: protozoal infection, section 18. *Harrison's principles of internal medicine*. 17th ed. 2008, p. 1290.
- [5] Clarke A, Chaudhri G, Cowden WB. Roles of tumor necrosis factor in the illness and pathology of malaria. *Trans R Soc Trop Med Hyg* 1989; **83**: 436–440.
- [6] Dunn SM, Hillman AJ, Stomski F, Jin BQ, Lucas CM, Boyd AW, et al. Leukocyte adhesion molecules involved in inflammation. *Transplant Proc* 1998; **21**: 31–34.
- [7] Kumar S, Jain AP, Vikas. Falciparum malaria presenting as acute pancreatitis. *J Vector Borne Dis* 2010; **47**: 121–122.