



Contents lists available at ScienceDirect

## Asian Pacific Journal of Tropical Biomedicine

journal homepage: www.elsevier.com/locate/apjtb



Document heading doi: 10.12980/APJTB.4.201414B378 ©2014 by the Asian Pacific Journal of Tropical Biomedicine. All rights reserved.

Histopathological and molecular study of *Neospora caninum* infection in bovine aborted fetusesAmir Kamali<sup>1</sup>, Hesam Adin Seifi<sup>1,2\*</sup>, Ahmad Reza Movassaghi<sup>2,3</sup>, Gholam Reza Razmi<sup>2,3</sup>, Zahra Naseri<sup>2</sup><sup>1</sup>Department of Clinical Sciences, Faculty of Veterinary Medicine, Ferdowsi University of Mashhad, Mashhad, Iran<sup>2</sup>Center of Excellence in Ruminant Abortion and Neonatal Mortality, Ferdowsi University of Mashhad, Mashhad, Iran<sup>3</sup>Department of Pathobiology, Faculty of Veterinary Medicine, Ferdowsi University of Mashhad, Mashhad, Iran

## ARTICLE INFO

## Article history:

Received 9 Sep 2014

Received in revised form 23 Sep 2014

Accepted 7 Oct 2014

Available online 17 Oct 2014

## Keywords:

*Neospora caninum*

Dairy herds

Abortion

PCR

Histopathology

Risk factors

## ABSTRACT

**Objective:** To estimate the extent to which abortion in dairy cows was associated with of *Neospora caninum* (*N. caninum*) and to determine the risk factors of neosporosis in dairy farms from 9 provinces in Iran.

**Methods:** Polymerase chain reaction (PCR) test was used to detect *Neospora* infection in the brain of 395 bovine aborted fetuses from 9 provinces of Iran. In addition, the brains of aborted fetuses were taken for histopathological examination. To identify the risk factors associated with neosporosis, data analysis was performed by SAS.

**Results:** *N. caninum* was detected in 179 (45%) out of 395 fetal brain samples of bovine aborted fetuses using PCR. Among the PCR-positive brain samples, only 56 samples were suited for histopathological examination. The characteristic lesions of *Neospora* infection including non-suppurative encephalitis were found in 16 (28%) of PCR-positive samples. The risk factors including season, parity of dam, history of bovine virus diarrhea and infectious bovine rhinotracheitis infection in herd, cow's milk production, herd size and fetal appearance did not show association with the infection. This study showed that *Neospora* caused abortion was significantly more in the second trimester of pregnancy than other periods. In addition, a significant association was observed between *Neospora* infection and stillbirth.

**Conclusions:** The results showed *N. caninum* infection was detected in high percentage of aborted fetuses. In addition, at least one fourth of abortions caused by *Neospora* infection. These results indicate increasing number of abortions associated with the protozoa more than reported before in Iran.

## 1. Introduction

*Neospora caninum* (*N. caninum*), an apicomplexan protozoan, is an important factor of fetal abortion in cattle that causes economic losses in dairy herds worldwide[1]. For the first time in 1984, this parasite was described in puppies with encephalomyelitis and myositis[2]. Historically in ruminant, the first report of *N. caninum* infection was diagnosed in a congenitally infected lamb in England[3]. The main route of transmission in cattle is vertical (80%-100%), although cows could be infected by ingestion of oocysts excreted by dogs and abortion may be observed in any age of pregnancy[4,5]. Dogs are final and intermediate host for

*N. caninum*[6]. It seems that the abortion rate in infected animals is three to seven times higher compared to uninfected ones. The main sign of *Neospora* infection in adult cow is abortion and it most occurs at 5-6 months gestation. *N. caninum* can also cause repeated abortion in cows[1]. Symptoms have been reported in calves younger than 2 months. These symptoms include neurological symptoms, weight loss and ataxia. In examination of the nervous system, decreased knee reflex and decreased peripheral sensation is evident. Calves may have protruding or asymmetric eyes. *N. caninum* occasionally cause birth defects such as hydrocephalus, spinal canal narrowing and scoliosis[1]. *N. caninum* DNA has been detected by polymerase chain reaction (PCR) and immunohistochemistry methods in brains of aborted fetuses in Iran[4,7]. Seroepidemiological studies have shown that the prevalence of *Neospora* infection is relatively high in dairy cattle[8-10] and dogs in Iran[11,12]. The objectives of the present

\*Corresponding author: Hesam Adin Seifi, Department of Clinical Sciences, Faculty of Veterinary Medicine, Ferdowsi University of Mashhad, Mashhad, Iran.  
E-mail: haseifi@um.ac.ir

Foundation Project: Supported by research fund of Ferdowsi University of Mashhad, Mashhad, Iran. (Grant No. 3/25975).

study were to estimate the extent to which abortion in dairy cows was associated with of *N. caninum* and to determine the risk factors of neosporosis in dairy farms in Iran. The present study is the first comprehensive assessment of abortion associated with *N. caninum* in dairy herds in Iran.

## 2. Materials and methods

The study was performed in 9 provinces (including Khorasan Razavi, North Khorasan, South Khorasan, Golestan, Mazandaran, Isfahan, Chaharmahale Bakhtiari, Kermanshah and West Azerbaijan) (Figure 1). The climate of these provinces varies from cold to warm area and they have almost 280000 cattle in dairy herds. The herd size varied from farm to farm with a range of 20 to 9000 cattle. Holstein/Friesian was the most common breed of cattle. This study was performed over a 4-year-period (2009-2013) in 45 dairy herds.

### 2.1. Sample collection

During 2009 to 2013, 395 aborted bovine fetuses at different

stages of gestation were referred to Center of Excellence in Ruminant Abortion and Neonatal Mortality. Firstly, the aborted fetuses were necropsied and samples of brain were collected under aseptic condition. After that, one half of the brain was taken for PCR and another half for histopathology examination. Collected fetal samples were centrifuged at 2000 ×g for 10 min and stored at 20 °C freezer until used.

### 2.2. DNA extraction and PCR

One half of the brain was homogenized with a stirrer, and DNA was extracted from 1 g homogenate sample using the commercial kit (Cinnagen Inc., Iran) according to the manufacturer's instructions. PCR was performed as described by Müller *et al.*[13]. Pair of Np6/Np21 primers (5' GGG TGT GCG TCC AAT CCT GTA AC 3' - 5' CTC GCC AGT CAA CCT ACG TCT TCT 3') was used to amplify the 337 bp DNA fragment.

### 2.3. Histopathological examination

For the histopathological study, brain tissues of aborted fetuses

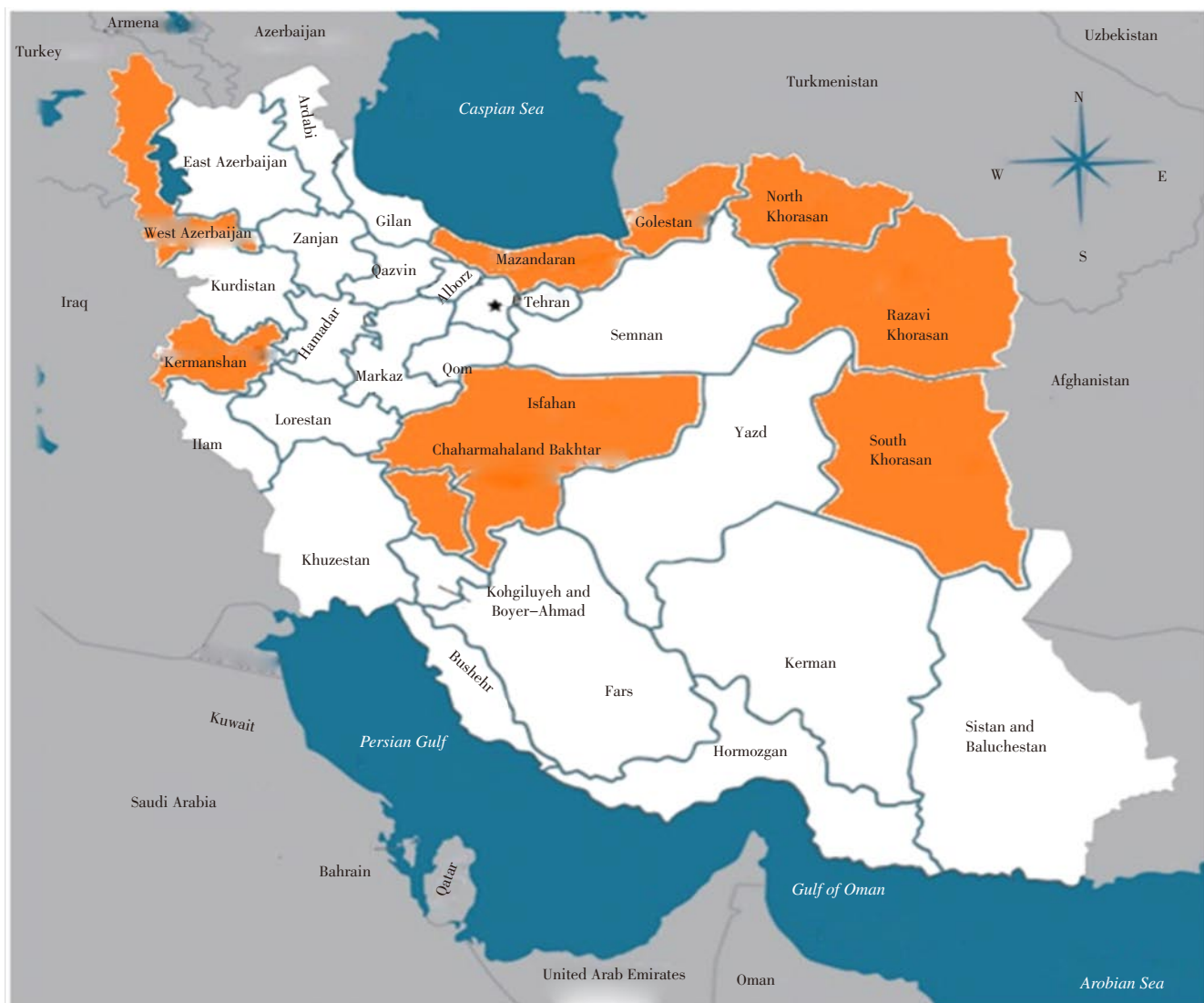

Figure 1. Map of Iran-sampling regions.

were fixed in 10% neutral buffered formalin. Then they were dehydrated through graded alcohols and embedded in paraffin wax. Sections were cut in 5 µm, deparaffinized, rehydrated and stained with hematoxylin and eosin (H & E). Then the stained sections were histopathologically assessed by light microscopy. Brains were examined for determined lesions and evaluated the parasite distribution. The sections were carefully examined at ×100, ×200, ×400 and ×1 000 magnifications, respectively.

2.4. Risk factors and statistical analysis

To identify the risk factors and clarify other factors associated with *Neospora* induced abortion in dairy cattle, the risk factors including season, parity of dam, cow’s milk production, history of bovine viral diarrhea (BVD) and infectious bovine rhinotracheitis (IBR) infection in herd, herd size, aborted fetal age, occurrence of stillbirth and fetal appearance were statistically analyzed. Statistical analysis was performed by SAS (Version 9.2). Chi-square analysis and logistic regression model were used to identify risk factors associated with *N. caninum* infected abortion.

3. Results

Brain samples of a total 395 aborted fetuses were examined by PCR for detection of *N. caninum*. Out of 395 brains samples, 179 samples (45%) were positive (Figure 2).

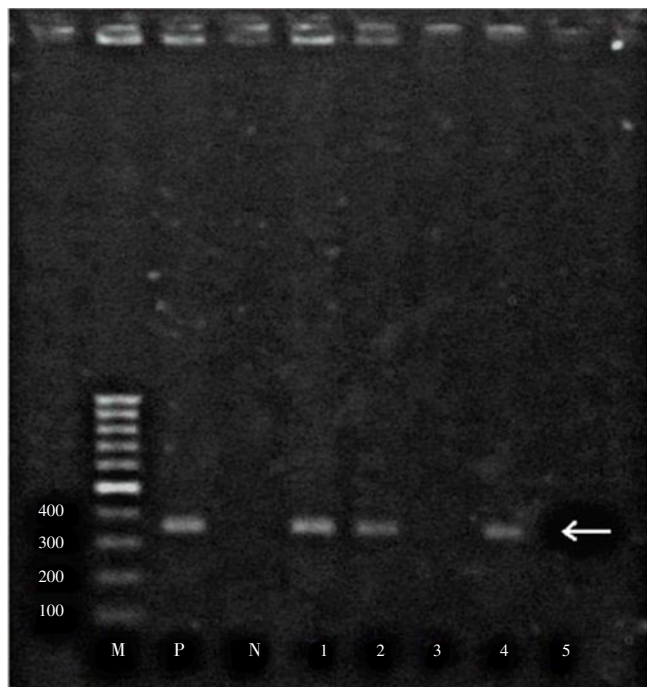


Figure 2. The PCR test for detecting *N. caninum* infection. M: Size marker (100 bp DNA Ladder); P: Positive control; N: Negative control; 1-5: Samples; 1, 2, 4: *N. caninum* positive; 3, 5: *N. caninum* negative. Right arrow shows 337 bp PCR product.

Only 56 fetal brains of PCR-positive were suitable for histopathological examination. Of these 56 samples, 16 (28%) showed the characteristic lesions of *Neospora* infection such as non-suppurative encephalitis. Other patterns of brain damage

that observed in this study were non-suppurative meningitis (5%), gliosis (focal and diffuse) (93%), satellitosis (2%), severe hyperemia (100%), hemorrhage (focal and diffuse) (51%), perivascular cuffing (63%), ischemic cell change (25%) and edema (100%). In one case, the *Neospora* like cyst with dimensions of 35 µm×47.5 µm was observed (Figure 3).

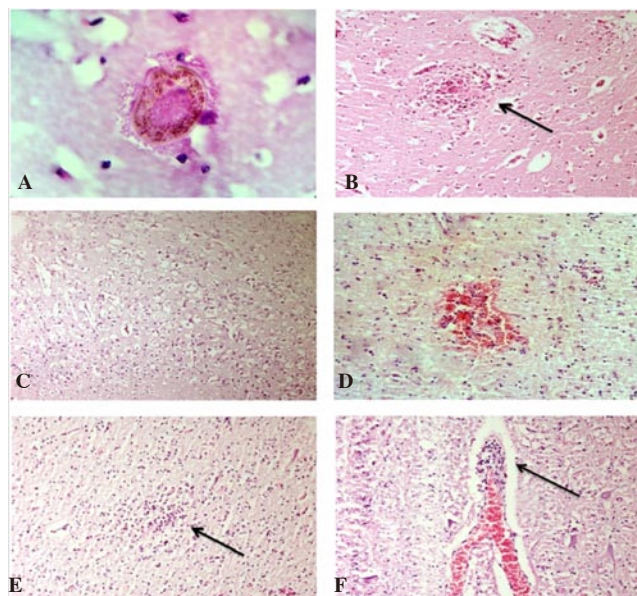


Figure 3. *N. caninum* like cyst in the brain. A: *N. caninum* like cyst with numerous bradyzoite enclosed in a thick cyst wall in brain (H & E, ×1000); B: Non-suppurative encephalitis (H & E, ×200); C: Diffuse edema (H & E, ×100); D: Focal hemorrhage in fetus brain parenchyma (H & E, ×200); E: Focal gliosis in fetus brain (H & E, ×200); F: Perivascular cuffing mostly mono nuclear cells in the fetus brain (H & E, ×200).

Table 1

Chi-square analysis of variables associated to *N. caninum* abortion based on PCR test.

Variable		PCR		P value
		Positive	Negative	
Season	Spring	70	78	0.8009
	Summer	40	44	
	Fall	20	27	
	Winter	49	67	
Stillbirth	Yes	3	23	0.0003
	No	176	193	
Milk production	Low (<30 kg)	1	2	0.8578
	Medium (30-35 kg)	63	78	
	High (>36 kg)	113	130	
Size	1-100	3	2	0.4494
	101-500	4	9	
	>500	170	199	
IBR	Infected	6	14	0.1579
	Non infected	173	202	
BVD	Infected	13	13	0.6196
	Non infected	166	203	
Parity	1-3 years old	48	50	0.1104
	4-5 years old	29	45	
	>5 years old	20	13	
Fetal age	1-90 days	0	1	<0.0001
	91-180 days	98	73	
	>180 days	60	115	
Fetal manifestation	Mummified	15	12	0.2682
	Normal	164	204	



Statistical analysis indicated that risk factor variables including season, parity of dam, the history of BVD and IBR occurrence in herd, cow's milk production, herd size and fetal appearance did not show significant association with *Neospora* caused abortion based on PCR test ( $P>0.05$ ), but two variables including fetal age and stillbirth showed a significant association with PCR results ( $P<0.001$ ) (Table 1).

The stillbirth incidence was significantly less in *Neospora*-infected fetuses than non-infected ones. In addition, this study showed that *Neospora* caused abortion was significantly more in the second trimester of pregnancy than other periods ( $P<0.001$ ). All variables were analyzed to the logistic regression model, which indicated that fetal age associated with *N. caninum*-related abortion was the only significant variable in logistic regression model. The odds of stillbirth occurrence in non-*Neospora* infected fetuses were two times greater than *Neospora* infected ones (OR: 2.043, 95% CI: 1.156-3.609,  $P=0.04$ ).

#### 4. Discussion

In present study, we used PCR and histopathology methods to detect *N. caninum* in aborted bovine fetuses. Among the diagnostic procedures, PCR was more sensitive and specific than other tests such as histopathology and immunohistochemistry[14] and was less affected by autolysis and postmortem changes[15]. So far, this method has been used for determining the presence of *N. caninum* DNA in different embryonic tissues[16], fetal fluids[17,18] and even oocysts in feces of final hosts[19]. PCR results along with histopathological findings in aborted fetal tissues, could confirm the occurrence of abortion by *N. caninum*. In the European countries and USA, some studies indicated that up to 42% of aborted fetuses from dairy cattle were infected with *N. caninum*[16]. In some areas of Iran, studies have been done to investigate the contamination rate of the parasite in dairy herds and the infection rate of 18.4%[8], 11.9%[9], and 12.6%[10] were reported. In present study, *N. caninum* DNA was detected in 45% (179) of brain samples of dairy farms in different provinces of Iran. This rate of infection is higher than other frequencies that were previously reported in Iran.

The main characteristic lesion of *Neospora* infection such as non-suppurative encephalitis[20–22] was observed in 16 (28%) out of 56 positive PCR brain samples. Other lesions in the brain were often focal to diffuse non-suppurative meningitis, mononuclear cell infiltration around acentral area of necrosis, glial proliferation and calcification[16,23]. In present study, other histologic lesions such as non-suppurative meningitis, gliosis, satellitosis, severe hyperemia, hemorrhage, perivascular cuffing, ischemic cell change, and edema were observed in brains of aborted fetuses. In our study, the *Neospora* like cyst with dimensions of 35  $\mu\text{m}\times 47.5 \mu\text{m}$  was observed. In bovine tissues, *N. caninum* cysts with 5–50  $\mu\text{m}$  in diameter and the thickness of the cyst wall varies from <1 to 2.5  $\mu\text{m}$  was reported[24]. The observed histopathological findings provide a strong evidence for *N. caninum*-induced abortion in dairy herds of Iran.

Many studies have been done to assess the risk factors associated with neosporosis in dairy cattle[25–29]. We investigated the associations of risk factors including parity, milk production, history of BVD and IBR infection in herd, season, herd size, age of abortions and fetal appearance with abortion due to *N. caninum* in dairy cows. The results were shown a significant association between fetal age and stillbirth with *N. caninum* infection. In the previous studies, there was also a strong relationship between fetal age and stillbirth with *Neospora* seroprevalence in dairy herds[30,31].

According to our results, *N. caninum* appears to be the most commonly detected and attributable cause of bovine abortion in dairy herds in Iran. Economic losses associated with neosporosis include abortion, neonatal mortality, early fetal death, and the fact that the disease has proved to be challenging to control, add the importance of the neosporosis as a major cause of abortion in dairy farms.

#### Conflict of interest statement

We declare that we have no conflict of interest.

#### Acknowledgements

The study was supported by research fund of Ferdowsi University of Mashhad, Mashhad, Iran. (Grant No. 3/25975). All the sampling and molecular diagnoses were performed in Center of Excellence in Ruminant Abortion and Neonatal Mortality. We are very grateful to Mr. Mohammadnejad for his technical assistance.

#### References

- [1] Dubey JP, Schares G. Neosporosis in animals-the last five years. *Vet Parasitol* 2011; **180**: 90-108.
- [2] Salehi N, Haddadzadeh H, Shayan P, Koochi MK. Isolation of *Neospora caninum* from an aborted fetus of seropositive cattle in Iran. *Vet Arhiv* 2012; **82**: 545-553.
- [3] King JS, Jenkins DJ, Ellis JT, Fleming P, Windsor PA, Šlapeta J. Implications of wild dog ecology on the sylvatic and domestic life cycle of *Neospora caninum* in Australia. *Vet J* 2011; **188**: 24-33.
- [4] Razmi GR, Maleki M, Farzaneh N, Talebkhan Garoussi M, Fallah AH. First report of *Neospora caninum*-associated bovine abortion in Mashhad Area, Iran. *Parasitol Res* 2007; **100**: 755-757.
- [5] Almería S. *Neospora caninum* and wildlife. *ISRN Parasitol* 2013; doi: 10.5402/2013/947347.
- [6] Monney T, Debache K, Hemphill A. Vaccines against a major cause of abortion in cattle, *Neospora caninum* infection. *Animals* 2011; **1**: 306-325.

- [7] Habibi GR, Hashemi-Fesharki R, Sadrebazzaz A, Bozorgi S, Bordbar N. Seminested PCR for diagnosis of *Neospora caninum* infection in cattle. *Arch Razi Inst* 2005; **59**: 55-64.
- [8] Nematollahi A, Moghaddam GH, Jaafari R, Helan JA, Norouzi M. Study on outbreak of *Neospora caninum*-associated abortion in dairy cows in Tabriz (Northwest Iran) by serological, molecular and histopathologic methods. *Asian Pac J Trop Med* 2013; **6**: 942-946.
- [9] Razmi GR, Mohammadi GR, Garossi T, Farzaneh N, Fallah AH, Maleki M. Seroepidemiology of *Neospora caninum* infection in dairy cattle herds in Mashhad Area, Iran. *Vet Parasitol* 2006; **135**: 187-189.
- [10] Nourollahi Fard SR, Khalili M, Aminzadeh A. Prevalence of antibodies to *Neospora caninum* in cattle in Kerman Province, South East Iran. *Vet Arhiv* 2008; **78**: 253-259.
- [11] Haddadzadeh HR, Sadrebazzaz A, Malmasi A, Talei Ardakani H, Khazraii Nia P, Sadreshirazi N. Seroprevalence of *Neospora caninum* infection in dogs from rural and urban environments in Tehran, Iran. *Parasitol Res* 2007; **101**: 1563-1565.
- [12] Hosseininejad M, Hosseini F. Seroprevalence of *Neospora caninum* and *Toxoplasma gondii* infection in dogs from west and central parts of Iran using two indirect ELISA tests and assessment of associate risk factors. *Iran J Vet Res* 2011; **12**: 46-51.
- [13] Müller N, Zimmermann V, Hentrich B, Gottstein B. Diagnosis of *Neospora caninum* and *Toxoplasma gondii* infection by PCR and DNA hybridization immunoassay. *J Clin Microbiol* 1996; **34**: 2850-2852.
- [14] Stuart P, Zintl A, De Waal T, Mulcahy G, Hawkins C, Lawton C. Investigating the role of wild carnivores in the epidemiology of bovine neosporosis. *Parasitology* 2013; **140**: 296-302.
- [15] Suteu O, Titilincu A, Modr D, Mihalca A, Mircean V, Cozma V. First identification of *Neospora caninum* by PCR in aborted bovine foetuses in Romania. *Parasitol Res* 2010; **106**: 719-722.
- [16] Dubey JP, Schares G. Diagnosis of bovine neosporosis. *Vet Parasitol* 2006; **140**: 1-34.
- [17] Doosti A, Khamesipour F, Nekoei S, Lutvikadic I. Survey for the presence of *Neospora caninum* in frozen bull's semen samples by PCR assay. *Asian Pac J Trop Dis* 2015; **5**: 7-12.
- [18] Buxton D, Wright S, Maley SW, Rae AG, Lundén A, Innes EA. Immunity to experimental neosporosis in pregnant sheep. *Parasite Immunol* 2001; **23**: 85-91.
- [19] Razmi G. Fecal and molecular survey of *Neospora caninum* in farm and household dogs in Mashhad Area, Khorasan Province, Iran. *Korean J Parasitol* 2009; **47**: 417-420.
- [20] uteu O, Pa tiu A, Györke A, Borza G, Ardelean A, Cozma V. A survey of *Neospora caninum*-associated abortion in dairy cattle of Romania. *Sci Parasitol* 2013; **14**: 139-146.
- [21] Basso W, Moré G, Quiroga MA, Balducchi D, Schares G, Venturini MC. *Neospora caninum* is a cause of perinatal mortality in axis deer (Axis axis). *Vet Parasitol* 2014; **199**: 255-258.
- [22] Sánchez S, Clark EG, Wobeser GA, Janzen ED, Philibert H. A retrospective study of non-suppurative encephalitis in beef cattle from Western Canada. *Can Vet J* 2013; **54**: 1127-1132.
- [23] Nishimura M, Kohara J, Hiasa J, Muroi Y, Yokoyama N, Kida K, et al. Tissue distribution of *Neospora caninum* in experimentally infected cattle. *Clin Vaccine Immunol* 2013; **20**: 309-312.
- [24] Dubey JP, Barr BC, Barta JR, Bjerkås I, Björkman C, Blagburn BL, et al. Redescription of *Neospora caninum* and its differentiation from related coccidia. *Int J Parasitol* 2002; **32**: 929-946.
- [25] Vanleeuwen JA, Haddad JP, Dohoo IR, Keefe GP, Tiwari A, Scott HM. Risk factors associated with *Neospora caninum* seropositivity in randomly sampled Canadian dairy cows and herds. *Prev Vet Med* 2010; **93**: 129-138.
- [26] Souza ME, Porto WJN, Albuquerque PPF, Souza Neto OL, Faria EB, Pinheiro Júnior JW, et al. Seroprevalence and risk factors associated with infection by *Neospora caninum* of dairy cattle in the state of Alagoas, Brazil. *Pesq Vet Bras* 2012; **32**: 1009-1013.
- [27] Beck R, Marinculi A, Mihaljević, Beni M, Martinković F. Seroprevalence and potential risk factors of *Neospora caninum* infection in dairy cattle in Croatia. *Vet Arhiv* 2010; **80**: 163-171.
- [28] Asmare K, Regassa F, Robertson LJ, Skjerve E. Seroprevalence of *Neospora caninum* and associated risk factors in intensive or semi-intensively managed dairy and breeding cattle of Ethiopia. *Vet Parasitol* 2013; **193**: 85-94.
- [29] Aguiar DM, Lacerda DP, Orlandelli RC, Medina AO, Azevedo SS, Okuda LH, et al. Seroprevalence and risk factors associated to *Neospora caninum* in female bovines from the Western São Paulo State, Brazil. *Arq Inst Biol* 2011; **78**: 183-189.
- [30] Reichel MP, Alejandra Ayanegui-Alcérreca M, Gondim LF, Ellis JT. What is the global economic impact of *Neospora caninum* in cattle-the billion dollar question. *Int J Parasitol* 2013; **43**: 133-142.
- [31] Justino FV, Elizabeth MS, José JMM. Risk factors associated with infection by *Neospora caninum* in dual-purpose cattle in the central region of Veracruz, Mexico. *Internet J Vet Med* 2012; doi: 10.5580/2ac7.