

HOSTED BY



ELSEVIER

Contents lists available at ScienceDirect

## Asian Pacific Journal of Tropical Biomedicine

journal homepage: [www.elsevier.com/locate/apjtb](http://www.elsevier.com/locate/apjtb)Original article <http://dx.doi.org/10.1016/j.apjtb.2015.07.018>Wound healing potential of *Althaea officinalis* flower mucilage in rabbit full thickness woundsRobab Valizadeh<sup>1</sup>, Ali Asghar Hemmati<sup>1</sup>, Gholamreza Houshmand<sup>1\*</sup>, Sara Bayat<sup>1,2</sup>, Mohammad Bahadoram<sup>1,2</sup><sup>1</sup>Department of Pharmacology and Toxicology, Herbal Research Center, Pharmacy School, Ahvaz Jundishapur University of Medical Sciences, Ahvaz, Iran<sup>2</sup>Medical Student Research Committee, Ahvaz Jundishapur University of Medical Sciences, Ahvaz, Iran

## ARTICLE INFO

## Article history:

Received 21 May 2015

Received in revised form 24 Jun, 2nd

revised form 10 Jul, 3rd revised form

13 Jul 2015

Accepted 16 Jul 2015

Available online 18 Aug 2015

## Keywords:

Wound

Antibacterial

Skin

Mucilage

*Althaea* flower

Rabbit

## ABSTRACT

**Objective:** To evaluate and practically demonstrate the influence of *Althaea officinalis* flower mucilage as a plant known in Iran's and other Middle Eastern countries' traditional medicine for its wound healing properties.

**Methods:** Animals were divided into 6 groups of 5 cases including a non-treated group as the negative control group receiving no treatment, a group treated with eucerin as the positive control group, a phenytoin 1% group as a standard group treated topically with phenytoin 1% hand-made ointment, and treatment groups treated with hand-made *Althaea officinalis* flower mucilage (AFM) ointment in a eucerin base with different concentrations (5%, 10%, 15%).

**Results:** Among the treatment groups, the AFM 15% ointment showed the best result. Wound healing duration was reduced by the surface application of these groups. Wound closure was completed on Days 14 and 15 in the AFM 15% ointment and phenytoin 1% groups, respectively. No significant difference was observed in healing period between these groups.

**Conclusions:** In conclusion, AFM 15% ointment was found to reduce wound healing time without any significant difference with the phenytoin 1% ointment. The authors suggest increased AFM effectiveness in when combined with phenytoin or other effectual plants.

## 1. Introduction

Wound is defined as any anatomical and physiological disruption in skin structure leading to skin cell damage [1]. Thereby, wound healing is a complex and overlapping process of reaction and interaction among cells and mediators to return natural skin ability, beginning immediately after skin loss. Inflammation proliferation and remodeling are three overlapping and continuous wound healing phases [2]. Immediately after injury in the first stage of homeostasis, vascular constriction and clot formation caused by fibrin and

platelets stop the bleeding [3,4]. Platelets release growth factors and attract neutrophil macrophage, and other inflammatory cells into the wound site. These cells kill microbes, break wound debris, secrete cytokines and produce reactive oxygen species [5,6]. Macrophage and fibroblast cells become dominant in this phase.

The second stage, the proliferation phase, is characterized by re-epithelialization angiogenesis and proliferation. Fibroblasts increase prominently and produce collagen and other extracellular matrix components such as proteoglycans and glycosaminoglycans. Collagen, as a basic structure of the granulation tissue, increases prominently in this phase. The organization of new vascular networks in the angiogenesis pathway stimulated by macrophage activity, tissue hypoxia and vascular endothelium growth factor (VEGF), provides necessary oxygen and nutrient supplements required for wound repair. The wound area is then epithelialized by keratinocytes. The healing process completes in the remodeling phase, during which the skin regains 80% of its original strength. Many factors can interfere

\*Corresponding author: Gholamreza Houshmand, Ph.D, Department of Pharmacology, School of Pharmacy, Ahvaz Jundishapur University of Medical Sciences, Ahvaz, Iran.

Tel: +98 613 336 7543

E-mail: [dr.houshmand\\_pharmaco@yahoo.com](mailto:dr.houshmand_pharmaco@yahoo.com)

Peer review under responsibility of Hainan Medical University.

Foundation Project: Supported by Ahvaz Jundishapur University of Medical Sciences, Iran (Grant No. 821).

in the wound healing process causing improper or impaired functionality. These factors include infection, age, sex hormones, stress, obesity, and diabetes [7–10].

Individual factors such as stress or diabetes can cause delays in the healing process or increase the risk of infection in the wound. In 1939, Kimball found gingival hyperplasia to be the most obvious side effect in patients treated with phenytoin. Later, other researchers also used phenytoin to improve the wound healing process [11]. Nowadays, phenytoin has become the most common wound healing cream in drugstores in Iran. Today, the healing properties of phytomedicine have become widely accepted [12].

The choice of plant to use for wound treatments greatly depends on numerous factors including skin structure, wound healing processes, substances that accelerate healing and plant components [13]. *Althaea officinalis* (*A. officinalis*), which is used as an emollient, diuretic, anti-inflammatory, anti-infective and immunomodulator remedy, is a very popular plant in Iranian traditional medicine (ITM) [14–16]. Al-Snafi analyzed *Althaea* for its components and maintained that it can have very practical health benefits [17]. According to ITM experts, *A. officinalis* has many therapeutic characteristics including its anti-inflammatory and antibacterial effects and its application as an immunomodulator. The main goal of the present study was to determine the wound healing efficacy of *Althaea officinalis* flower mucilage (AFM) formulated in 5%, 10%, and 15% eucerin bases with special attention given to its histological differentiation.

## 2. Materials and methods

Dried *A. officinalis* (marshmallow) flowers can be obtained from local stores. In order to acquire mucilage from dried *A. officinalis* powder, we dissolved 20 g ground powder in 500 mL boiled water. This mixture was then heated for 30 min at 70–75 °C and filtered twice. The liquid mucilage was subsequently heated using the bain marie method at 75 °C for 24–42 h. After the solvent evaporated, dried mucilage was carved with a scalpel. To prepare the AFM ointment with different concentrations, 5, 10 and 15 g ground dried mucilage was mixed with a eucerin base.

### 2.1. Preparation of animals

Thirty adult male and female New Zealand breed rabbits weighing 1.6–2.2 kg were obtained from the Razi Institute of Ahvaz. Rabbits were kept at (23 ± 2) °C in a light cycle of 12 h light and 12 h darkness, and fed with compact food made from Shushtar Pars Company, vegetables, and water *ad libitum*. Thirty rabbits were divided into six experimental groups ( $n = 5$ ) as follows: no treatment group, treatment with 1% phenytoin ointment, treatment with AFM 5% ointment, treatment with AFM 10% ointment, and treatment with AFM 15% ointment.

### 2.2. Wound induction method

First, the hair of the test animals' left side lower back was completely shaved. The animals were situated to stay in the standard crouching position. A metal template measuring 20 × 20 mm<sup>2</sup>, whose outline was traced by a fine-tipped pen, was placed on the stretched skin of each animal's lower back.

The wound areas were anesthetized by 2% lidocaine subcutaneous injection on the square corners and sterilized using betadine. Full thickness wounds were made by bistouries blades, forceps, and kukher scissors. A draft was drawn around each wound site by transparent plastic sheets and fine tipped pen marks. Sterilized wounds were washed with normal saline and betadine immediately. The animals were kept in individual cages after dressing and returned to their standard situation [temperature of (23 ± 2) °C, humidity of (50%–55%)]. Topical ointments (eucerin, phenytoin in eucerin base and 5%, 10%, 15% concentrations of AFM in eucerin base) were applied on wound sites twice a day. To reduce infection rate, wound sites were evaluated daily for infection. All dressings and animal maintenance followed the ethical rules of standard surgery processes.

### 2.3. Method of wound area calculation

Wound area was calculated using graph paper. Healing processes were found to be dependent on general (oxygenation, nutrition and infection) and individual (sex hormones, obesity, and age) factors. Although we tried to create equal situations to minimize differences, the effect of individual characteristics was undeniable in the healing process. To minimize errors in the measurement of the wound area as well as achieve statistically sound results, wound healing percentage was replaced with wound area and calculated as follows:

Wound healing percentage in N day

$$= \frac{(\text{Wound area in first day} - \text{Wound area in Nth day})}{\text{Wound area in first day}} \times 100$$

Precise interpretations of tissue samples required detailed sampling; therefore, after anesthesia with 2% lidocaine subcutaneous injection, two triangular areas were separated from the corners of the wound site to be histologically evaluated on Day 7 at the end of treatment. The tip of each triangle was treated and the base was left untouched. Samples were fixed in 10% formalin and delivered to the Pathology Laboratory. Sample preparation and interpretation were carried out by pathology experts from Shafa Hospital and faculty members of the Department of Veterinarian Sciences, Shahid Chamran University, Ahvaz, Iran. Hematoxylin and eosin (H & E) coloring was used for tissue coloring.

### 2.4. Statistical analysis

Healing percentage was considered as healing factor between the groups. After data collection, a One-way ANOVA and Tukey tests were run. Each point in the diagrams showed the mean ± SEM, and  $P < 0.05$  was considered as significant.

## 3. Results

In the non-treatment and eucerin groups, the wound healed within 21 days. For those treated with 1% phenytoin in the eucerin base, 15 days were required. The AFM ointment with different concentrations of 5%, 10% and 15%, improved healing in 17, 16 and 14 days, respectively. The healing percentage in different groups on different days was analyzed through a One-way ANOVA and Tukey's test. Healing percentage was

found not to be significantly different for the non-treated and eucerin-treated groups (Figure 1). Figure 2 shows the comparison between the 1% phenytoin and eucerin healing ability and the significant difference observed.

As shown in Figure 3, compared to the eucerin-treated group, the healing percentage in the 5% AFM ointment group was significantly different at Day 11. Figure 4 shows that the 10% AFM ointment group was significantly different from the eucerin-treated group.

Figure 5 shows the AFM 15% treated and the eucerin treated groups compared. In Figure 5, significant differences were observed in the healing percentage from the first day of wound development.

Figure 6 shows the comparison between the AFM 15% and 1% phenytoin and significant differences were observed in the healing percentage from the 3rd day.

As indicated by the results of Day 14 with the short treatment, different AFM concentrations (5%, 10%, 15%) and the 1% phenytoin groups showed significant differences from the eucerin treated group.

### 3.1. Histological assay

Having a precise interpretation of tissue samples required for the detailed sampling, two triangle samples were separated carefully from the corner of the wound sites on the 7th and final treatment days. Samples were fixed in 10% formalin solution and delivered to the Pathology Laboratory. H & E coloring was selected for tissue coloring. Tissue sample preparations were done in the Department of Pathology, Shafa Hospital, Ahvaz, Iran. Pictures were taken from tissue samples by light

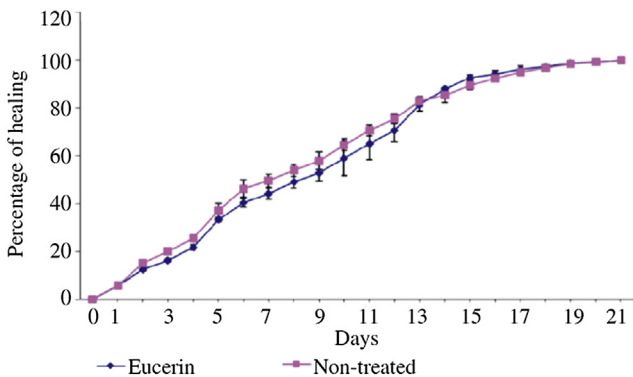


Figure 1. Wound healing profile of non-treated and eucerin-treated groups.

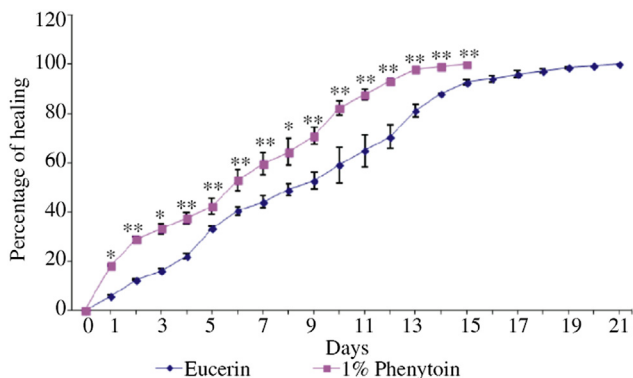


Figure 2. Wound healing profile of 1%-treated and eucerin-treated groups. \*:  $P < 0.05$ , \*\*:  $P < 0.01$ .

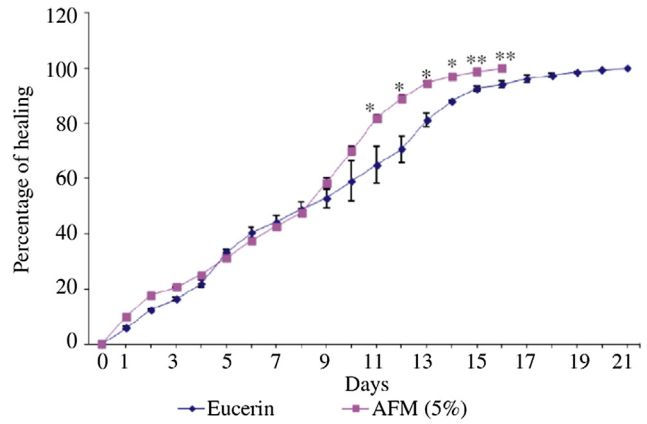


Figure 3. Wound healing profile of AFM 5%-treated and eucerin-treated groups. \*:  $P < 0.05$ , \*\*:  $P < 0.01$ .

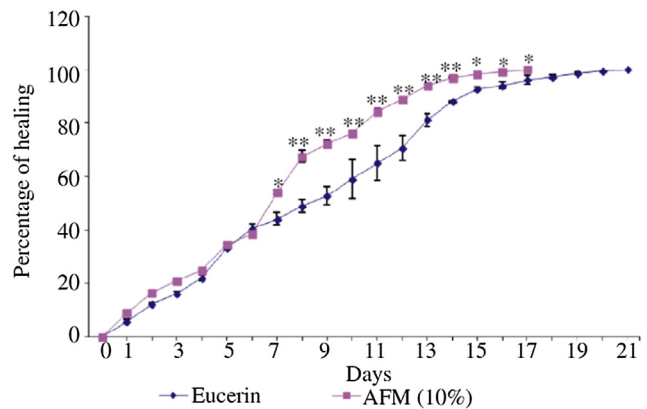


Figure 4. Wound healing profile of AFM 10%-treated and eucerin-treated groups. \*:  $P < 0.05$ , \*\*:  $P < 0.01$ .

microscopy in the Department of Pathology, School of Veterinarian Sciences, Shahid Chamran University, Ahvaz, Iran.

#### 3.1.1. Non-treated group

In the 7th day, wide ulcers were observed in the epidermis layer. The accumulation of inflammation cells was seen in the dermis layer, while granulation tissues were not seen in the 7th day (Figure 7). At the end of treatment (Day 21), epidermis

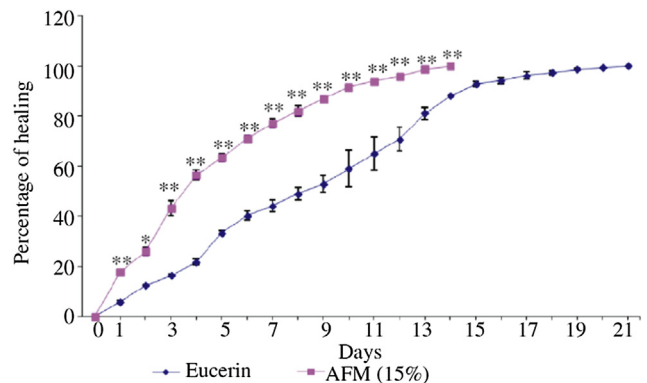
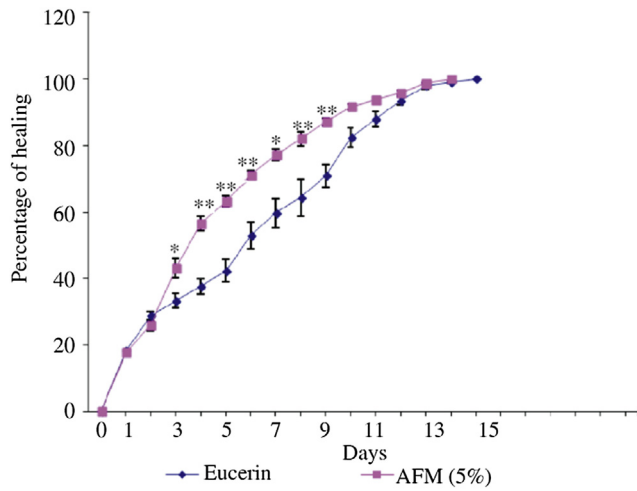
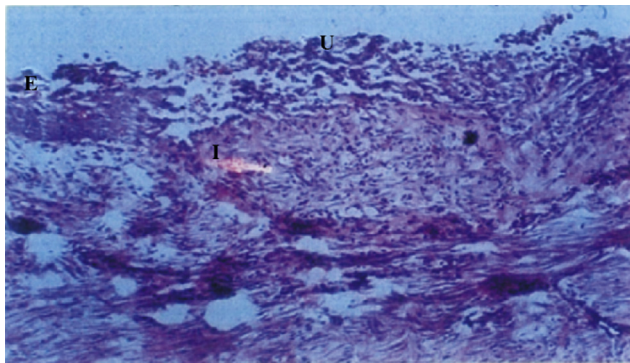


Figure 5. Wound healing profile of AFM 15%-treated and eucerin-treated groups. \*:  $P < 0.05$ , \*\*:  $P < 0.01$ .



**Figure 6.** Wound healing profile of 1% phenytoin-treated and AFM 15%-treated groups.  
\*:  $P < 0.05$ , \*\*:  $P < 0.01$ .

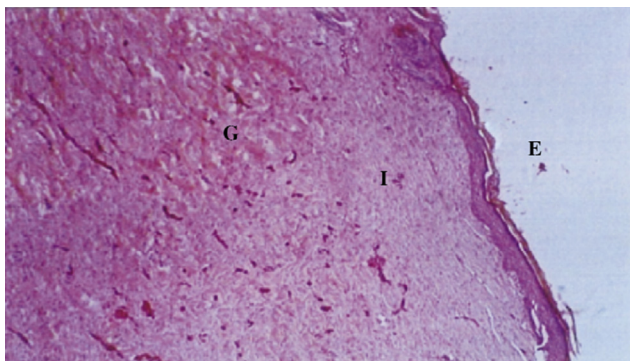


**Figure 7.** Tissue sample of wound site in non-treated group on Day 7 (H & E,  $\times 100$ ).  
E: Epidermis; U: Ulcer; I: Inflammation cells.

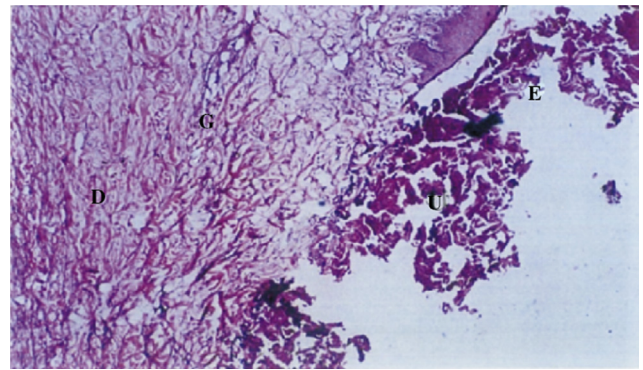
remodeling, granulation tissue and dispersed inflammation cells were observed in this group (Figure 8).

**3.1.2. Eucerin-treated group**

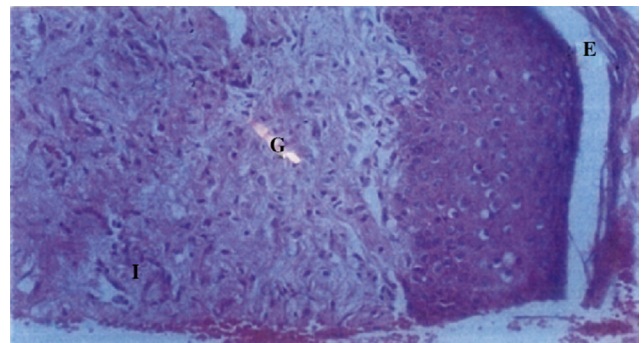
At the 7th day, epidermis renovation began, but ulcers were observed in the wound site and fibroblast cells proliferation and granulation tissues formed in the dermis layer (Figure 9).



**Figure 8.** Tissue sample of healed wound in non-treated group on Day 21 (H & E,  $\times 100$ ).  
E: Epidermis; G: Granulation tissue; I: Inflammation cells.



**Figure 9.** Tissue sample of wound site in eucerin treated group on Day 7 (H & E,  $\times 100$ ).  
E: Epidermis; U: Ulcer; G: Granulation tissue; D: Dermis.



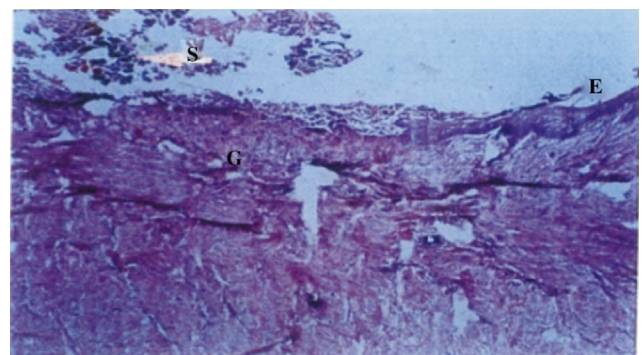
**Figure 10.** Tissue sample of wound site in eucerin treated group on Day 21 (H & E,  $\times 200$ ).  
E: Epidermis; G: Granulation tissue; I: Inflammation cells.

In the final day, when wound size reduced to zero, the epidermis was formed completely; accumulation inflammatory cells were observed and fibroblast proliferation with initial granulation tissue was formed (Figure 10).

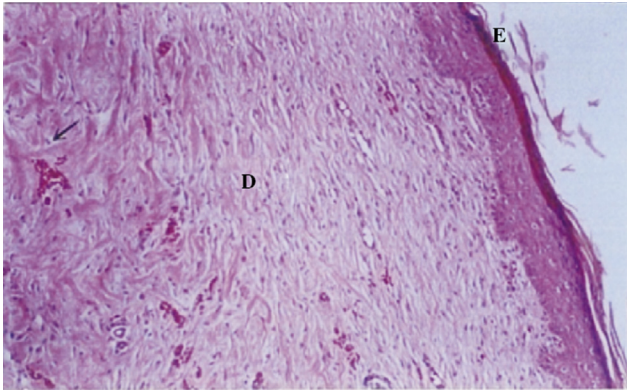
**3.1.3. 1% Phenytoin ointment-treated group**

Debris tissue and epidermis formation were clearly observed at Day 7. Fibroblast proliferation showed the initial process of granulation tissue formation (Figure 11).

Epidermis regenerated completely at the end of the treatment, and proliferated fibroblast and precipitated collagen were observed. Dermis restoration was also evident (Figure 12).



**Figure 11.** Tissue sample of healed wound in 1% phenytoin treated group on Day 7 (H & E,  $\times 200$ ).  
E: Epidermis; G: Granulation tissue; S: Scar.



**Figure 12.** Tissue sample of healed wound in 1% phenytoin treated group on Day 15 (H & E,  $\times 200$ ).  
E: Epidermis; D: Dermis.

#### 3.1.4. 5% AFM ointment-treated group

At Day 7, ulcers, necrotic tissues in the epidermis layer, inflammatory cells and neutrophil accumulations were clearly observed (Figure 13). In the final day of treatment, epidermis formation was completed, and granulation tissues, matured fibroblast cells and collagen deposition were seen (Figure 14).

#### 3.1.5. 10% AFM ointment-treated group

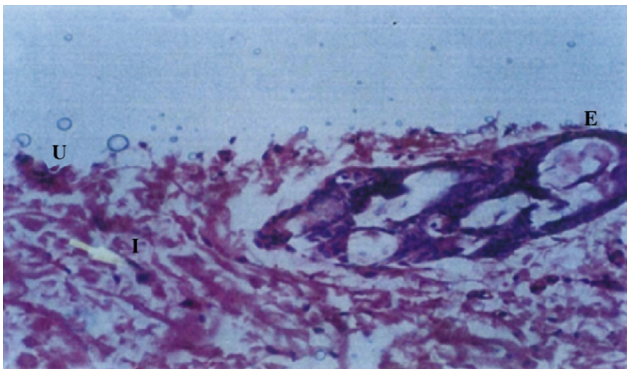
At Day 7, the epidermis was passing through the initial repairing process, and granulation tissues and neutrophil cells in histological assays were clearly observed (Figure 15). At the end of treatment, epidermis formation was completed and sedimentary collagen, proliferated fibroblast, and granulation tissues were seen (Figure 16).

#### 3.1.6. 15% AFM ointment-treated group

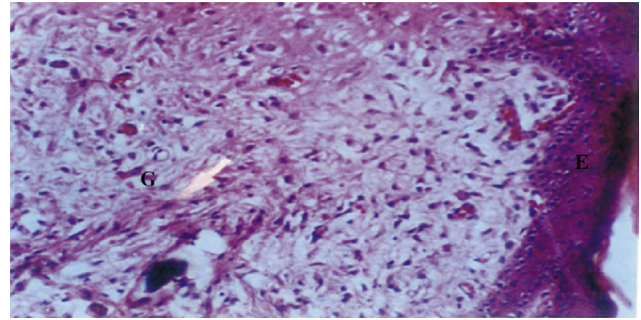
At Day 7, new epidermis was formed under the debris tissue and an irritation reaction was seen in the dermis (Figure 17). On the 14th day, the epidermis layer was seen with normal thickness in the histological assay, and fibroblast proliferation and granulation tissue formation in the dermis layer were observed (Figure 18).

### 3.2. Histological result

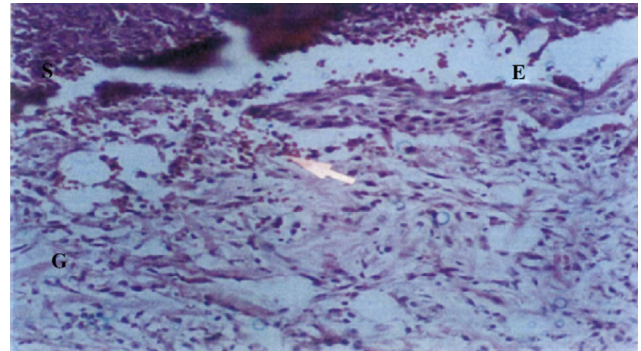
The 15% AFM ointment made perfect repair in a macroscopic analysis 14 days after the treatment (the shortest time



**Figure 13.** Tissue sample of healed wound in 5% *Althaea* ointment treated group on Day 7 (H & E,  $\times 200$ ).  
E: Epidermis; U: Ulcer; I: Inflammation cells.




**Figure 14.** Tissue sample of healed wound in 5% *Althaea* ointment treated group on Day 16 (H & E,  $\times 200$ ).  
E: Epidermis; G: Granulation tissue.

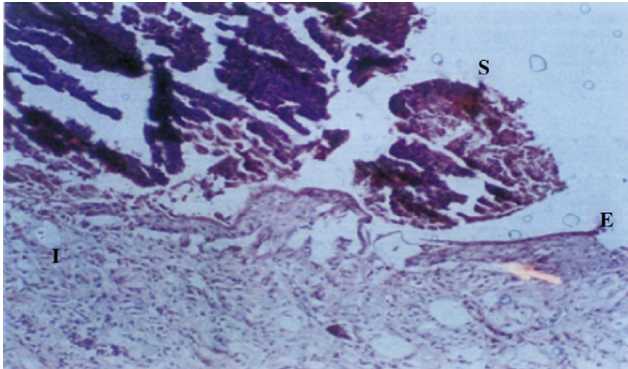


**Figure 15.** Tissue sample of healed wound in 10% *Althaea* ointment treated group on Day 7 (H & E,  $\times 200$ ).  
E: Epidermis; G: Granulation tissue.

between groups). At the end of the treatment, when complete healing was observed in the macroscopic evaluation, different groups were evaluated for epidermis thickness; new blood vessels were found in the angiogenesis process. In addition, fibroblast numbers increased and maturation and collagen precipitation were also formed. In the eucerin and non-treatment groups, inflammation reactions were seen in the macroscopic evaluation, despite being at the end of the treatment. Fibroblasts were observed in the microscopic analysis, which was also the same for other treatment groups (1% phenytoin and 5%, 10%, 15% AFM ointments). No inflammation reaction was observed. Fibroblast number decreased due to the anti-inflammatory effect in these groups. Collagen precipitation was observed as a

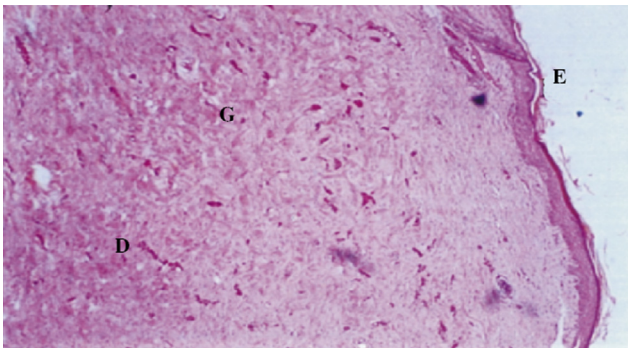


**Figure 16.** Tissue sample of healed wound in 10% *Althaea* ointment treated group on Day 17 (H & E,  $\times 100$ ).  
E: Epidermis; G: Granulation tissue; D: Dermis.



**Figure 17.** Tissue sample of healed wound in 15% *Althaea* ointment treated group on Day 7 (H & E,  $\times 100$ ).

E: Epidermis; I: Inflammation tissue; S: Scar.



**Figure 18.** Tissue sample of healed wound in 15% *Althaea* ointment treated group on Day 14 (H & E,  $\times 100$ ).

E: Epidermis; G: Granulation tissue; D: Dermis.

macroscopic sign in all treatment groups in the final treatment day. Angiogenesis was clearly observed in the picture with a  $200\times$  resolution. The 1% phenytoin and the 15% AFM ointments showed higher healing rates. In the 15% AFM group on Days 3–9, little difference was observed in the final epidermis thickness or collagen precipitation as compared to the final day of the treatment. In this study, perfect repair and final day refer to the wound site without any sign of infection, secretion or blood vessels in the skin surface (blood vessels were seen in the angiogenesis period in the incomplete repairs). In other words, skin elasticity returned to its normal position, though scars might have been observed in the wound site in light or dark areas a long time after healing. The pathological picture evaluation of treatment groups on the 7th day showed initial epithelialization and epidermis formation in the 1% phenytoin and 15% AFM groups. The epidermis in the eucerin-treated group was thicker in the final day of treatment (Day 21) compared with the *A. officinalis* of different concentrations or the 1% phenytoin groups. This showed that longer periods and repairing times with less speed could result in a thicker epidermis.

#### 4. Discussion

Wound healing is a complex and continuous process that begins immediately after injury. It is accompanied by homeostasis blood clotting inflammation proliferation and remodeling phases. All these processes can prolong or promote healing by influencing external or internal factors including infection sex hormones and nutrition. Today, the demand for herbal therapy is

increasing. Phytomedicine has a long history in herbal remedies. *A. officinalis* flower is a famous plant in ITM characterized by its anti-inflammatory immunomodulator and anti-infection properties. Al-Snafi analyzed and detected *A. officinalis* flower components and approved its remedial properties accordingly. The components they detected include mucilage, pectin, tannin, flavonoids, phenolic acid, and other amino acids [17]. Li *et al.* in their survival literature, argued that tannic acid can promote excisional wound healing by angiogenesis and antibacterial activities. They showed that tannic acid increased the VEGF level [18–20]. VEGF is the most efficacious, prevalent and long term angiogenesis signal stimulator for wound sites. Tannin and arabinose promote healing time through coagulating surface proteins [20]. Pectin is another detected *A. officinalis* flower substance that prepares moist and oxygen in the wound site which is, in turn, a vital factor for angiogenesis and epithelialization and kills bacteria in wound sites [21–23]. Researchers have found anti-oxidant agents to diminish the increased level of reactive oxygen species in wound sites and to minimize tissue damage resulting from hydrogen peroxide production or oxygen free radicals in these sites [24]. Recently, studies have reported mucilage (the major part of *A. officinalis* extract) to be a polysaccharide that stimulates the epithelialization in the epithelial surface of the damaged tissue. Phenolic acid in *A. officinalis* has an anti-inflammatory effect which helps reduce healing time. The weaker inflammatory reaction in pathological samples of different concentrations of *A. officinalis* at the end of our treatment might be caused by this compound [24,25].

Our initial findings regarding the wound healing process showed a reduced healing time. In this study, the 15% AFM ointment significantly enhanced wound healing in rabbits and reduced the days needed for complete healing compared with the eucerin or non-treated groups; nevertheless, no significant difference was found with the 1% phenytoin ointment treated group. Thus, more investigations are required to elucidate the exact effect of *A. officinalis* flower on wound healing.

#### Conflict of interest statement

We declare that we have no conflict of interest.

#### Acknowledgments

This study is part of Pharm D thesis of Robab Valizadeh. In addition, the authors wish to thankfully acknowledge the financial support (Grant No. 821) of Ahvaz Jundishapur University of Medical Sciences, Iran.

#### References

- [1] Broughton G 2nd, Janis JE, Attinger CE. The basic science of wound healing. *Plast Reconstr Surg* 2006; **117**(7 Suppl): 12S-34S.
- [2] Situm M, Kolic M. [Chronic wounds: differential diagnosis]. *Acta Med Croatica* 2013; **67**(Suppl 1): 11-20. Croatian.
- [3] Reinke JM, Sorg H. Wound repair and regeneration. *Eur Surg Res* 2012; **49**(1): 35-43.
- [4] Velnar T, Bailey T, Smrkolj V. The wound healing process: an overview of the cellular and molecular mechanisms. *J Int Med Res* 2009; **37**(5): 1528-42.
- [5] Eming SA, Krieg T, Davidson JM. Inflammation in wound repair: molecular and cellular mechanisms. *J Invest Dermatol* 2007; **127**(3): 514-25.

- [6] Barrientos S, Stojadinovic O, Golinko MS, Brem H, Tomic-Canic M. Growth factors and cytokines in wound healing. *Wound Repair Regen* 2008; **16**(5): 585-601.
- [7] Hemmati AA, Mojiri Forushani H, Mohammad Asgari H. Wound healing potential of topical amlodipine in full thickness wound of rabbit. *Jundishapur J Nat Pharm Prod* 2014; **9**(3): e15638.
- [8] Willenborg S, Eckes B, Brinckmann J, Krieg T, Waisman A, Hartmann K, et al. Genetic ablation of mast cells redefines the role of mast cells in skin wound healing and bleomycin-induced fibrosis. *J Invest Dermatol* 2014; **134**(7): 2005-15.
- [9] Khalil H, Cullen M, Chambers H, Carroll M, Walker J. Elements affecting wound healing time: an evidence based analysis. *Wound Repair Regen* 2015; <http://dx.doi.org/10.1111/wrr.12307>.
- [10] Zhu T, Park HC, Son KM, Yang HC. Effects of dimethylglycine on wound healing of palatal mucosa in a rat model. *BMC Oral Health* 2015; **15**: 60.
- [11] Firmino F, de Almeida AM, e Silva Rde J, Alves Gda S, Grandeiro Dda S, Penna LH. [Scientific production on the applicability of phenytoin in wound healing]. *Rev Esc Enferm Usp* 2014; **48**(1): 166-73. Portuguese.
- [12] Zhao M. Electrical fields in wound healing-an overriding signal that directs cell migration. *Semin Cell Dev Biol* 2009; **20**(6): 674-82.
- [13] Marrotte EJ, Chen DD, Hakim JS, Chen AF. Manganese superoxide dismutase expression in endothelial progenitor cells accelerates wound healing in diabetic mice. *J Clin Invest* 2010; **120**(12): 4207-19.
- [14] Hage-Sleiman R, Mroueh M, Daher CF. Pharmacological evaluation of aqueous extract of *Althaea officinalis* flower grown in Lebanon. *Pharm Biol* 2011; **49**(3): 327-33.
- [15] Sutovska M, Capek P, Franova S, Joskova M, Sutovsky J, Marcinek J, et al. Antitussive activity of *Althaea officinalis* L. polysaccharide rhamnogalacturonan and its changes in guinea pigs with ovalbumine-induced airways inflammation. *Bratisl Lek Listy* 2011; **112**(12): 670-5.
- [16] Sadighara P, Gharibi S, Moghadam Jafari A, Jahed Khaniki G, Salari S. The antioxidant and flavonoids contents of *Althaea officinalis* L. flowers based on their color. *Avicenna J Phytomed* 2012; **2**(3): 113-7.
- [17] Al-Snafi AE. The pharmaceutical importance of *Althaea officinalis* and *Althaea rosea*: a review. *Int J Pharm Tech Res* 2013; **5**(3): 1378-85.
- [18] Guo S, DiPietro LA. Factors affecting wound healing. *J Dent Res* 2010; **89**(3): 219-29.
- [19] Zarshenas MM, Arabzadeh A, Tafti MA, Kordafshari G, Zargaran A, Mohagheghzadeh A. Application of herbal exudates in traditional Persian medicine. *Galen Med J* 2013; **1**(2): 78-83.
- [20] Li K, Diao Y, Zhang H, Wang S, Zhang Z, Yu B, et al. Tannin extracts from immature fruits of *Terminalia chebula* Fructus Retz. promote cutaneous wound healing in rats. *BMC Complement Altern Med* 2011; **11**: 86.
- [21] Boateng JS, Matthews KH, Stevens HN, Eccleston GM. Wound healing dressings and drug delivery systems: a review. *J Pharm Sci* 2008; **97**(8): 2892-923.
- [22] Okan D, Woo K, Ayello EA, Sibbald G. The role of moisture balance in wound healing. *Adv Skin Wound Care* 2007; **20**(1): 39-53.
- [23] Eisenbud DE. Oxygen in wound healing: nutrient, antibiotic, signaling molecule, and therapeutic agent. *Clin Plast Surg* 2012; **39**(3): 293-310.
- [24] Hemmati AA. Therapeutic significance of natural anti oxidants. *Jundishapur J Nat Pharm Prod* 2013; **8**(3): 99.
- [25] Hemmati AA, Houshmand G, Ghorbanzadeh B, Nemati M, Behmanesh MA. Topical vitamin K1 promotes repair of full thickness wound in rat. *Indian J Pharmacol* 2014; **46**(4): 409-12.