

Contents lists available at ScienceDirect

Asian Pacific Journal of Tropical Biomedicine

journal homepage: www.elsevier.com/locate/apjtb

Document heading doi:10.12980/APJTB.4.2014APJTB-2014-0012 © 2014 by the Asian Pacific Journal of Tropical Biomedicine. All rights reserved.

Disseminated toxocariasis in an immunocompetent host

Madan Raj Aryal¹, Paras Karmacharya¹, Amrit Pokharel², Smith Giri³, Ranjan Pathak^{1*}, Richard Alweis¹¹Department of Medicine, Reading Health System, PA 19611, USA²Department of Medicine, Tribhuvan University Teaching Hospital, Kathmandu, Nepal³Department of Medicine, University of Tennessee Health Science Center, TN 38163, USA

PEER REVIEW

Peer reviewer

Dr. Lim Boon Huat, Biomedicine Programme, School of Health Sciences, Health Campus, Universiti Sains Malaysia, 16150 Kubang Kerian, Kelantan, Malaysia. Tel: +6 09767 7619, Fax: +6 09767 7515, E-mail: limbh@usm.my
Co-reviewers: Prof. Fabrizio Bruschi, Pisa, Italy.

Comments

The authors demonstrated the efficacy of albendazole or mebendazole with concomitant corticosteroid on treating a patient suspected of being infected with toxocariasis.
Details on Page 840

ABSTRACT

Toxocariasis is a zoonotic infection caused by *Toxocara canis*, or less commonly, *Toxocara cati*, which is one of the most common zoonotic infections worldwide. It commonly affects the pediatric and immunocompromised population; however, it has rarely been reported in the immunocompetent adults. Two of the well-recognized syndromes in children are visceral larva migrans and ocular larva migrans. Infection in adults usually ranges from asymptomatic to non-specific symptoms which makes the diagnosis challenging. A case of 36 year-old male was presented with disseminated toxocariasis with pulmonary and hepatic involvement and striking peripheral eosinophilia.

KEYWORDS

Toxocariasis, *Toxocara canis*, Mebendazole, Albendazole

1. Introduction

Toxocariasis is a human infiltrative larval infection caused by the dog ascarid, *Toxocara canis* and the cat ascarid, *Toxocara cati*[1]. Human toxocariasis is one of the most common zoonotic infections worldwide. While it is more common in the tropical regions of the world; it is estimated that human seroprevalence is 13.9% in the United States and that about 5% of dogs and puppies in North America are infected[2,3]. It commonly affects the pediatric and immunocompromised population; however, it has rarely been reported in the immunocompetent adults. Infection in adults usually ranges from asymptomatic to non-specific symptoms which makes the diagnosis challenging. A case of 36 year-old male was presented with disseminated toxocariasis with pulmonary and hepatic involvement and

striking peripheral eosinophilia.

2. Case presentation

A 36 year-old Caucasian male presented to the emergency department with low grade fever, fatigue and abdominal pain for 1 week. The pain was intermittent, lasting several minutes at a time, localized to the right upper quadrant with no aggravating or alleviating factors. Associated symptoms included nausea with 5 episodes of non-bilious vomiting and nonproductive cough for the same duration. Social history included living in an apartment with 6 dogs and a kitten. He also had prior exposure to tuberculosis. He denied any recent travel outside Pennsylvania, ingestion of raw or uncooked meat, or recent sick contacts.

*Corresponding author: Ranjan Pathak, MD, Department of Internal Medicine, Reading Health System, West Reading, PA 19611, USA.
Tel: 1 484 8183401
Fax: 1 484 6289003
E-mail: ranjanrp@gmail.com

Article history:
Received 6 Jan 2014
Received in revised form 10 Feb, 2nd revised form 22 Feb, 3rd revised form 8 Mar 2014
Accepted 26 Apr 2014
Available online 15 Sep 2014

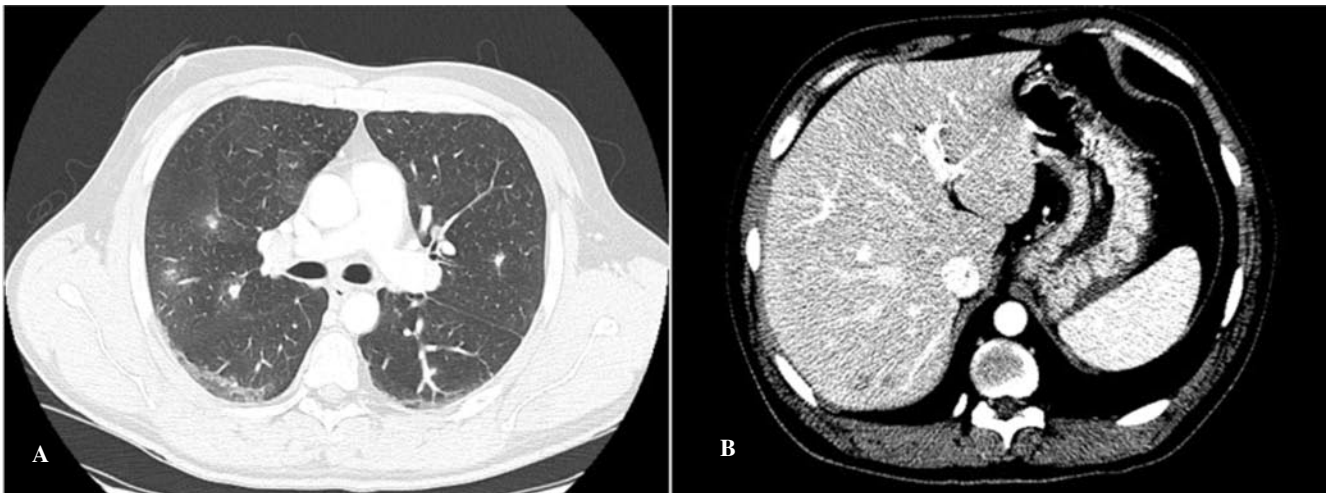


Figure 1. Contrast enhanced CT scan of the chest and abdomen.

A: CT scan of the chest showing multifocal, ill-defined pulmonary nodules with a small surrounding halo, without evidence of cavitation; B: CT scan of the abdomen showing multiple sub-centimeter ill-defined hypodense lesions with vague peripheral enhancement throughout the liver.

Physical examination revealed a fully conscious and alert patient with a blood pressure of 128/76 mmHg, pulse rate 76/min, respiratory rate 20/min, and a temperature of 36.8 °C. The lungs were clear to auscultation bilaterally. He had mild right upper quadrant tenderness with no guarding, rigidity or rebound tenderness. Stool guaiac test was negative for occult blood. His laboratory test results were significant for a leukocytosis with white blood cell count 17 400/mm³ (eosinophils 18%, absolute eosinophil count 3 220), hemoglobin 14.4, blood glucose 99 and his aspartate aminotransferase, alanine aminotransferase, alkaline phosphatase, amylase, lipase and bilirubin were all within normal limits. Serum immunoglobulin (Ig) E levels were 5564 IU/mL, other immunoglobulin levels (IgA, G and M) as well as complement levels (CH₅₀) were within normal limits. Flow cytometry did not reveal any abnormal cell populations. Additional tests, including antinuclear antibody, anti-neutrophil cytoplasmic antibody, stool examination for ova and parasites, serologies for HIV, hepatitis B and C, *Aspergillus fumigatus*, *Trichinella spiralis*, *Histoplasma capsulatum*, *Toxoplasma gondii*, *Strongyloides stercoralis* and quantiferon test were all negative. His serum toxocara IgM antibody levels on ELISA was 3.19 (normal <1). Chest radiograph revealed bilateral scattered small ill-defined nodules bilaterally. Contrast enhanced CT scan of the chest and abdomen revealed ill-defined pulmonary nodules and foci of ground glass opacification and multiple hypodense lesions in the liver with peripheral enhancement (Figure 1). CT scan of the brain showed no acute abnormalities. Gram stain, acid fast stain and bacterial/fungal cultures of bronchial washings and endobronchial biopsy were negative. Urine and blood cultures were negative. An ultrasound-guided liver biopsy was attempted but was not successful due to small size of the lesions.

Based on his constellation of symptoms, history of exposure to dogs, positive toxocara serology and pulmonary and liver involvement in radiograph, a diagnosis of disseminated toxocariasis was made after ruling out other possible

infectious processes. He was treated with mebendazole 200 mg twice a day for 5 d. Concomitant prednisone was started at 1 mg/(kg·d) and tapered over the next 2 months. At 3 weeks follow up, he had a significant improvement in his symptoms as well as eosinophil count.

3. Discussion

Toxocariasis is a zoonotic infection caused by *Toxocara canis*, or less commonly, *Toxocara cati*, whose definitive hosts are dogs and cats, respectively. Humans are accidental hosts and acquire the infection primarily through ingestion of embryonated eggs from soil contaminated with infected dog or cat feces and through contaminated vegetables^[1,4,5]. The patient's history was significant for dog and cat exposure.

Most human infections are asymptomatic. Two of the well-recognized syndromes especially in children are visceral larva migrans and ocular larva migrans. Other less severe syndromes described are covert toxocariasis (in children), and common toxocariasis (in adults). Central nervous system involvement may lead to a variety of neurological disorders such as meningo-encephalitis, space-occupying lesion, cerebral vasculitis, epilepsy, and myelitis^[1,6]. Infection in adults usually ranges from asymptomatic to non-specific symptoms as it is shown in the case, which usually makes the diagnosis difficult. Clinical manifestations are due to damage caused by death of migrating larvae in the visceral organs, e.g., lungs, liver and eyes. This is thought to provoke an immediate and delayed hypersensitivity reaction and eosinophilic granulomatous response affecting a wide variety of organs^[7].

Diagnosis is established on the basis of marked eosinophilia and presence of specific serum toxocara antibodies in the right clinical setting^[8]. High serology titers suggest recent infection while lower levels point to mild infection or infection in remission. Serum eosinophil levels may be used to assess therapeutic response. However, it

is important to note that while eosinophilia and toxocara antibody titres are positively correlated in most of the cases, high *Toxocara* antibody titre may be associated with normal serum eosinophil counts in some cases[9]. The patient mentioned in the case had diffuse involvement of the lungs and the liver with a history of exposure to 6 dogs and a cat and his labs demonstrated striking eosinophilia and a positive toxocara serology.

Mild forms of toxocariasis are self-limited and do not require anti-helminthic therapy; severe or persistent infections, such as the example in this case, can be treated with benzimidazole derivatives such as mebendazole and albendazole[7]. Concomitant corticosteroids limit the inflammatory response resulting from release of *Toxocara* antigens by dying parasites. There is scant literature regarding the optimal duration of therapy and a five days' course is commonly prescribed. However, some patients might have persistent disease after the first course of treatment and might need a repeat course of antihelminthic therapy. The patient was prescribed mebendazole 200 mg by mouth twice a day for 2 weeks with prednisone [starting at 1 mg/(kg·d)], which was tapered over the next 2 months. At 1 year follow up, the patient was completely asymptomatic with normalization of laboratory parameters.

In conclusion, toxocariasis should be considered as a differential diagnosis in any patient presenting with persistent hypereosinophilia. Similarly, in patients with multiple non-cavitating pulmonary and hepatic infiltrates, a history of exposure to dogs and cats should be sought and toxocara serology should be performed[6,10]. Albendazole or mebendazole with concomitant corticosteroid are the treatment of choice and can lead to a significant improvement in symptoms and laboratory parameters.

Conflict of interest statement

We declare that we have no conflict of interest.

Comments

Background

Diagnosis of toxocariasis in immunocompetent adults is a challenge as the infection ranges from asymptomatic to non-specific symptoms. Confirmation of the infection is difficult as it requires identification of *Toxocara* larvae in biopsy of infected organ. Hence hypereosinophilia, serological evidences, pulmonary and hepatic involvement, and history of exposure to dogs and/or cats are useful for differential diagnosis of toxocariasis.

Research frontiers

The case study reveals the importance of considering *Toxocara* infection in adult patient with persistent hypereosinophilia; and albendazole or mebendazole with

concomitant corticosteroid are the treatment of choice.

Related reports

Besides *Toxocara*, many other parasites such as *Ascaris*, *Strongyloides* and hookworms cause eosinophilic lung disease. Differential diagnosis is often based on presence of high antibody titre specific to the parasite antigen.

Innovations and breakthroughs

In a patient with multiple non-cavitating pulmonary and hepatic infiltrates, a history of exposure to dogs and cats was sought and *Toxocara* serology was performed.

Applications

The diagnosis and treatment of toxocariasis in this report is important to clinical parasitologists who work in communities where human seroprevalence against toxocariasis is high and many dogs and cats are infected with *Toxocara*.

Peer review

The authors demonstrated the efficacy of albendazole or mebendazole with concomitant corticosteroid on treating a patient suspected of being infected with toxocariasis.

References

- [1] Nicoletti A. Toxocariasis. *Handb Clin Neurol* 2013; **114**: 217–228.
- [2] Won KY, Kruszon-Moran D, Schantz PM, Jones JL. National seroprevalence and risk factors for zoonotic *Toxocara* spp. infection. *Am J Trop Med Hyg* 2008; **79**(4): 552–557.
- [3] Mohamed AS, Moore GE, Glickman LT. Prevalence of intestinal nematode parasitism among pet dogs in the United States (2003–2006). *J Am Vet Med Assoc* 2009; **234**(5): 631–637.
- [4] Macpherson CN. The epidemiology and public health importance of toxocariasis: a zoonosis of global importance. *Int J Parasitol* 2013; **43**(12–13): 999–1008.
- [5] Rubinsky-Elefant G, Hirata CE, Yamamoto JH, Ferreira MU. Human toxocariasis: diagnosis, worldwide seroprevalences and clinical expression of the systemic and ocular forms. *Ann Trop Med Parasitol* 2010; **104**(1): 3–23.
- [6] Coşkun F, Akıncı E. Hepatic toxocariasis: a rare cause of right upper abdominal pain in the emergency department. *Turkiye Parasitol Derg* 2013; **37**(2): 151–153.
- [7] Despommier D. Toxocariasis: clinical aspects, epidemiology, medical ecology, and molecular aspects. *Clin Microbiol Rev* 2003; **16**(2): 265–272.
- [8] Cojocariu IE, Bahnea R, Luca C, Leca D, Luca M. Clinical and biological features of adult toxocariasis. *Rev Med Chir Soc Med Nat Iasi* 2012; **116**(4): 1162–1165.
- [9] Taylor MR, Keane CT, O'Connor P, Mulvihill E, Holland C. The expanded spectrum of toxocaral disease. *Lancet* 1988; **1**(8587): 692–695.
- [10] Kang EY, Shim JJ, Kim JS, Kim KI. Pulmonary involvement of idiopathic hypereosinophilic syndrome: CT findings in five patients. *J Comput Assist Tomogr* 1997; **21**(4): 612–615.